

ANTLER ANOMALIES IN TULE ELK

Peter J. P. Gogan,^{1,3} David A. Jessup,² and Reginald H. Barrett¹

¹ Department of Forestry and Resource Management, University of California, Berkeley, California 94720, USA

² Wildlife Investigations Laboratory, California Department of Fish and Game, 1701 Nimbus Road, Suite D, Rancho Cordova, California 95670, USA

³ Present address: Voyageurs National Park, P.O. Box 50, International Falls, Minnesota 56649, USA

ABSTRACT: Antler anomalies were evident in tule elk (*Cervus elaphus nannodes*) within 1 yr of reintroduction to Point Reyes, California (USA). These anomalies are consistent with previously described mineral deficiency-induced anomalies in cervids. The elk were judged deficient in copper. Low levels of copper in soils and vegetation at the release site, exacerbated by possible protein deficiency due to poor range conditions, are postulated as likely causes of the antler anomalies.

Key words: Tule elk, *Cervus elaphus nannodes*, antler anomalies, mineral deficiency, copper, field study.

INTRODUCTION

Two mature male and eight mature female tule elk (*Cervus elaphus nannodes*) translocated from San Luis National Wildlife Refuge, Merced County (37°10'N, 120°51'W), to Point Reyes National Seashore, Marin County (38°20'N, 122°56'W), California (USA), in March 1978 were restricted to a 1.2-ha pen and provided dietary supplements of alfalfa hay prior to their release to a 1,030-ha beef cattle ranch within the Seashore in September 1978. The eight elk cows produced nine live-born calves while in the holding pen, although two calves were lost perinatally to undetermined causes. The entire herd appeared to flourish through December 1978 (Ray, 1981). However, by May 1979, the elk exhibited signs of copper deficiency as described for sheep and cattle. These signs included achromotrichia, rough and brittle pelage, stilted gait and reduced reproductive rates (three live-born calves from eight cows). Antler anomalies were observed in the two reintroduced mature bulls and four yearling males in 1979. An adult male and adult female died in May 1979. Discussions with a local veterinarian revealed that beef-cattle at the Point Reyes release site regularly received dietary copper supplements to prevent reproductive problems, including birth of hairless calves with deformed spinal columns as was ob-

served in the 1950's (R. Fisher, pers. comm.).

The surviving elk at Point Reyes were provided with pelleted alfalfa feed, fresh alfalfa and commercial livestock feed supplements containing copper as copper oxide including 13.6 kg of 12% Vonco Dairy Pellets (maximum 2% minerals including copper) and 2.3 kg of Comet 20% Pasture and Roughage balance (0.003% copper) (Bar Ale, Petaluma, California 94952, USA) daily between mid-September 1979 and early February 1980 and thereafter on alternate days through April 1980, when they ceased taking it.

MATERIALS AND METHODS

Carcasses of both adult elk dying in May were necropsied within 1 wk of death. The surviving adult male was immobilized with a combination of 4 mg etorphine (M-99, Lemon Company, Sellersville, Pennsylvania 18960, USA) and 35 mg of xylazine (Rompun, Haver-Lockhart Laboratories, Shawnee, Kansas 66201, USA) and transferred to a holding pen at Grizzly Island State Wildlife Management Area, Solano County (38°10'N, 121°40'W), California, in early July 1979. At Grizzly Island, the animal received an injection of 120 mg copper glycinate (Cuprate, Burns Biotec, Oakland, California 94621, USA) and a copper sulfate-enriched diet of pelleted alfalfa feed and fresh alfalfa. It was subsequently released to free-range in April 1980. This male was immobilized as above and serum samples taken in May and July 1980. The scavenged carcass was not located until several weeks after

the animal's death at Grizzly Island in the fall 1981.

Necropsies were performed on a yearling female that died of natural causes, an adult female that died under treatment and a yearling male that died during an attempt to immobilize it. Liver and serum samples were taken for analysis of copper levels when possible. No analysis was done for sex hormone levels.

The skulls of a mature male (PORE 312) and a yearling male (PORE 319) that died at Point Reyes in 1979 were preserved in the natural history collection at Point Reyes National Seashore (Point Reyes, California 94956, USA). The left antlers grown by the surviving mature male in 1979 and 1980 and cast in March 1980 and 1981 (PORE 481, 482) were also preserved. The antlered skull cap of this male was mounted in 1981 and is presently in the Department of Fish and Game administrative building at Grizzly Island (Grizzly Island Wildlife Management Area, California Department of Fish and Game, P.O. Box 368, Suisun City, California 94585, USA). All antlers used in this study were radiographed at Marin Veterinary Clinic (Point Reyes, California 94956, USA). Select radiographs were examined by Dr. A. B. Bubenik (Thornhill, Ontario, Canada L3T 3X7).

RESULTS

Both mature males exhibited a similar pattern of antler anomalies. Antlers of the male that died in 1979 appeared normal in development of the proximal portion of main beam and brow and bez tines, but were then bilaterally malformed with an anterior deviation of the beam ending in a vertically oriented club (Fig. 1). This elk died in July, prior to the normal shedding of velvet. The more massive, cast, 1979–1980 antler (PORE 481) of the surviving male exhibited a sharp downward bend in the main beam beyond the bez tine and the distal portion of the beam was palmate from which four small tines protruded (Fig. 2). The 1980–1981 antlers of this male were more normal in appearance. Antlers for 1981–1982 were partially malformed and considerably smaller than those of the previous year. A radiograph of the cast antler from this mature male at Point Reyes in 1979 (PORE 481) showed a poorly developed cortex in comparison to the antler grown by the same male at Grizzly Island

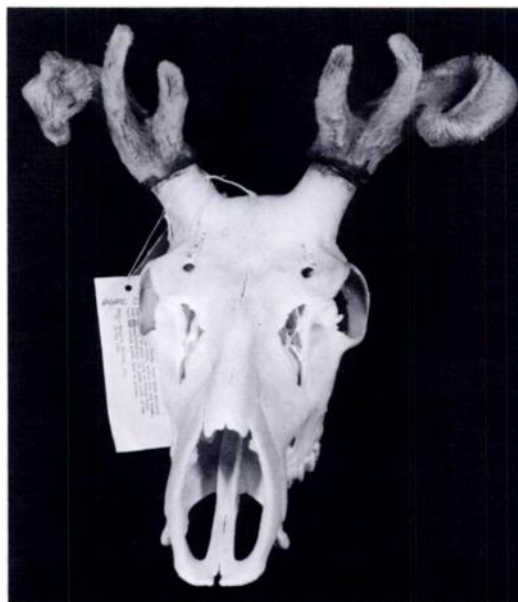

FIGURE 1. Photograph of skull showing bilateral deformed antlers of an adult male tule elk that died at Point Reyes (PORE 312).

the following year (PORE 482) (A. B. Bubenik, pers. comm.). The antler cortices of PORE 481 were not only thinner than PORE 482, but the adjacent trabecular bone was coarser, suggesting osteoporosis, and the central core was hollow rather than filled with trabecular bone. This may result in long survival of the core after shedding, an event caused by relatively low testosterone secretion (A. B. Bubenik, pers. comm.).

Spike antlers of the yearling male that died at Point Reyes in 1979 exhibited a slight bilateral corkscrew anomaly (Fig. 3), as did the three surviving male yearlings. This pattern of antler growth was not evident in yearling males at Point Reyes in any other year through 1986 (Gogan, pers. obs.).

Necropsy of the 1-wk-old carcasses of the adult male and adult female that died in May 1979 suggested the cause of death may have been peritonitis associated with osteophagia as diagnosed from many small, sharp bone fragments in the abomasum (R. Fisher, pers. comm.).




FIGURE 2. Photograph of left antlers of adult male tule elk with a deformed antler in 1979 cast at Point Reyes (PORE 481) (upper), a more normal antler cast in 1980 (PORE 482) (center) and a smaller, partially malformed antler when the animal died at Grizzly Island in 1981 (lower). Antlers were bilaterally similar in each year. Photograph by Jerald Morse.

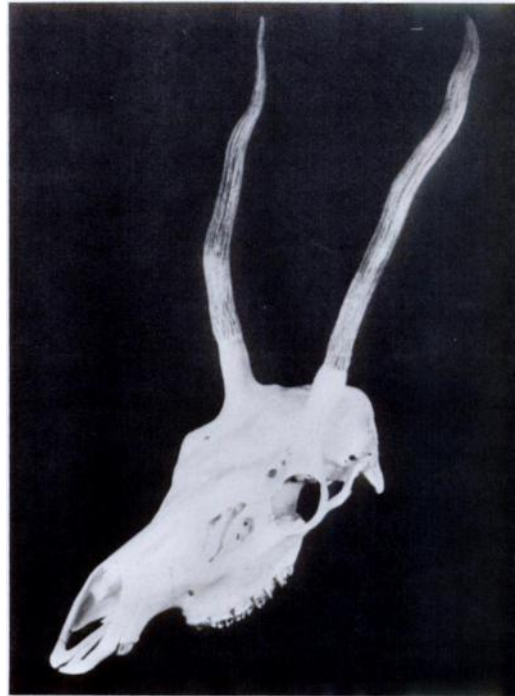

FIGURE 3. Photograph of skull showing bilateral corkscrew antlers in a yearling male tule elk that died at Point Reyes in 1979 (PORE 319). Photograph by Jerald Morse.

In July 1979, the surviving adult male was emaciated, with its ribs and backbone severely protruding. The animal's hooves were badly overgrown and its pelage was pale and brittle. Its serum copper level was 0.3 parts per million (ppm). In May 1980, the animal had gained weight and its serum copper level increased 1.0 ppm. However, serum copper declined to 0.3 ppm again in July 1980.

A yearling female died of undetermined causes in mid-July 1979. It, too, was extremely emaciated. Necropsy of the <24-hr-old, partially scavenged carcass revealed no body, perirenal or cardiac fat. The liver was very firm and the spleen shrunken. The bone marrow was pale and watery. Lung nematodes were present in many bronchi but not in excessive numbers. The brain, heart and kidneys were unremarkable. The rumen was full of ingesta but contained no bone fragments or dirt. The cause of death was not deter-

mined, but starvation and fibrosis of the liver were identified as possible causes. The liver copper level was 4.7 ppm dry weight basis (dwb).

An emaciated adult female was immobilized as above at Point Reyes and transferred to Grizzly Island in late August 1979. A dose of 3 cc penicillin (Flo-Cillin, Bristol Laboratories, Syracuse, New York 13221, USA) and 120 mg copper glycinate was administered via a nonbarbed syringe dart. Approximately 6 min later the animal swayed on its rear quarters, stumbled forward and fell with the head and neck beneath her body. Examination revealed the neck to be broken at the fourth vertebrae and the animal was euthanized. The animal had been in poor physical condition with overgrown hooves. Necropsy revealed no subcutaneous, perirenal or cardiac fat. The abomasum contained several hundred well-worn bone fragments. The

colon appeared thickened. The spleen and lymph nodes appeared normal. The liver was grey-colored and firm. The heart was slightly enlarged on the right side and the musculature appeared mottled. Other pathological conditions were attributable to injuries sustained while falling. The liver copper level was 3.1 ppm dwb and serum copper level 0.6 ppm.

A yearling male was struck in the abdomen with a barbed syringe in early November 1979 and died of peritonitis. Necropsy showed the animal to be in fair flesh with light subcutaneous, perirenal and cardiac fat. Liver copper content was 10 ppm dwb.

DISCUSSION

Antler anomalies may be attributed to (1) genetic causes (Goss, 1983); (2) injury to the antler or contralateral hind limb (Goss, 1983); (3) physiologic-nutritional factors, including mineral imbalances (Bubenik, 1966) possibly associated with protein deficiency (French et al., 1956) and imbalances of testosterone (A. B. Bubenik, pers. comm.); and (4) failure of testosterone receptors at the velvet (Bubenik and Weber-Schilling, 1986). The bilateral nature of these deformities suggest they were not caused by physical injury to the antler, and injury to the hind limbs was not seen. The fact that the deformity was not evident in the same individual in consecutive years suggested a non-genetic cause (Goss, 1983). Thus, physiologic-nutritional imbalances were the likely cause of these deformities. Antler anomalies of the type recorded here have been associated with imbalances of calcium and phosphorus in *C. elaphus* (Bubenik, 1966, 1982). Normal-appearing but brittle antlers in tule elk in the Owens Valley, Inyo County, California (USA), have been attributed to calcium deficiency (McCullough, 1969). Captive white-tailed deer (*Odocoileus virginianus*) fed diets low in calcium, phosphorus and protein developed abnormally short antlers with fewer points (French et al., 1956).

In Texas, low liver copper levels were reported for four of seven white-tailed deer with antlers "... stunted, twisted, broadened, or knobby at the tips" (King et al., 1984). A local deficiency of an unidentified trace element was proposed as a potential cause of antlers in velvet in the fall and atrophic testes in white-tailed deer in the same area (Taylor et al., 1964). This anomaly was localized, but generally the incidence increased following severe droughts (Taylor et al., 1964).

Osteomalacia associated with copper deficiency has been recorded in both domestic and wild ungulates. Bone disorders associated with copper deficiency in cattle include osteoporosis, spontaneous bone fracture, and delayed and incomplete calcification of cartilaginous plates (Irwin et al., 1974; Owen, 1981). Copper deficiency in wild cervids has been reported as ataxia in adult red deer (Barlow et al., 1964; Terlecki et al., 1964; MacKintosh et al., 1986a), osteoporosis in adult reindeer (*Rangifer tarandus*) (Hyvarinen et al., 1977), and irregular hoof keratinization and reduced reproductive rates in adult moose (*Alces alces*) (Flynn et al., 1977). It seems, therefore, that copper deficiency has the potential to cause antler deformities of the type reported herein.

The adult male transferred to Grizzly Island received injectable copper supplementation initially and dietary supplements through April 1980. Growth of the more normal 1980–1981 antlers coincided with the dietary copper supplements. The diminutive and partially deformed antlers of 1981–1982 (Fig. 2) were thought not to have resulted from trace element deficiency, but rather from the old age of this animal (≥ 14 yr) (Wolfe, 1982).

Rotation and ventral displacement of the beam in the two mature males in 1979 suggested that the beams deviated ventrally under their own weight and were subsequently mineralized in that position (Bubenik, 1982). Radiographic results were not entirely consistent with delayed mineralization attributable to trace element

deficiency because antlers developed under such conditions become "almost petrified in tips and base" (A. B. Bubenik, pers. comm.). The antler anomalies may also have been due to inadequate levels of testosterone or other complicating factors (A. B. Bubenik, pers. comm.). However, antlers grown under conditions of low testosterone levels do not shed their velvet (Bubenik, 1982). All adult or yearling male elk at Point Reyes shed the velvet from their antlers in the fall. Thus, if the initial inadequate mineralization and antler deformities were due to low testosterone, this was corrected by the fall. The role of other factors compounding the effect of copper deficiency on antler growth was not determined.

Liver copper levels in the elk that died at Point Reyes in 1979 are indicative of copper deficiency. Levels in tule elk at Point Reyes contrasted greatly to values reported between 84 and 142 ppm dwb for tule elk at three other locations in California (McCullough, 1969). Values for elk (*C. elaphus* subsp.) in Fiordland National Park, New Zealand, averaged 69 ppm dwb, while free-ranging red deer (*C. elaphus* subsp.) outside the park averaged 132 ppm dwb (Reid et al., 1980). The average value for red deer from captive herds in the same region, with some evidence of ataxia, was 11 ppm dwb (Reid et al., 1980). Female red deer (*C. elaphus elaphus*) in Scotland had an average liver copper level of 24 ppm dwb with a range of 3 to 108 ppm (Cowie, 1976). Liver copper levels in all red deer in the British Isles diagnosed as ataxic were less than a suggested critical level of 20 ppm dwb (Barlow, 1978). However, although no red deer on the Isle of Rhum, Scotland, showed evidence of ataxia, 20% of the animals sampled had liver copper values below 20 ppm dwb (McTaggart et al., 1981). Only two percent had liver copper levels below 10 ppm dwb (McTaggart et al., 1981). Liver copper values <18 ppm dwb have been identified as diagnostic of copper deficiency in red deer in New Zealand (MacKintosh et al., 1986b).

Similarly, levels of copper in serum samples are indicative of copper deficiency in tule elk at Point Reyes. The serum copper level in the surviving adult male immobilized in July 1979 was below the value of 0.5 ppm considered diagnostic of copper deficiency in red deer (MacKintosh et al., 1986b), and it was only marginally above that value in the female that died under treatment. This value is less than one-half the critical value of 1 ppm for moose (Flynn et al., 1977) or reindeer (Hyvarinen et al., 1977).

Mean calcium (12%) and phosphorus (21%) values in hair of tule elk at Point Reyes were within the range of mean values for tule elk at other locations in California (calcium 9 to 21%; phosphorus 5 to 40%) (Gogan, unpubl. data). However, investigations of copper values in liver and serum in tule elk at Point Reyes from 1979 to 1981 indicated that the herd suffered from a severe copper deficiency in mid-1979. This was reversed by diet supplementation in spring 1980 (Gogan, 1986). However, the animals reverted to subclinical deficiency (Bingley and Anderson, 1972) from summer 1980 through winter 1981 (Gogan, 1986). This deficiency in copper was consistent with simple copper deficiency due to low levels of copper in the forage, soils and granitic parent material, rather than complex copper deficiency due to excessive amounts of molybdenum or sulfur-sulfates (Mills, 1980; Akesson et al., 1982). In addition, copper deficiency may have been exacerbated by poor range conditions and forage competition between elk and beef cattle during 1978-1979 following a drought in 1976-1977 (Gogan, 1986). Cattle were stocked throughout the year at high densities (0.4/ha) until their complete removal in November 1979 (Gogan, 1986). Elk at Point Reyes consumed far more bush lupine (*Lupinus arboreus*) between October 1979 and February 1980 than at any other time through September 1981 (Gogan, 1986). Mean copper content of this shrub (9.0 ppm dwb) is far higher than mean values

for more typical elk forage plants such as grasses (range 2.8 to 5.1 ppm dwb) and forbs (range 1.2 to 6.8 ppm dwb) (Akeson et al., 1982). High consumption of bush lupine may indicate an inability to obtain adequate nutrients, including copper, from other sources. Similarly, levels of dietary protein, estimated by percent fecal nitrogen (Lancaster, 1949; Kie and Burton, 1984), were lower in early October 1979, the first month sampled, than in any other month over the same period despite dietary supplements provided initially in mid-September 1979 (Gogan, unpubl. data).

The antler deformities recorded in tule elk at Point Reyes suggest inadequate mineralization, likely caused by low levels of dietary copper and possibly associated with concurrent low levels of dietary protein. It appears less likely that low levels of testosterone caused the deformities, given the ability of elk at Point Reyes to shed velvet from their antlers in the fall. Any interactions between copper deficiency and testosterone levels is poorly understood. However, the generally poor nutrition measured as low levels of copper and protein, possibly compounded by other unknown factors, is the most likely cause of malformed antlers in tule elk at Point Reyes in 1979.

ACKNOWLEDGMENTS

We wish to thank R. Fisher for the radiographs of elk antlers and A. B. Bubenik for reviewing radiographs and photographs of antlers. J. Wood and two anonymous referees made many constructive suggestions on drafts of this manuscript. L. Merkle kindly typed the final and earlier versions of this manuscript. This research was supported by National Park Service Contract CX 800-9-0029; Pittman Robertson Project W-52-R "A Wildlife Investigations Laboratory"; Project 3501-MS of the California Agricultural Experiment Station; and a Rob and Bessie Welder Wildlife Foundation fellowship to the senior author. Welder Wildlife Foundation Contribution No. 323.

LITERATURE CITED

- AKESON, M., L. D. WHITTIG, R. G. BURAU, V. V. RENDIG, AND R. D. MEYER. 1982. Levels of selected micronutrients in soils and vegetation and dietary implications for tule elk at Point Reyes National Seashore. Technical Report No. 13, Cooperative National Park Resources Studies Unit, University of California, Davis, California, 47 pp.
- BARLOW, R. M. 1978. Enzootic ataxia of deer. *In* Symposium on the comparative pathology of zoo animals, R. S. Montali and G. Migaki (eds.). National Zoological Park, Smithsonian Institute, Washington, D.C., pp. 65-71.
- , E. J. BUTLER, AND D. PURVES. 1964. An ataxic condition in red deer (*Cervus elaphus*). *Journal of Comparative Pathology* 74: 519-529.
- BINGLEY, J. N., AND N. ANDERSON. 1972. Clinically silent hypocuprosis and the effects of molybdenum loading on beef calves in Gippsland, Victoria. *Australian Journal of Agricultural Research* 23: 885-904.
- BUBENIK, A. B. 1966. *Das Gehehe*. Paul Parey Verlag, Hamburg, Federal Republic of Germany, 214 pp.
- . 1982. Physiology. *In* Elk of North America, ecology and management, J. W. Thomas and D. E. Towel (eds.). Stackpole Books, Harrisburg, Pennsylvania, pp. 125-179.
- , AND C. WEBER-SCHILLING. 1986. Perücken der Geweihträger und das Phänomenon des Abwerfens oberhalb der Rose. *Zeitschrift für Jagd- und Jägerschaft* 32: 158-171.
- COWIE, R. S. 1976. Copper levels in red deer. *The Veterinary Record* 98: 434.
- FLYNN, A. A., A. W. FRANZMANN, P. D. ARNESON, AND J. L. OLDEMAYER. 1977. Indications of copper deficiency in a subpopulation of Alaskan moose. *Journal of Nutrition* 107: 1182-1189.
- FRENCH, C. F., I. C. MCEWAN, N. D. MAGRUDER, R. H. INGRAM, AND R. W. SWIFT. 1956. Nutrient requirements for growth and antler development in the white-tailed deer. *The Journal of Wildlife Management* 20: 221-232.
- GOGAN, P. J. P. 1986. Ecology of the tule elk range, Point Reyes National Seashore. Ph.D. Thesis. University of California, Berkeley, California, 441 pp.
- GOSS, R. J. 1983. Deer antlers. Regeneration, function and evolution. Academic Press Inc., New York, New York, 316 pp.
- HYVARINEN, H., I. HELLE, M. NIEMINEN, P. VAYRYNEN, AND R. VAYRYNEN. 1977. The influence of nutrition and seasonal conditions on mineral status in the reindeer. *Canadian Journal of Zoology* 55: 648-655.
- IRWIN, M. R., P. W. POULOS, JR., B. P. SMITH, AND G. L. FISHER. 1974. Radiology and histopathology of lameness in young cattle with secondary copper deficiency. *Journal of Comparative Pathology* 84: 611-621.
- KIE, J. G., AND T. S. BURTON. 1984. Dietary quality, fecal nitrogen and 2, 6 diamino-pellic acid in black-

- tailed deer in northern California. Research Note PSW-364. Pacific Southwest Forest and Range Experiment Station, Forest Service, U.S. Department of Agriculture, Berkeley, California, 3 pp.
- KING, K. A., J. LELEUS, AND B. M. MULHERN. 1984. Molybdenum and copper levels in white-tailed deer near uranium mines in Texas. *The Journal of Wildlife Management* 48: 267-270.
- LANCASTER, R. J. 1949. Estimation of digestibility of grazed pasture from faeces nitrogen. *Nature* (London) 163: 330-331.
- MACKINTOSH, C. G., M. B. ORR, AND K. TURNER. 1986a. Enzootic ataxia in wapiti. *Proceedings Deer Branch New Zealand Veterinary Association Course 3*: 165-169.
- , P. R. WILSON, N. S. BEATSON, K. TURNER, AND P. JOHNSTONE. 1986b. Preliminary report of the liver:serum copper relationship in red deer. *Proceedings Deer Branch New Zealand Veterinary Association Course 3*: 156-164.
- MCCULLOUGH, D. R. 1969. The tule elk: Its history, behavior and ecology. University of California Publications in Zoology 88: 1-209.
- MCTAGGART, H. S., V. P. W. LOWE, P. J. BARDEN, AND J. B. M. GELLATLY. 1981. Copper status of red deer on the island of Rhum. *The Veterinary Record* 109: 155-157.
- MILLS, C. F. 1980. Metabolic interactions of copper with other trace elements. *In Biological roles of copper*, D. Evered and G. Lawrenson (eds.). *Erpta medica*. Ciba Foundation Symposium 79 (New Series), Amsterdam, The Netherlands, 343 pp.
- OWEN, C. A., JR. 1981. Copper deficiency and toxicity: Acquired and inherited, in plants, animals, and man. Noyes Publications, Park Ridge, New Jersey, 181 pp.
- RAY, D. T. 1981. Post-release activity of tule elk at Point Reyes National Seashore, California. M.S. Thesis. University of Michigan, Ann Arbor, Michigan, 114 pp.
- REID, T. C., H. J. F. MCALLUM, AND P. D. JOHNSTONE. 1980. Liver copper concentrations in red deer (*Cervus elaphus*) and wapiti (*C. canadensis*) in New Zealand. *Research in Veterinary Science* 28: 261-262.
- TAYLOR, D. O. N., J. W. THOMAS, AND R. G. MARBURGER. 1964. Abnormal antler growth associated with hypogonadism in white-tailed deer in Texas. *American Journal of Veterinary Research* 25: 179-185.
- TERLECKI, S., J. T. DONE, AND F. G. CLEGG. 1964. Enzootic ataxia of red deer. *British Veterinary Journal* 120: 311-321.
- WOLFE, G. J. 1982. The relationship between age and antler development in wapiti. *In Antler development in Cervidae*, R. D. Brown (ed.). Caesar Kleberg Wildlife Research Institute, Kingsville, Texas, pp. 29-36.

Received for publication 29 August 1987.