

## **Egg Yolk Serositis in an American Alligator (*Alligator mississippiensis*)**

Authors: M. M. McDonald, and H. W. Taylor

Source: Journal of Wildlife Diseases, 24(4) : 700-702

Published By: Wildlife Disease Association

URL: <https://doi.org/10.7589/0090-3558-24.4.700>

---

BioOne Complete ([complete.BioOne.org](http://complete.BioOne.org)) is a full-text database of 200 subscribed and open-access titles in the biological, ecological, and environmental sciences published by nonprofit societies, associations, museums, institutions, and presses.

Your use of this PDF, the BioOne Complete website, and all posted and associated content indicates your acceptance of BioOne's Terms of Use, available at [www.bioone.org/terms-o-use](http://www.bioone.org/terms-o-use).

Usage of BioOne Complete content is strictly limited to personal, educational, and non - commercial use. Commercial inquiries or rights and permissions requests should be directed to the individual publisher as copyright holder.

---

BioOne sees sustainable scholarly publishing as an inherently collaborative enterprise connecting authors, nonprofit publishers, academic institutions, research libraries, and research funders in the common goal of maximizing access to critical research.

## Egg Yolk Serositis in an American Alligator (*Alligator mississippiensis*)

M. M. McDonald<sup>1,2</sup> and H. W. Taylor,<sup>1</sup> <sup>1</sup> Department of Veterinary Pathology, School of Veterinary Medicine, Louisiana State University, Baton Rouge, Louisiana 70803, USA. <sup>2</sup> Present address: Chemical Pathology Branch, National Institute of Environmental Health Sciences, P.O. Box 12233, Research Triangle Park, North Carolina 27709, USA

**ABSTRACT:** An adult female American alligator (*Alligator mississippiensis*) had diffuse, yellow, granular serosal thickening at necropsy. Light microscopic examination of affected stomach, small intestine and spleen revealed a chronic proliferative serositis associated with 3 to 15  $\mu\text{m}$  eosinophilic extracellular globules identified histochemically and morphologically as egg yolk. The intracoelomic egg yolk was considered to be the cause of the serosal reaction.

**Key words:** *Alligator mississippiensis*, American alligator, crocodilian, egg yolk peritonitis, reptile pathology, chronic proliferative serositis, case report.

Egg yolk peritonitis, either sterile or contaminated by bacteria, is a common condition of domestic poultry and pet birds caused by abnormal presence of egg material or ruptured eggs in the coelomic cavity (Coutts, 1981; Blackmore, 1982). It has been reported in reptiles (Hamerton, 1938; Hime, 1976), including a broad-fronted crocodile (*Osteolaemus tetrapsis*) (Hamerton, 1938). This report describes an unusual, previously undocumented tissue reaction to intracoelomic egg yolk in an American alligator (*Alligator mississippiensis*).

During the 1980 summer breeding season, an active, adult (35.4 kg, 2.23 m) female alligator was killed near its nest at the Rockefeller Wildlife Refuge (Cameron Parish, Louisiana, USA; 29°N, 93°W). The nest contained about 40 eggs. The reptile was necropsied by wildlife biologists who reported that the only gross abnormality was a diffuse and finely granular yellow thickening of the mesentery and serosae of the stomach, intestines, spleen, kidneys, ovaries and oviducts.

Samples of small intestine, stomach, kidney and spleen were fixed in 10% neutral buffered formalin, routinely processed, embedded in paraffin, sectioned at 4 to 6  $\mu\text{m}$  and stained with hematoxylin and eosin (H&E) and various special stains. Light microscopic examination showed that the only significant lesion was a marked chronic reactive serositis. Numerous finger-like, nonbranching projections composed of hy-

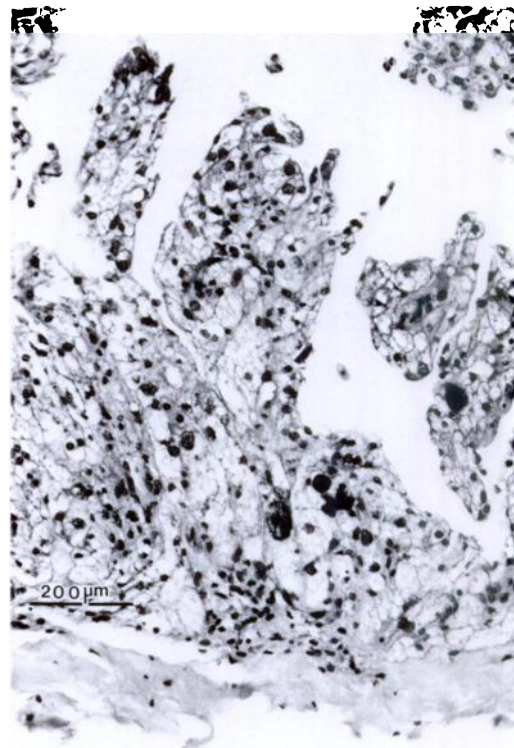


FIGURE 1. Papillary projections composed of pleomorphic mesothelial cells in small intestinal serosa of an American alligator. H&E.

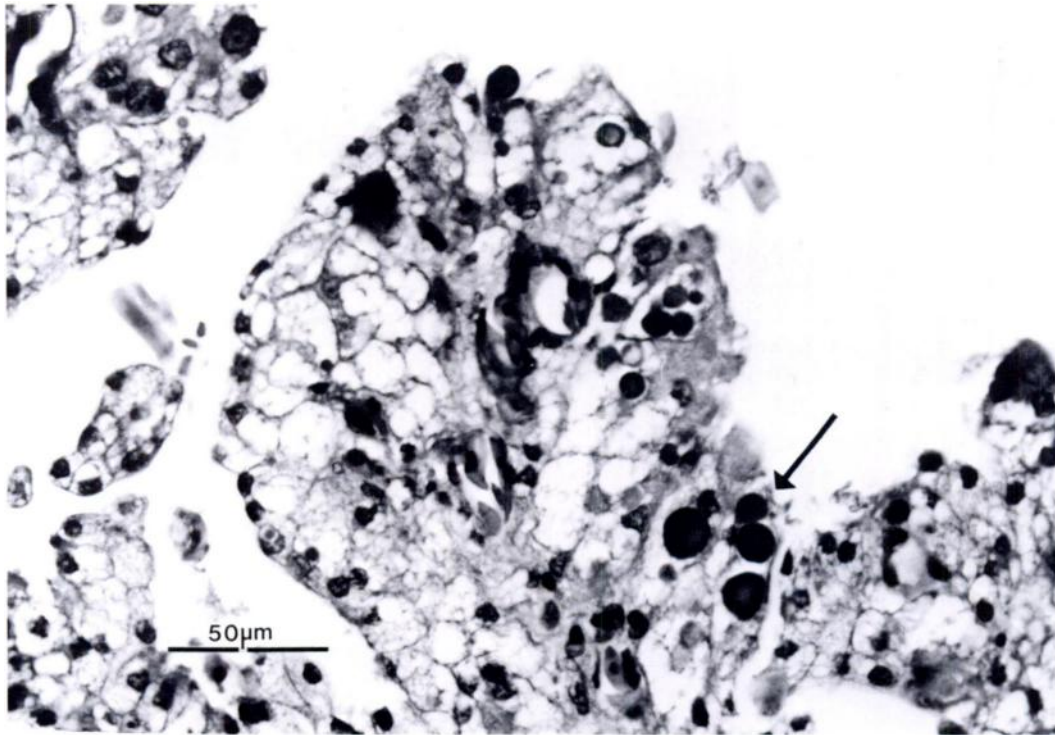


FIGURE 2. Extracellular globule of egg yolk (arrow) in thickened small intestinal serosa of an American alligator. H&E.

peritrophic mesothelial cells extended from the thickened serosa (Fig. 1). The haphazardly packed, polygonal to oval mesothelial cells were distended by confluent, clear cytoplasmic vacuoles; occasional cells had finely foamy cytoplasm. Cytoplasmic vacuoles were positive with oil-red-O staining (Sheehan and Hrapchak, 1980) but were negative with periodic acid-Schiff (PAS) reaction and Von Kossa's stain (Preece, 1972) alizarin-red-S stain (Thompson, 1966), and Ziehl-Neelsen, Prussian blue and Alcian blue stains (Luna, 1968).

Mesothelial cell nuclei were characterized by extreme pleomorphism. Oval and elliptical forms were present, as well as nuclei with irregular, undulating outlines. A few giant (10 to 40  $\mu\text{m}$ ), bizarre nuclei also were seen. Most nuclei had fine chromatin stippling with variable vesiculation. Mitotic figures were not seen in multiple sections.

Serosal vascularization was prominent.

Snook's reticulum stain (Luna, 1968) revealed a delicate, scanty lattice of reticulum fibers and Masson's trichrome stain (Luna, 1968) demonstrated slight to moderate amounts of perivascular collagen. A few small foci of mononuclear inflammatory cells and heterophils were scattered among the mesothelial cells.

Scattered throughout H&E sections were numerous, deeply eosinophilic, nonrefractile, extracellular, 3 to 15  $\mu\text{m}$  diameter globules (Fig. 2). Some of the larger globules had faint concentric lamellations. Globules were PAS-positive but were negative with oil-red-O, Alcian blue, Von Kossa's, alizarin-red-S, Ziehl-Neelsen, and Prussian blue stains. Although the results of special stains of the globules did not correspond completely with those previously reported for snake egg yolk (Bellairs, 1959), the material was identified as egg yolk based on morphology (Bellairs, 1959; Hodges, 1974; Gilbert, 1979). The histo-

logic diagnosis was chronic diffuse proliferative serositis.

Because fresh tissue was not available for culture, the involvement of pathogenic microorganisms could not be excluded from the diagnosis. However, bacteria or fungi were not demonstrated with Gram or Ziehl-Neelsen stains or the PAS reaction. The paucity of inflammatory cell infiltrates in our case contrasts with the histological reaction that would be expected in bacterial and fungal infections. Many cases of egg peritonitis in pet birds are bacteriologically sterile (Blackmore, 1982).

We concluded that egg yolk elicited the serosal reaction in this alligator. As the oviductal ostia of the American alligator communicate freely with the coelomic cavity (Fox, 1977), escape or reflux by reverse peristalsis of ovulated ovarian follicles could easily occur. Alternately, traumatic rupture of an unovulated follicle also could liberate yolk material. This report emphasizes that egg yolk serositis should be considered in the differential diagnosis of serosal lesions in female crocodylians.

We wish to thank the Department of Veterinary Pathology, Armed Forces Institute of Pathology, Washington, D.C. for diagnostic consultation in this case.

#### LITERATURE CITED

- BELLAIRS, R. 1959. The yolk of the adder (*Vipera berus*). *British Journal of Herpetology* 2: 155-158.
- BLACKMORE, D. K. 1982. Diseases of the reproductive system. *In* Diseases of cage and aviary birds, 2nd ed., M. L. Petrak (ed.). Lea and Febiger, Philadelphia, Pennsylvania, pp. 464-465.
- COUTTS, G. S. 1981. Poultry diseases under modern management, 2nd ed. Saiga Publishing Company, Hindhead, Surrey, England, 245 pp.
- FOX, H. 1977. The urogenital system of reptiles. *In* Biology of the Reptilia, Vol. 6, C. Gans and T. S. Parson (eds.). Academic Press, London, England, pp. 1-157.
- GILBERT, A. B. 1979. Female genital organs. *In* Form and function in birds, Vol. 1, A. S. King and J. McLelland (eds.). Academic Press, London, England, pp. 248-250.
- HAMERTON, A. E. 1938. Report on the deaths occurring in the Society's Gardens during the year 1937. *Proceedings of the Zoological Society (London)* 1938: 489-526.
- HIME, J. M. 1976. Report of the veterinary officer, Regent's Park, 1974-75. *Journal of Zoology (London)* 178: 447-455.
- HODGES, R. D. 1974. The reproductive system. *In* Histology of the fowl. Academic Press, London, England, pp. 391-392.
- LUNA, L. G. 1968. A manual of histologic staining methods of the Armed Forces Institute of Pathology, 3rd ed. McGraw-Hill Book Company, New York, New York, 257 pp.
- PREECE, A. 1972. A manual for histologic techniques, 3rd ed. Little, Brown Company, Boston, Massachusetts, 287 pp.
- SHEEHAN, D., AND B. HRAPCHAK. 1980. The theory and practice of histotechnology. C. V. Mosby Company, St. Louis, Missouri, 481 pp.
- THOMPSON, S. W. 1966. Selected histochemical and histopathological methods, Charles C Thomas Publishers, Springfield, Illinois, 1639 pp.

*Received for publication 7 December 1987.*