

Snakebite in Captive Rocky Mountain Elk (*Cervus elaphus nelsoni*)

Authors: Miller, Michael W., Wild, Margaret A., Baker, Brenda J., and Tu, Anthony T.

Source: Journal of Wildlife Diseases, 25(3) : 392-396

Published By: Wildlife Disease Association

URL: <https://doi.org/10.7589/0090-3558-25.3.392>

BioOne Complete (complete.BioOne.org) is a full-text database of 200 subscribed and open-access titles in the biological, ecological, and environmental sciences published by nonprofit societies, associations, museums, institutions, and presses.

Your use of this PDF, the BioOne Complete website, and all posted and associated content indicates your acceptance of BioOne's Terms of Use, available at www.bioone.org/terms-of-use.

Usage of BioOne Complete content is strictly limited to personal, educational, and non - commercial use. Commercial inquiries or rights and permissions requests should be directed to the individual publisher as copyright holder.

BioOne sees sustainable scholarly publishing as an inherently collaborative enterprise connecting authors, nonprofit publishers, academic institutions, research libraries, and research funders in the common goal of maximizing access to critical research.

Snakebite in Captive Rocky Mountain Elk (*Cervus elaphus nelsoni*)

Michael W. Miller,¹ Margaret A. Wild,¹ Brenda J. Baker,² and Anthony T. Tu,² ¹ Colorado Division of Wildlife Research Center, 317 W. Prospect, Fort Collins, Colorado 80526, USA; ² Department of Biochemistry, Colorado State University, Fort Collins, Colorado 80523, USA

ABSTRACT: Eight cases of snakebite occurred in seven of 11 captive Rocky Mountain elk (*Cervus elaphus nelsoni*) during June and July 1987. Severity of reactions to envenomation varied; affected elk presented with combinations of signs that included painful swelling restricted to the face and muzzle, submandibular edema, inspiratory dyspnea, epistaxis, frothy, blood-tinged nasal discharge, epiphora, anorexia and anxiousness or depression. We observed puncture wounds in only two cases. Treatment consisted of dexamethasone (about 0.1 mg/kg subcutaneously, single dose) and procaine penicillin G (about 25,000 IU/kg subcutaneously, once or twice daily, for 5 to 6 days), as well as revaccination using clostridium and tetanus toxoids. Swelling resolved and elk recovered in 3 to 5 days without complications. Using immunodiffusion, we detected serum antibodies to prairie rattlesnake (*Crotalus viridis viridis*) venom in six of seven affected elk, demonstrating seroconversion in three cases and anamnesis in one elk bitten twice. Venom was undetectable in any serum samples using similar techniques.

Key words: Rocky Mountain elk, *Cervus elaphus nelsoni*, snakebite, zootoxicosis, serum antibodies, immunodiffusion, venom, prairie rattlesnake, *Crotalus viridis viridis*, case report.

Snakebite occurs in livestock on summer ranges throughout the western states, usually as isolated cases. Reactions to bites inflicted by prairie rattlesnakes (*Crotalus viridis viridis*) are relatively mild in domestic ruminants; envenomation causes painful local swelling but rarely mortality (Blood et al., 1983; Fowler, 1987). Horses react more severely to rattlesnake bites, and mortality may occur in untreated cases, particularly those involving the muzzle (McNellis, 1949; Blood et al., 1983). Despite the likelihood of encounters between native wild ruminants and rattlesnakes, cases of snakebite have not been reported. Here, we describe clinical signs, treatment and detection of serum antibodies in cap-

tive Rocky Mountain elk (*Cervus elaphus nelsoni*) after snakebite.

The affected elk were part of a captive herd maintained in two approximately 4 ha pastures at the Colorado Division of Wildlife Foothills Research Facility (Fort Collins, Colorado 80526, USA; 40°35'N, 105°10'W). Individual elk were identified by eartag codes (e.g. A86). Seven of 11 hand-raised yearling cows developed clinical signs suggestive of snakebite between 13 June and 17 July 1987. In all cases, we believe initial observations were made within 2 to 12 hr of envenomation.

The first case (I86) presented on 13 June 1987 with submandibular edema and asymmetrical muzzle swelling; hot, painful swelling was localized to the left upper lip. In addition, unilateral epistaxis and bleeding from the juncture of upper lip and gum were noted, and the animal appeared slightly depressed. Swelling increased over the next 5 hr, but otherwise the animal remained clinically unchanged. Differential diagnoses included trauma, snakebite and phlegmon secondary to pharyngeal abscess (Fowler, 1987). We tentatively diagnosed snakebite based on pain and progression of swelling, and initiated appropriate treatment.

On the following evening, more severe cases were encountered in two elk (A86, D86) from an adjacent pasture. Extensive muzzle and facial swelling, submandibular edema (Fig. 1), anxiousness, hypersalivation, molar grinding and epiphora were common to both cases. Both elk also exhibited inspiratory dyspnea and, after exertion, open-mouth breathing that we presume was caused by restricted nasal airflow from tissue swelling. Unilateral epistaxis

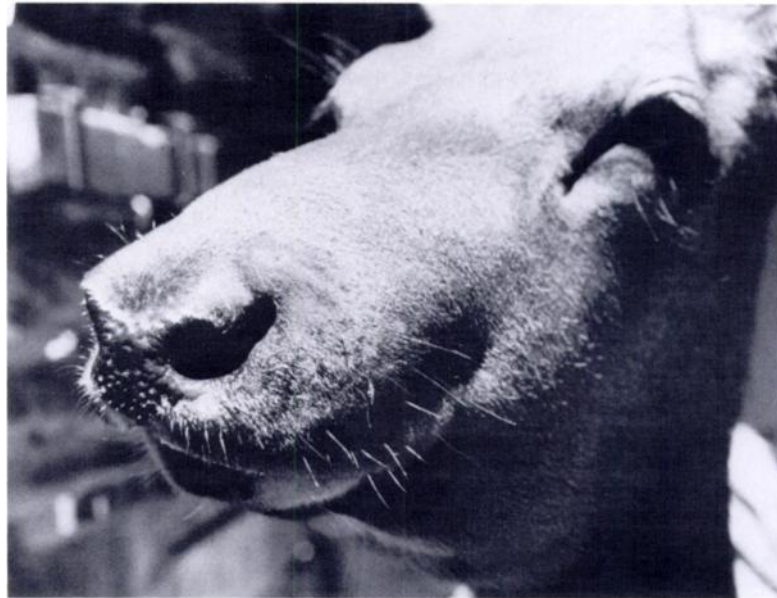

FIGURE 1. Captive elk showing signs of relatively severe reaction to prairie rattlesnake bite, characterized by facial swelling, submandibular edema, epiphora and epistaxis.

and blood-tinged, frothy nasal exudate were seen in one of these cows (D86).

On 14 July 1987, a fourth elk (K86) presented with signs resembling those described in the initial case. Three days later, four more elk (A86, C86, G86, J86), all from a single pasture, presented with the same syndrome. For one of these cows (A86), it was the second snakebite. Severity of swelling varied markedly among these last four cases. In addition to swelling, edema, and other signs previously described, we found paired puncture wounds (≤ 1 mm diameter) (Fig. 2) on the muzzles of two elk (J86, C86). In both cases wounds were about 4 cm apart. The extent of puncture separation was probably influenced by extensive tissue swelling, and we doubt that this spread represented a true reflection of the snake's size.

We treated all elk that showed signs of snakebite, regardless of severity. Therapy was directed toward reducing venom-induced inflammation, as well as preventing secondary bacterial infections in damaged tissue; in particular, we sought to prevent clostridial infections reported as sequelae

in domestic ruminants (Blood et al., 1983; Fowler, 1987). Dexamethasone (Vedco, Anthony Products, Arcadia, California 91006, USA) (about 0.1 mg/kg subcutaneously), procaine penicillin G (Pfizer, Inc., New York, New York 10017, USA) (about 25,000 IU/kg subcutaneously), and boosters of clostridium (Ultrabac-7, Beecham Laboratories, Bristol, Tennessee 31620, USA) and tetanus (Unitox, Jensen-Salsbury Laboratories, Kansas City, Missouri 64141, USA) toxoids were administered to each animal at initial presentation. We continued to treat with penicillin twice daily for 3 days, and once daily for another 2 or 3 days. None of the cases were judged severe enough to warrant polyvalent antivenin therapy.

Snakebite cases resolved within 3 to 5 days after envenomation. Duration of swelling and edema in the most severe cases averaged about 3 days (range 2 to 4 days), with a marked reduction on the fourth day. There appeared to be a direct relationship between severity and duration. In contrast to reactions in domestic species (McNellis, 1949; Parrish et al., 1957; Jones

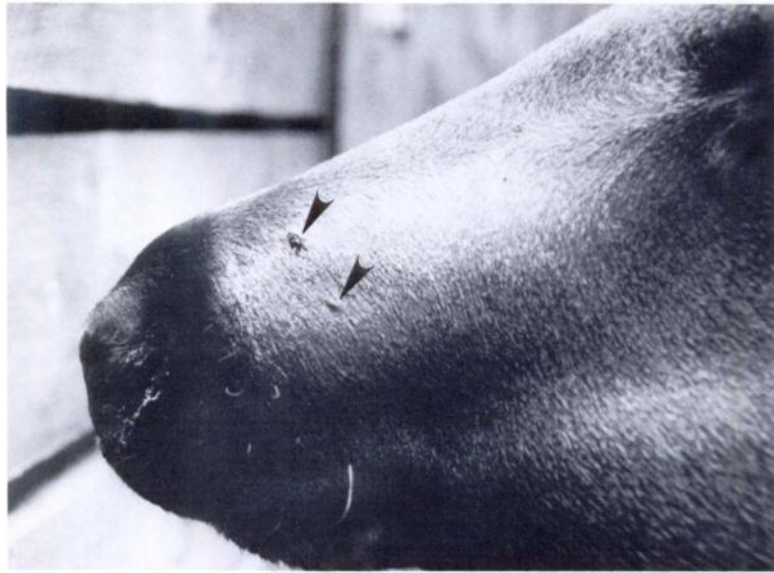


FIGURE 2. Puncture wounds (arrows) from snakebite were observed in only two of eight cases. Separation of wounds (about 4 cm) appeared to be affected by secondary swelling.

and Hunt, 1983; Fowler, 1987; Oehme, 1987), we observed no necrosis, depigmentation or other indications of severe tissue necrosis in any of the affected elk. However, some damage to the nasal cavity lining may have occurred as a result of edema and swelling; elk D86 expelled a mass of clotted blood and sloughed mucous membrane from one nostril the day after being bitten, but showed no other evidence of tissue damage.

To confirm our clinical diagnosis of snakebite, we attempted to demonstrate rattlesnake venom or antibodies to venom in serum from affected elk. We collected blood via jugular venipuncture from the first three snakebite suspects (A86, D86, I86) 18 or 19 days after initial signs appeared; samples from three unaffected elk (C86, G86, J86) bled at that time served as "controls." (None of these elk had shown signs of snakebite previously.) One animal bitten in July (K86) was bled on the day she was observed with swelling, and all elk from the second group (A86, C86, G86, J86, K86) were bled 14 or 17 days after signs appeared. In addition, one elk (D86) bitten in June was bled again at this time

(47 days after envenomation). We harvested serum from all samples ($n = 13$) within 12 hr of collection. A 1.0 ml aliquot of each sample was lyophilized and rehydrated in 0.2 ml 0.9% saline to provide a serum concentrate.

We used standard immunodiffusion techniques (Tu et al., 1980) in qualitatively analyzing both sera and concentrates for presence of venom or antibodies. All assays were performed on seven-well 0.9% agarose immunodiffusion plates (ICN Immunobiologicals, P.O. Box 1200, Lisle, Illinois 60532, USA). Controls included *Crotalidae* Polyvalent Antivenin (Wyeth Laboratories, Inc., Marietta, Pennsylvania 17547, USA) as a positive antibody source, 0.9% saline as a negative control and crude prairie rattlesnake venom (Miami Serpentarium Laboratories, 12655 South Dixie Highway, Miami, Florida 33156, USA) as a positive control. We used prairie rattlesnake venom because this is the only species of rattlesnake indigenous to our area (Glenn and Straight, 1982). Antivenin and venom were concentrated as previously described for serum for use as controls in concentrate assays. For all assays, we added 20 μ l of

control reagents or sera to appropriate wells and then incubated plates for 24 hr at about 22 C. After incubation, plates were deproteinized in 0.9% saline (four or five changes/day) for 3 days, stained with 0.1% amidoblack (K and K Manufacturers, Inc., Plainville, New York 11803, USA) in 10% acetic acid for 5 min, then destained in 10% acetic acid (four or five changes/day) for 3 days. Each unknown was assayed in duplicate on the same plate. We interpreted formation of precipitin lines between antigen and antibody wells as positive reactions. These were subjectively compared by location and intensity with those of controls on the same plate.

Antibodies to prairie rattlesnake venom were present in eight of nine serum concentrates from six of seven affected elk (A86, C86, D86, G86, I86, J86) bled ≥ 14 days after being bitten; antibodies were not detected in concentrates from control elk (C86, G86, J86) bled before they were bitten, or from one of the affected elk (K86) (Table 1). Only one unconcentrated sample had detectable antibody levels; that serum was from the elk (A86) bitten twice, and was collected 14 days after her second exposure. We did not detect venom in any serum or concentrated serum samples. Seroconversion was demonstrable in three of four elk (C86, G86, J86) where paired sera were available (Table 1). Although relatively low antibody response was induced by a single envenomation, circulating antibody persisted for ≥ 47 days postexposure. In addition, one anamnestic response to venom produced at least a fivefold increase in circulating antibody; this may have reduced severity of that elk's (A86) response to the second bite.

We doubt that prairie rattlesnake envenomation represents a significant source of morbidity or mortality in free-ranging elk. Dispersion and altitudinal separation of summer ranges for elk (often $> 2,000$ m; Adams, 1982) and rattlesnake (usually $< 2,200$ m; Klauber, 1972) probably reduce likelihood of these encounters. Captive elk confined at elevations lower than

TABLE 1. Presence of antibodies to prairie rattlesnake venom in concentrated serum from envenomated elk, as detected by immunodiffusion.

Elk number	Days from envenomation	Immunodiffusion result ^a
I86	+19 ^b	+
A86	+18	+
	+14 (+32) ^c	++
D86	+18	+
	+47	+
K86	0	0
	+17	0
C86	-15	0
	+14	+ ^d
G86	-15	0
	+14	+ ^d
J86	-15	0
	+14	+ ^d

^a 0 = negative, + = positive, ++ = strong positive.

^b +, positive after envenomization; -, negative before envenomization.

^c 14 days after second exposure, 32 days after initial exposure.

^d Seroconversion.

typical elk summer range (and within rattlesnake ranges) may be at somewhat greater risk. Elevation of our foothills facility is near 1,540 m, and prairie rattlesnakes are relatively common in the vicinity. In a similar setting, snakebite was suspected but not confirmed as the cause of death in three bull elk held by the Wyoming Game and Fish Department Sybille Research Station (Bosler Route, Wheatland, Wyoming, USA, elevation about 1,900 m) (E. T. Thorne, pers. comm.). Preventing snakebite in elk (and other captive wildlife) maintained within rattlesnake ranges may be aided by using off-ground feed and water containers and by storing feed in rodent-proof areas some distance from pen facilities. We suspect that proximity of stored feed and attendant rodent populations attracted one or more rattlesnakes to the vicinity of our elk pens. Feed sheds may have served as foci of rattlesnake activity and subsequent elk/rattlesnake interactions; elk group behavior probably facilitated multiple attacks.

We believe secondary bacterial infections represent the greatest potential for venom-related mortality in elk. Both *Clos-*

tridium sordellii (M. W. Miller, unpubl. data) and *C. septicum* (Howe, 1981) have been linked to elk deaths, and elk are probably susceptible to other clostridial diseases of domestic livestock as well. In captive elk, conservative treatment consisting of corticosteroids (single dose), antibiotics and revaccination should reduce probability of mortality after snakebite. In the absence of secondary bacterial infections, our observations suggest that elk are capable of complete and uneventful recovery from prairie rattlesnake envenomation.

We thank L. E. Lovett for typing this manuscript. Comments from R. M. Bartmann, D. A. Reed, M. R. Szymczak, and three anonymous reviewers were helpful in revising our original draft. Our work was supported by Federal Aid to Wildlife Restoration Project W-153-R-2.

LITERATURE CITED

- ADAMS, A. W. 1982. Migration. In *Elk of North America: Ecology and management*, J. W. Thomas and D. E. Toweill (eds.). Stackpole Books, Harrisburg, Pennsylvania, pp. 301-321.
- BLOOD, D. C., O. M. RADOSTITS, AND J. A. HENDERSON. 1983. *Veterinary medicine*, 6th ed. Bailliere Tindall, London, England, 1310 pp.
- FOWLER, M. E. 1987. Zootoxins. In *Current veterinary therapy, food animal practice 2*, J. L. Howard (ed.). W. B. Saunders Co., Philadelphia, Pennsylvania, pp. 463-465.
- GLENN, J. L., AND R. C. STRAIGHT. 1982. The rattlesnakes and their venom yield and lethal toxicity. In *Rattlesnake venoms*, A. T. Tu (ed.). Marcel Dekker, Inc., New York, New York, pp. 51-56.
- HOWE, D. L. 1981. Miscellaneous bacterial diseases: Malignant edema. In *Infectious diseases of wild mammals*, 2nd ed., J. W. Davis, L. H. Karstad, and D. O. Trainer (eds.). Iowa State University Press, Ames, Iowa, pp. 421-422.
- JONES, T. C., AND R. D. HUNT. 1983. *Veterinary pathology*, 5th ed. Lea and Febiger, Philadelphia, Pennsylvania, 1792 pp.
- KLAUBER, L. M. 1972. *Rattlesnakes: Their habits, life histories, and influence in mankind*, Vol. 1. University of California Press, Berkeley and Los Angeles, California, pp. 510-520.
- MCNELLIS, R. 1949. Rattlesnake bite. *Journal of the American Veterinary Medical Association* 114: 145-146.
- OEHME, F. W. 1987. Snake bite. In *Current therapy in equine medicine 2*, N. E. Robinson (ed.). W. B. Saunders Co., Philadelphia, Pennsylvania, pp. 663-664.
- PARRISH, H. M., J. E. SCATTERDAY, AND C. B. POLLARD. 1957. The clinical management of snake venom poisoning in domestic animals. *Journal of the American Veterinary Medical Association* 130: 548-551.
- TU, A. T., J. STERMITZ, AND H. ISHIZAKI. 1980. Comparative study of pit viper venoms of genera *Trimeresurus* from Asia and *Bothrops* from America: An immunological and isotachopheric study. *Comparative Biochemistry and Physiology* 66B: 249-254.

Received for Publication 3 October 1988.