



LESIONS ASSOCIATED WITH METAZOAN PARASITES OF WILD PLATYPUSES (ORNITHORHYNCHUS ANATINUS)

Authors: Whittington, Richard J., and Spratt, David M.

Source: Journal of Wildlife Diseases, 25(4) : 521-526

Published By: Wildlife Disease Association

URL: <https://doi.org/10.7589/0090-3558-25.4.521>

BioOne Complete (complete.BioOne.org) is a full-text database of 200 subscribed and open-access titles in the biological, ecological, and environmental sciences published by nonprofit societies, associations, museums, institutions, and presses.

Your use of this PDF, the BioOne Complete website, and all posted and associated content indicates your acceptance of BioOne's Terms of Use, available at www.bioone.org/terms-of-use.

Usage of BioOne Complete content is strictly limited to personal, educational, and non - commercial use. Commercial inquiries or rights and permissions requests should be directed to the individual publisher as copyright holder.

BioOne sees sustainable scholarly publishing as an inherently collaborative enterprise connecting authors, nonprofit publishers, academic institutions, research libraries, and research funders in the common goal of maximizing access to critical research.

LESIONS ASSOCIATED WITH METAZOAN PARASITES OF WILD PLATYPUSES (*ORNITHORHYNCHUS ANATINUS*)

Richard J. Whittington¹ and David M. Spratt²

¹ New South Wales Department of Agriculture & Fisheries, Central Veterinary Laboratory, Roy Watts Road, Glenfield 2167, Australia

² Division of Wildlife and Ecology, Commonwealth Scientific and Industrial Research Organisation, P.O. Box 84, Lyneham 2602, Australia

ABSTRACT: Pathological findings associated with helminth and arthropod parasites of four wild platypuses (*Ornithorhynchus anatinus*) are described. Fourth-stage larval rhabditoid nematodes (?Cylindrocorporidae) found partially embedded in the stratum corneum were associated with mild acanthosis, orthokeratotic hyperkeratosis and inconstant subacute dermatitis. A filarioid nematode (?Lemdaninae) was found in hypodermal lymphoid tissue. A larval trichostrongyloid nematode was found in the dermis, with no evidence of host response. An undescribed species of trombiculid mite ("chigger") was found in the pelage and attached to superficial stratum corneum. Focal inclusions of eosinophilic material within stratum corneum, interpreted as mite gel saliva produced during formation of the "stylostome," were also observed. The tick *Ixodes ornithorhynchi* punctured the epidermis causing adnexal trauma, dermal haemorrhage and chronic active dermatitis. The digenean *Mehlisia ornithorhynchi* was present in the small intestine of one animal and was associated with mild catarrhal enteritis.

Key words: Platypus, *Ornithorhynchus anatinus*, Monotremata, parasites, helminths, arthropods, pathology, skin, small intestine, survey.

INTRODUCTION

The platypus (*Ornithorhynchus anatinus*, Monotremata) is known to be infected with the trematodes *Mehlisia ornithorhynchi*, *Maritrema ornithorhynchi* and *Moreauia mirabilis* (Johnston, 1913, 1915; Hickman, 1955; Mackerras, 1958), the fleas *Pygiopsylla hoptia* and *P. zethi* (Dunnet and Mardon, 1974), and the ticks *Ixodes ornithorhynchi* and *Amblyoma triguttatum triguttatum* (Roberts, 1970). The only nematode purportedly collected from the platypus, *Tasmanema mundayi*, is considered a dubious host record (Spratt and Whittington, 1989). Platypuses are seldom available for pathological examination because they are closely protected, semi-aquatic and fossorial. Four wild platypuses found drowned in fishing nets during a survey of fish species were available for examination. Novel metazoan parasites, three genera of nematodes (Spratt and Whittington, 1989) and a mite, were found associated with the skin. Gross and histological findings associated with these parasites, *Mehlisia ornithorhynchi* and the platypus tick *Ixodes ornithorhynchi*, are described.

MATERIALS AND METHODS

Host data are listed as follows. Animal one was a juvenile male, approximately 6-mo-old, weighing 1,100 g, collected at Abercrombie River (34°0'S, 149°15'E), New South Wales on 27 April 1985. Animals two and three were adult males, >2-yr-old, weighing 2,200 and 1,700 g, collected from the Upper Murrumbidgee River (35°15'S, 149°0'E), New South Wales on 17 January 1986. Animal four was an adult female, 18-mo-old, weighing 1,070 g, collected from the Queanbeyan River (35°30'S, 149°15'E), New South Wales on 29 May 1986.

Following removal from the net, each animal was packed in ice, forwarded to the laboratory and necropsy was performed within 24 hr of the estimated time of drowning. The age and sex of each animal was determined from the morphology of the spur (Temple-Smith, 1973, in Grant, 1984). The skin, with attached panniculus muscle, was removed and fixed in 10% neutral buffered formalin together with gastrointestinal tract, viscera, bill, tongue, diaphragm and other skeletal muscles. Fixed skin was soaked in tap water to soften, the pelage was shaved, and then it, the skin surface and deep skin scrapings were examined with a stereomicroscope. The gastrointestinal tract was opened longitudinally and similarly examined. Fixed tissues were embedded in paraffin, sectioned at 5 µm and stained with haematoxylin and eosin. Blood smears, prepared from heart blood, were stained with Giemsa. Rectal feces

were examined following sedimentation and helminth egg counts were conducted using a counting chamber. Parasites were measured by microscopy using a calibrated eyepiece micrometer. Representative parasites are deposited in the parasite collection of the Division of Wildlife and Ecology (Commonwealth Scientific and Industrial Research Organisation, Lyneham 2602, Australia; W/L and P prefixes, accession number is given in results) and as stated in Spratt and Whittington (1989). Representative histological sections are deposited in the Registry of Zoo Animal Pathology (Taronga Park Zoological Gardens, Mosman 2088 Australia; TZ prefix, accession number is given in results).

RESULTS AND DISCUSSION

Three nematode and two arthropod species were found associated with the skin. *Mehlisia ornithorhynchi* (Digenea; W/L T181), found in the proximal 30 cm of the small intestine of Animal four, was the only other metazoan found. One hundred fourteen mature digeneans were present and the fecal egg count was 400 eggs/g of feces. Grossly, inflammation was not present, and, microscopically, the mild catarrhal enteritis could not be attributed solely to the digenean because developmental stages of protozoan parasites were present also in the mucosa. The latter will be described elsewhere. McColl (1983) found *M. ornithorhynchi* in only one of 20 platypuses that died after a variable period in captivity in Victoria (Australia), supporting the finding in this study that the intestinal digeneans known from the platypus are not common infections.

Fourth-stage larval rhabditoid nematodes tentatively placed in the family Cyndrocorporidae (Spratt and Whittington, 1989) (W/L N2723, P92) were found in the skin of Animals one, two and four. Nematodes could be found easily in most skin scrapings and in histological sections of skin from these animals (TZ B0014, B0015, B0017, B0043). The larvae were 0.66 to 1.34 mm (\bar{x} = 1.01 mm; n = 10) in length. The anterior end of each nematode was partially embedded in the epidermis or in hair follicles, and the posterior end was free in the pelage. Histologically

in transverse section, each nematode appeared to be enclosed by a tunnel of epidermis; in longitudinal section, larvae projected into the pelage from a pit or channel in the stratum corneum. Most nematodes were located superficially; however a few were found in the epithelium of deep hair follicles. A group of transverse sections of nematodes was found in the hypodermis of Animal one but this was the only instance in many sections where nematodes had breached the stratum basale. There was minimal host response to the parasite. Mild orthokeratotic hyperkeratosis and/or acanthosis occurred near larvae, although mild orthokeratotic hyperkeratosis was diffuse in Animal four. Mild cellular infiltrates containing lymphocytes with small numbers of plasma cells and eosinophils occurred in the dermis associated with some larvae (Fig. 1). This nematode has been determined retrospectively to be identical to that previously identified by one of us (DMS) as *Capillaria* sp. in a section from a platypus with ulcerative dermatitis (Munday and Peel, 1983). This establishes that the nematode is present in both mainland Australia and Tasmania.

An adult female filarioid nematode, tentatively placed in the Lemninae (Spratt and Whittington, 1989) (W/L N2910), was found in hypodermal lymphoid tissue from the dorsum of Animal two. Three transverse sections were observed histologically (TZ B0015, B0043); these measured up to 190 μ m in diameter and contained numerous microfilariae (Fig. 2). The filarioid was surrounded by lymphocytes with small numbers of plasma cells, macrophages and fibroblasts. We were unable to determine whether the nematode was present within a normal lymphoid follicle, or within a lymph vessel that had subsequently accumulated inflammatory cells. Fragments of this gravid female nematode, which contained microfilariae in the uteri, were recovered from fixed skin. Similar fragments also were recovered from fibrous dermal connective tissue of two platypuses which were not examined histologically

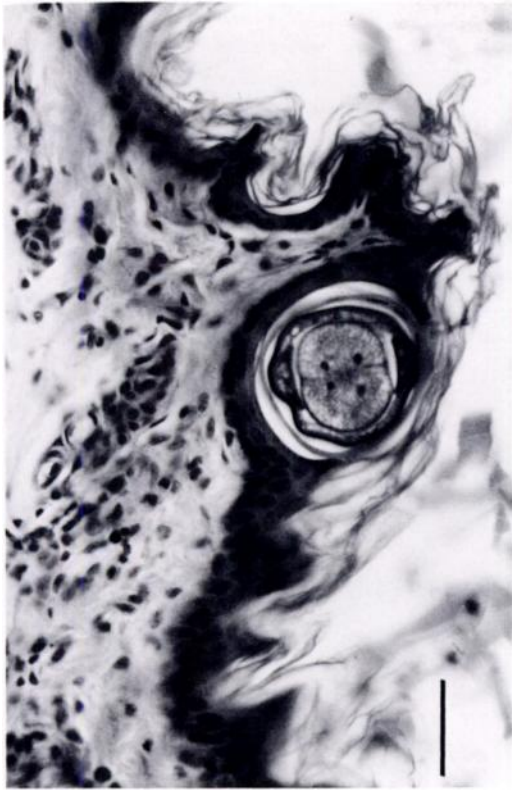

FIGURE 1. Fourth-stage rhabditoid larva (?Cylindrocorporidae) in the skin of a platypus (Animal four); the parasite is enclosed within stratum corneum. There is mild infiltration of the dermis by lymphocytes, with small numbers of plasma cells and eosinophils and there is a diffuse, mild, orthokeratotic hyperkeratosis. H&E. Bar = 50 μ m.

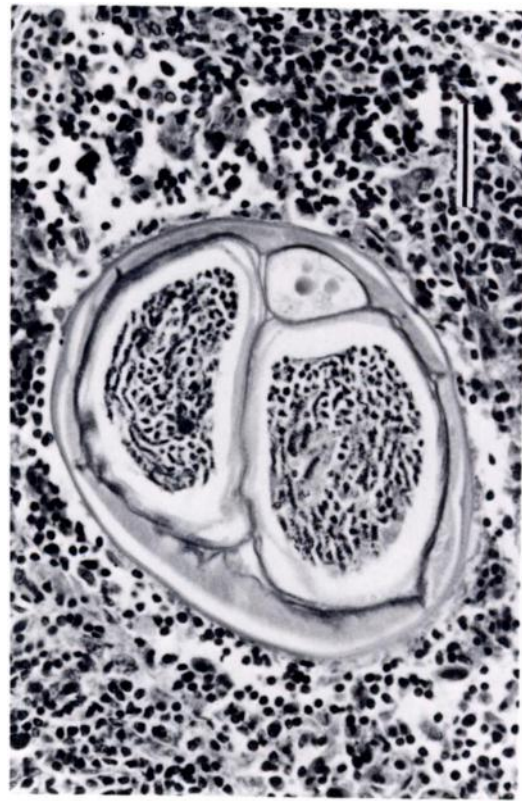


FIGURE 2. Gravid female filarioid nematode (?Lemdaninae) within hypodermal lymphoid tissue of a platypus (Animal two). H&E. Bar = 50 μ m.

(Spratt and Whittington, 1989). The largest fragment was 2.30 mm long and 0.18 mm wide. A similar gravid female filarioid has since been recovered from a platypus from Georges River, St. Helens, Tasmania (Spratt, unpubl.) (W/L N3041, P109). A fragment of this nematode recovered from subcutaneous tissue was 11.40 mm long. Cross sections in histological sections were 103 to 152 μ m in diameter and were not associated with host reaction. Male and female specimens of another filarioid, *Cercopithifilaria johnstoni*, a parasite known from a range of eutherian and marsupial hosts in eastern Australia (Spratt and Haycock, 1988), have recently been recovered from platypuses in Tasmania, but are dis-

tinct from the filarioid reported here (Spratt and Obendorf, unpubl.).

A single transverse section of a larval trichostrongyloid nematode (Spratt and Whittington, 1989) was observed in the dermis of Animal one. The presence of a prominent synlophe differentiated this nematode from others found in the platypus and indicated relationship with the Trichostrongyloidea. Tissue damage or inflammation was not associated with this parasite.

Larval trombiculid mites ("chiggers") (W/L AR156) measuring 1.10 mm long and 0.50 mm wide and belonging to an unnamed taxon not previously encountered in Australia were found deep in the pelage of Animals one and four. Also, larvae were observed in capsules attached to hairs (Sweatman, 1977). Mites were found

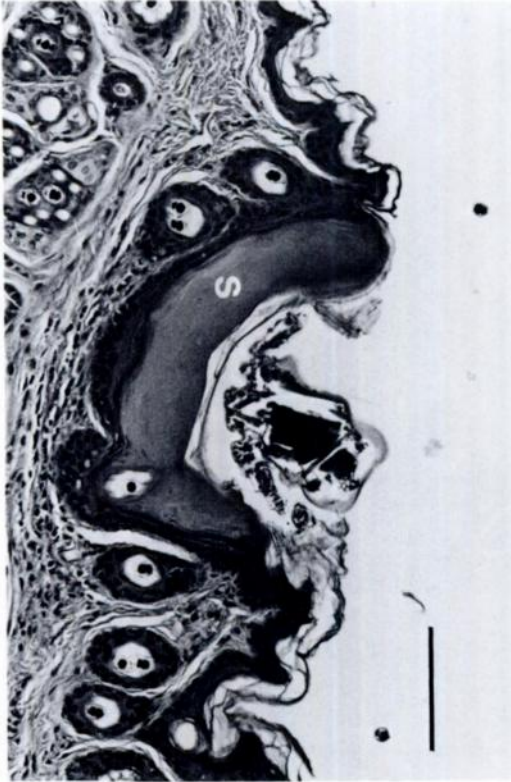

FIGURE 3. Trombiculid mite lying on the epidermis of a platypus (Animal one). Note the amorphous eosinophilic gel saliva (S). H&E. Bar = 100 μ m.

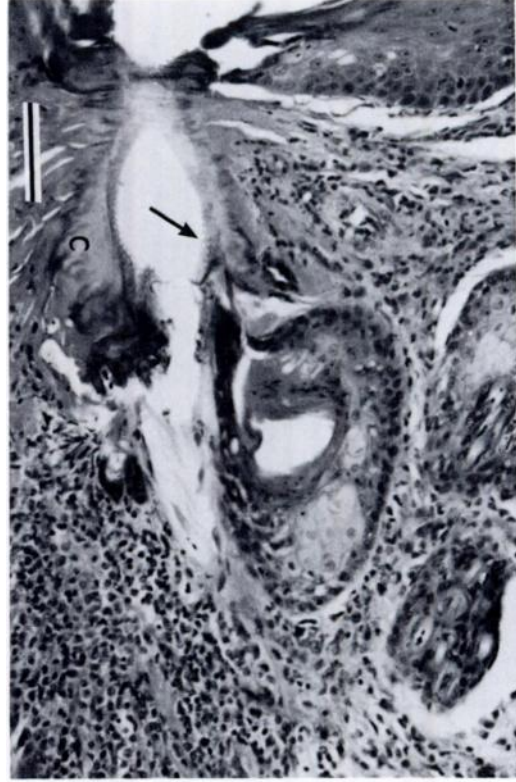


FIGURE 4. Penetrating mouthparts (arrow) of *Ixodes ornithorhynchi* surrounded by eosinophilic cement substance (c). Note the adnexal trauma and chronic, active dermatitis. H&E. Bar = 100 μ m.

in histological section only in Animal one (TZ B0014). Most often they were located free in the pelage, although one was found lying on the stratum corneum (Fig. 3). This mite sat in a shallow depression of the epithelium which was lined by amorphous to faintly lamellated eosinophilic material. There was no inflammatory response in the epithelium or underlying dermis. Numerous amorphous to lamellated, eosinophilic inclusions were found in sections of epidermis from Animal one. These were either on the surface of the stratum corneum or present as urn-shaped pockets within the stratum corneum. In all cases, one to several layers of cornified epithelium enclosed the eosinophilic material and in some the lamellated material contained degenerate epithelial cell nuclei. A linear cleft oriented perpendicular to the skin surface

was present in some of these eosinophilic bodies. These lesions resulted from injection of hyaline gel saliva into the epidermis by the mite during formation of the "stylostome" or feeding tube, and are not believed to be due to host reaction (Schumacher and Hoeppli, 1963; Sweatman, 1977). We suspect that the "chiggers" are dislodged easily from the epidermis during routine tissue processing.

Larval, nymphal and adult female ticks, *Ixodes ornithorhynchi* (W/L AR139, 145, 157) occurred on all animals (mean intensity = 42, SE = 18.3, range 7 to 90). Generally, they were attached to the less densely haired parts of the forelimbs and hindlimbs; 20 engorged females were attached to the dorsal sacral skin of Animal three and one engorged female was attached to the ventral surface of the tail of

Animal four. There was no macroscopic evidence of dermatitis, despite numerous ticks often being attached to small areas of skin on the legs. However, small puncture marks were visible at the sites of attachment, after removal of ticks.

Microscopically, the mouthparts of ticks penetrated the stratum basale and were surrounded in the dermis by deeply eosinophilic, amorphous material which extended upwards to the adjacent epidermis (Fig. 4) (TZ B0043). This eosinophilic material, which is thought to be produced by the tick, serves to anchor the tick to the host and has been called cement substance (Schumacher and Hoeppli, 1963). Attachment of ticks was associated with chronic, active dermatitis. Adnexal trauma, dermal haemorrhage and marked cellular infiltration occurred around feeding sites. The cellular infiltrate varied from acute (neutrophils with some eosinophils) and subacute (lymphocytes and macrophages) to chronic (fibroblasts). Bacterial colonies were present on the stratum corneum at the site of penetration of mouthparts. *Ixodes ornithorhynchi* is known throughout the range of the platypus, although the male tick has not been described (Roberts, 1970).

Intensities of 200 ticks have been reported from individual platypuses (Temple-Smith, 1973, in Whittington and Grant, 1983). Even so, the latter authors found no correlation between packed cell volume and tick intensities ranging from 0 to 100 ($\bar{x} = 33$) in 45 platypuses. Intensities of 6 to 10 *I. ornithorhynchi* were found on two of 20 captive platypuses by McColl (1983). Mackerras (1959) and Collins et al. (1986) suggested that *I. ornithorhynchi* may be the vector of *Theileria ornithorhynchi*, which was present in a small proportion of the erythrocytes in the four animals in our study. Fleas, which are known to infect the platypus (Dunnet and Mardon, 1974), were not found in this study.

Adult forms of several of these parasites and life cycles of all of them remain unknown. However, the soil and nesting ma-

terial of the burrow of the platypus may be a significant environment, insofar as completion of their life cycles and transmission is concerned. These parasites apparently had little effect on their hosts; this suggests a well-adapted and probably lengthy association with the platypus. This is supported by the knowledge that at least three of the parasites, the filarioid, the rhabditoid and the tick, are present in populations of platypus that have been isolated since the physical separation of Tasmania from mainland Australia, an event which occurred most recently circa 12,000 to 13,500 yr BP (Galloway and Kemp, 1981).

Although there was no evidence of significant pathology associated with any of these parasites, they cannot be discounted as vectors of disease or as potential pathogens. The tick, the trombiculid mite and the rhabditoid nematode may be capable of introducing microbial pathogens into the skin during penetration of the epidermis. The rhabditoid was found in direct association with the lesions of severe ulcerative dermatitis in the cases described by Munday and Peel (1983).

ACKNOWLEDGMENTS

We are indebted to officers of the NSW Department of Agriculture & Fisheries and the Australian Capital Territory Parks and Conservation Service for sending platypuses to one of us (RJW) promptly. The NSW National Parks and Wildlife Service supported this work by providing licences. L. M. Angel and Tom Cribb, and R. Domrow kindly offered advice concerning identification of the trematodes and mites, respectively. B. L. Munday generously provided sections of skin from platypuses in Tasmania while D. Obendorf provided a specimen and a section of a filarioid. I. K. Barker and P. J. A. Presidente offered valuable criticism of an earlier draft of the manuscript.

LITERATURE CITED

- COLLINS, G. H., R. J. WHITTINGTON, AND P. J. CANNFIELD. 1986. *Theileria ornithorhynchi* Mackerras, 1959 in the platypus, *Ornithorhynchus anatinus* (Shaw). *Journal of Wildlife Diseases* 22: 19–24.
- DUNNET, G. M., AND D. K. MARDON. 1974. A monograph of Australian fleas (Siphonaptera).

- Australian Journal of Zoology, Supplementary Series, No. 30: 1-273.
- GALLOWAY, R. W., AND E. M. KEMP. 1981. Late Cainozoic environments in Australia. In Ecological biogeography of Australia, A. Keast (ed.). Junk, The Hague, Netherlands, pp. 53-80.
- GRANT, T. R. 1984. The platypus. New South Wales University Press, Kensington, New South Wales, Australia, 76 pp.
- HICKMAN, V. V. 1955. On *Maritrema ornithorhynchi* sp. n. a new trematode from the monotreme, *Ornithorhynchus anatinus* Shaw, with a key to the genus *Maritrema* Nicoll. Revista Iberica de Parasitologica, Granada (Espana). Tomo extraordinario Marzo 1955: 181-191.
- JOHNSTON, S. J. 1913. On some trematode parasites of marsupials and of a monotreme. Proceedings of the Linnean Society of New South Wales 37: 727-740.
- . 1915. On *Moreauia mirabilis* gen. et sp. nov., a remarkable trematode parasitic in *Ornithorhynchus*. Proceedings of the Linnean Society of New South Wales 40: 278-287.
- MACKERRAS, M. J. 1958. Catalogue of Australian mammals and their recorded internal parasites. Part 1. Monotremes and marsupials. Proceedings of the Linnean Society of New South Wales 83: 101-125.
- . 1959. The haematozoa of Australian mammals. Australian Journal of Zoology 7: 105-135.
- MCCOLL, K. A. 1983. Pathology in captive platypus (*Ornithorhynchus anatinus*) in Victoria, Australia. Journal of Wildlife Diseases 19: 118-122.
- MUNDAY, B. L., AND B. F. PEEL. 1983. Severe ulcerative dermatitis in platypus (*Ornithorhynchus anatinus*). Journal of Wildlife Diseases 19: 363-365.
- ROBERTS, F. H. S. 1970. Australian ticks. Commonwealth Scientific and Industrial Research Organisation, Melbourne, Australia, 267 pp.
- SCHUMACHER, H. H., AND R. HOEPLI. 1963. Histochemical reactions to trombiculid mites, with special reference to the structure and function of the "stylostome." Zeitschrift für Tropenmedizin und Parasitologie 14: 192-208.
- SPRATT, D. M., AND P. HAYCOCK. 1988. Aspects of the life history of *Cercopithifilaria johnstoni* (Nematoda: Filarioidea). International Journal for Parasitology 18: 1087-1092.
- , AND R. J. WHITTINGTON. 1989. Nematode parasites from the skin of the platypus, *Ornithorhynchus anatinus*, (Monotremata). Systematic Parasitology 13: In press.
- SWEATMAN, G. K. 1977. Mites and pentastomes. In Parasitic diseases of wild mammals, J. W. Davies and R. C. Anderson (eds.). Iowa State University Press, Ames, Iowa, pp. 3-64.
- WHITTINGTON, R. J., AND T. R. GRANT. 1983. Haematology and blood chemistry of the free-living platypus, *Ornithorhynchus anatinus* (Shaw) (Monotremata: Ornithorhynchidae). Australian Journal of Zoology 31: 475-482.

Received for publication 20 December 1988.