

Pyogranulomatous Pneumonias Due to *Nocardia asteroides* and *Staphylococcus epidermidis* in Two Koalas (*Phascolarctos cinereus*)

Authors: Wigney, D. I., Gee, D. R., and Canfield, P. J.

Source: Journal of Wildlife Diseases, 25(4) : 592-596

Published By: Wildlife Disease Association

URL: <https://doi.org/10.7589/0090-3558-25.4.592>

BioOne Complete (complete.BioOne.org) is a full-text database of 200 subscribed and open-access titles in the biological, ecological, and environmental sciences published by nonprofit societies, associations, museums, institutions, and presses.

Your use of this PDF, the BioOne Complete website, and all posted and associated content indicates your acceptance of BioOne's Terms of Use, available at www.bioone.org/terms-of-use.

Usage of BioOne Complete content is strictly limited to personal, educational, and non - commercial use. Commercial inquiries or rights and permissions requests should be directed to the individual publisher as copyright holder.

BioOne sees sustainable scholarly publishing as an inherently collaborative enterprise connecting authors, nonprofit publishers, academic institutions, research libraries, and research funders in the common goal of maximizing access to critical research.

SHORT COMMUNICATIONS

Journal of Wildlife Diseases, 25(4), 1989, pp. 592–596
© Wildlife Disease Association 1989

Pyogranulomatous Pneumonias Due to *Nocardia asteroides* and *Staphylococcus epidermidis* in Two Koalas (*Phascolarctos cinereus*)

D. I. Wigney, D. R. Gee, and P. J. Canfield, Department of Veterinary Pathology, University of Sydney, New South Wales 2006, Australia

ABSTRACT: Pyogranulomatous pneumonia was detected in two koalas (*Phascolarctos cinereus*). *Nocardia asteroides* was isolated from one koala with extensive pneumonia, pleurisy and splenitis. *Staphylococcus epidermidis* was isolated from a second koala with pneumonia restricted to the left cranial lobe. Both koalas were in poor condition and had underlying urogenital disease. It was concluded that each organism had acted as an opportunistic pathogen in its compromised host.

Key words: *Phascolarctos cinereus*, koala, pyogranulomatous pneumonia, *Nocardia asteroides*, *Staphylococcus epidermidis*.

Pneumonia occurs commonly in both free-living (Canfield, 1987a) and captive (Canfield et al., 1986) koalas (*Phascolarctos cinereus*). Organisms isolated include *Bordetella bronchiseptica* (McKenzie et al., 1979), *Pseudomonas aeruginosa* (McKenzie, 1981; Oxenford et al., 1986), *Corynebacterium* spp. (Rahman, 1957; Francis, 1963), *Streptobacillus moniliformis* (Russell and Straube, 1979), *Mycobacterium ulcerans* (McOrist et al., 1985), *Cryptococcus neoformans* (Backhouse and Bolliger, 1960) and *Toxoplasma gondii* (Dickens, 1975). Many of these organisms are thought to act as opportunistic pathogens in koalas, following changed habitat, overcrowding and intercurrent diseases. We report two cases of pyogranulomatous pneumonia in free-living koalas from the north coast of New South Wales (Australia).

The first case involved a 6- to 7-yr-old male koala with lethargy, continual vocalization, generalized lymphadenomeg-

aly and pain on palpation of the right thoracic and abdominal walls. Blood was collected from the cephalic vein. The koala was determined to be hypoalbuminemic at 30 g/liter albumin (reference range (RR) 34–50 g/liter), anemic with a hematocrit of 0.25 liter/liter (RR 0.29–0.44 liter/liter) and had a neutrophilia of 18.8×10^9 cells/liter (RR $0.5\text{--}6.3 \times 10^9$ /liter) (reference ranges were established by Clinical Pathology Laboratory, Department of Veterinary Pathology, University of Sydney, Sydney, Australia). The animal was cared for and force fed by members of a local koala preservation society but, as there was little improvement after 2 wk, it was killed with Na barbiturate injection.

Necropsy was performed 18 hr following death. The animal had no fat reserves but little muscle wasting (weight was 6.8 kg; crown rump length was 54.5 cm). A twig, approximately 5 cm long, was embedded in the left side of the nasal septum. The right pleural space was obliterated by yellow gelatinous and caseous material. Within this material were nodules, <1 cm in diameter, consisting of yellow, opaque, viscous fluid centres surrounded by white firm tissue. Most of the parenchyma of the right lung was replaced by similar material and had an adherent, thickened, white pleura. The left lung contained a single caseous nodule 1 cm in diameter.

Tissue was fixed in 10% buffered formalin, embedded in paraffin and processed routinely. Sections were stained with

haematoxylin and eosin (H and E) and special stains. Microscopically, within the right lung and pleural cavity there were fibrovascular proliferation, fibrinous exudate and infiltrates of neutrophils, giant cells and mononuclear cells consistent with pyogranulomatous inflammation. Large numbers of beaded Gram-positive bacteria, with branching filaments, approximately 1 μm in width and up to 30 μm in length were seen in a Brown and Brenn stain (Culling et al., 1985). Organisms were present both extracellularly and within giant cells, and appeared acid-alcohol fast using Putt's modification (Putt, 1951) of the Ziehl-Neelsen stain (Fig. 1). In addition, there was focal pyogranulomatous splenitis containing small numbers of acid-fast organisms, benign hyperplasia of peripheral lymph nodes and mild, chronic prostatitis.

At necropsy, the right lung tissue was heat seared, incised with a sterile scalpel blade and several moistened bacteriological swabs introduced into the viscous exudate. Numerous degenerate inflammatory cells and large numbers of Gram-positive filaments were present in a Gram stained smear. Sheep blood (5%) agar plates were inoculated and incubated at 37 C aerobically, and anaerobically in a special gas mixture (10% CO₂, 10% H₂, 80% N₂). Ogawa egg medium (1%) (Ogawa and Motomura, 1970), for isolation of mycobacteria, also was incubated aerobically. *Nocardia asteroides* was isolated in pure culture from the aerobic media and identified based on the methods of Mishra et al. (1980).

The second case was a 6-yr-old female koala that had an inflamed digit on the right forepaw. Four mo previously the animal had been treated for cystitis over a 2 mo period and appeared to have recovered. After initiation of antimicrobial therapy for the affected digit the animal deteriorated rapidly and was euthanased with Na barbiturate. At necropsy, 24 hr later, the animal weighed 3.2 kg and had a crown-rump length of 47 cm. The lungs

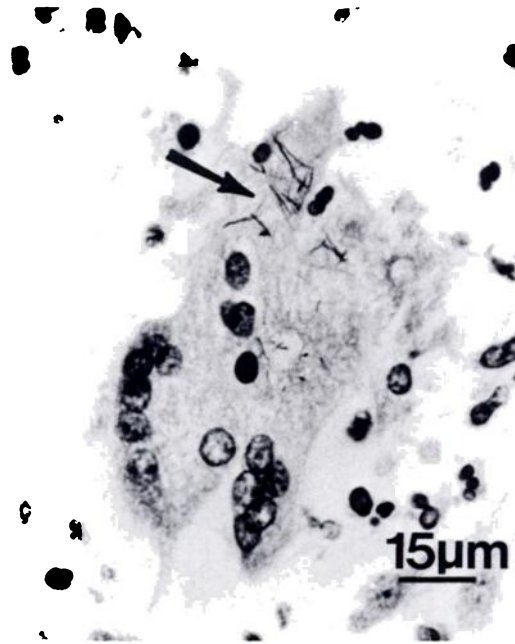


FIGURE 1. Branching filamentous organisms, *Nocardia asteroides* (arrow), within a giant cell from a koala. Ziehl-Neelsen stain.

appeared normal except for the left cranial lobe which was adherent to the thoracic wall. The lung parenchyma in this region was yellow and firm. There was marked muscle wasting, a thickened bladder wall and a 1 × 2 cm right paraovarian cyst.

Microscopically, degenerate neutrophils filled most of the airways and alveolar spaces in the affected portion of lung. Aggregates of granular, amorphous, basophilic material that contained dense clusters of Gram-positive cocci, were associated with either neutrophil clusters or macrophages and giant cells (Fig. 2). Fibrin deposits and areas of fibrosis were associated with plasma cell infiltrates. The inflammation was considered pyogranulomatous. Isolated Gram-positive cocci were also scattered throughout the tissue and were situated both intra- and extracellularly. In addition, there was a mild chronic cystitis and a similar process affected the urogenital sinus.

Microbiological specimens of lung were collected and processed as in the previous

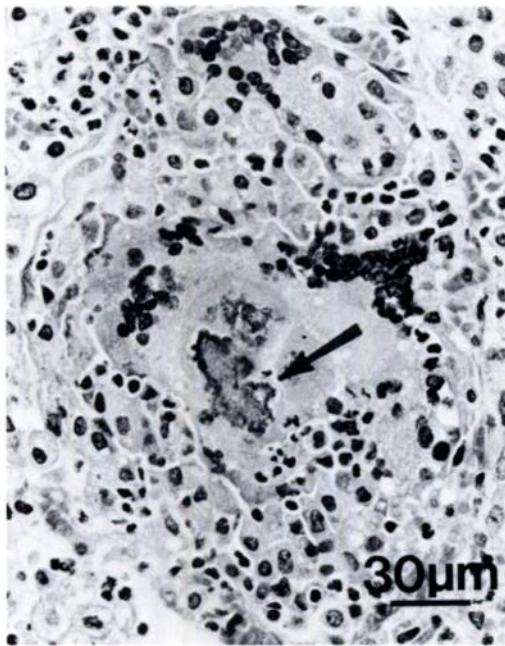


FIGURE 2. A cluster of organisms, *Staphylococcus epidermidis*, associated with pyogranulomatous inflammation in a koala. H&E.

case. Large numbers of lytic polymorphs and many Gram-positive cocci were seen in a Gram stain of lesion material. Sheep blood agar plates were inoculated and incubated aerobically at 37 C. *Staphylococcus epidermidis* (Kloos and Schleifer, 1986) was recovered in pure growth. Bacteriophage typing against a set of human phages was attempted, but the isolate was found to be non-typable.

Pneumonia due to *Nocardia asteroides* has not been described previously in the koala, but is well recognised in other species of domestic and wild mammals (Beaman and Sugar, 1983). The validity of reported diagnoses of nocardiosis in other marsupials (Tucker and Millar, 1953) is difficult to establish because of a lack of distinction between nocardiosis and actinomycosis in the early literature. It is possible that pulmonary infection in the first case was related to inhalation of organisms due to the presence of the nasal twig. However, this was not examined further. The finding of

chronic prostatitis, a condition commonly accompanying cystitis, suggests that the animal was already compromised. *Nocardia asteroides*, a soil saprophyte of world-wide distribution, is the most frequently isolated species from clinical specimens, although *Nocardia brasiliensis* and *Nocardia otitidiscaviarum* also have been implicated in disease (Lechevalier and Goodfellow, 1986). Infection in humans is often associated with immunocompromised patients (Stevens, 1983).

Staphylococcus epidermidis and other coagulase-negative staphylococci have previously been considered contaminants of clinical specimens in man. Recently, however, it has been recognised that these organisms may act as opportunistic pathogens in compromised individuals (Gemmel, 1983). Isolation of *S. epidermidis* in pure culture and its visible presence in phagocytes in lesions confirms its role as a pathogen in the second case. The infection was considered opportunistic as the koala was in poor condition and had been treated for several weeks for chronic cystitis, reportedly caused by *C. psittaci* (Brown and Grice, 1984). Attempted phage typing of the isolate suggested it was probably not of human origin.

Although respiratory disease contributed to the eventual demise of both koalas in this report, other diseases, reportedly caused by *Chlamydia psittaci*, probably contributed to debilitation. *Chlamydia psittaci* was initially thought to be acting as a primary pathogen but the finding of infected koalas without clinical expression of disease (Weigler et al., 1988), has implied its role to be more of an opportunistic pathogen. Underlying factors were probably responsible for increased susceptibility to opportunistic infections. The habitat of the koala along the coastal region of northern New South Wales is particularly threatened by urbanization and land clearing for farming (Canfield, 1987b). Deaths due to motor vehicles, attack by carnivores and contact with poisonous chemicals are combining with overcrowding and lack of

food trees to make fragile the survival of the koala in that region (Canfield, 1987b). Habitat management is essential to successful control of disease, especially that associated with opportunistic pathogens.

We thank the Koala Preservation Society of New South Wales for providing field assistance. Histological assistance was provided by Beverley Horsburgh, Karen Wadwell and Roslyn Walker. Identification of the *Nocardia asteroides* was conducted by David Dawson and Jim Psaltis from the State Health Laboratory (Tuberculosis Section), Brisbane. Confirmation of the *S. epidermidis* identification and attempted phage typing was performed by Candace Gabelish, Department of Infectious Diseases, University of Sydney. We also thank Daria Love for her assistance and advice regarding the isolation and identification of the organisms and Karen Wadwell for photography. This study was supported by grants from the Australian National Parks & Wildlife Service and the Sun Herald Koala Appeal Fund.

LITERATURE CITED

- BACKHOUSE, T. C., AND A. BOLLIGER. 1960. Cryptococcosis in the koala. *Australian Journal of Science* 23: 86-87.
- BEAMAN, B. L., AND A. M. SUGAR. 1983. *Nocardia* in naturally acquired and experimental infections in animals. *The Journal of Hygiene* 91: 393-419.
- BROWN, A. S., AND R. G. GRICE. 1984. Isolation of *Chlamydia psittaci* from koalas (*Phascolarctos cinereus*). *Australian Veterinary Journal* 61: 413.
- CANFIELD, P. J. 1987a. A mortality survey of free range koalas from the North Coast of New South Wales. *Australian Veterinary Journal* 64: 325-328.
- . 1987b. A study of koala deaths. *Australian Science Magazine* 4: 24-25.
- , C. J. OXENFORD, G. R. LOMAS, AND R. K. DICKENS. 1986. A disease outbreak involving pneumonia in captive koalas. *Australian Veterinary Journal* 63: 312-313.
- CULLING, C. F. A., R. T. ALLISON, AND W. T. BARR. 1985. *In Cellular pathology technique*, 4th ed. Butterworth & Co. Ltd., London, England, 334 pp.
- DICKENS, R. K. 1975. The koala *Phascolarctos cinereus*, past, present and future. *Australian Veterinary Journal* 51: 459-463.
- FRANCIS, J. 1963. Susceptibility of *Corynebacterium equi* to streptomycin and treatment of pneumonia in koala bears. *Veterinary Record* 75: 642.
- GEMMEL, C. G. 1983. Extracellular toxins and enzymes of coagulase-negative staphylococci. *In Staphylococci and staphylococcal infections*, Vol. 2. The organism *in vivo* and *in vitro*, C. S. F. Easmon and C. Adlam (eds.). Academic Press, London, England, pp. 809-827.
- KLOOS, W. E., AND K. H. SCHLEIFER. 1986. *Staphylococcus epidermidis*. *In Bergey's manual of systematic bacteriology*, Vol. 2, J. G. Holt (ed.). Williams & Wilkins Co., Baltimore, Maryland, pp. 1019-1022.
- LECHEVALIER, M. P., AND M. GOODFELLOW. 1986. Genus *Nocardia*. *In Bergey's manual of systematic bacteriology*, Vol. 2, J. G. Holt (ed.). Williams & Wilkins Co., Baltimore, Maryland, pp. 1459-1471.
- MCKENZIE, R. A. 1981. Observations and diseases of free living and captive koalas *Phascolarctos cinereus*. *Australian Veterinary Journal* 57: 243-246.
- MCKENZIE, R. A., A. D. WOOD, AND P. J. BLACKALL. 1979. Pneumonia associated with *Bordetella bronchiseptica* in koalas. *Australian Veterinary Journal* 55: 427-430.
- MORIST, S., I. V. JERRETT, M. ANDERSON, AND J. HAYMAN. 1985. Cutaneous and respiratory tract infection with *Mycobacterium ulcerans* in two koalas (*Phascolarctos cinereus*). *Journal of Wildlife Diseases* 21: 171-173.
- MISHRA, S. K., R. E. GORDON, AND D. A. BARNETT. 1980. Identification of nocardiae & streptomycetes of medical importance. *Journal of Clinical Microbiology* 11: 728-736.
- OGAWA, T., AND K. MOTOMURA. 1970. Studies on murine leprosy bacillus. 1. Attempt to cultivate *in vitro* the Hawaiian strain of *Mycobacterium lepraemurium*. *Kitasato Archives of Experimental Medicine* 43: 21-36.
- OXENFORD, C. J., P. J. CANFIELD, AND R. K. DICKENS. 1986. Cholecystitis and bronchopneumonia associated with *Pseudomonas aeruginosa* in a koala. *Australian Veterinary Journal* 63: 338-339.
- PUTT, F. A. 1951. A modified Ziehl-Neelsen stain for demonstration of leprosy bacilli and other acid-fast organisms. *American Journal of Clinical Pathology* 21: 92-95.
- RAHMAN, A. 1957. The sensitivity of various bacteria to chemotherapeutic agents. *British Veterinary Journal* 113: 175-188.
- RUSSELL, E. G., AND E. F. STRAUBE. 1979. Streptobacillary pleuritis in a koala (*Phascolarctos cinereus*). *Journal of Wildlife Diseases* 15: 391-394.
- STEVENS, D. A. 1983. Clinical and clinical labora-

- tory aspects of nocardial infection. The Journal of Hygiene 91: 377-384.
- TUCKER, R., AND R. MILLAR. 1953. Outbreak of nocardiosis in marsupials in the Brisbane Botanical Gardens. Journal of Comparative Pathology 63: 143-146.
- WEIGLER, B. J., A. A. GIRJES, N. A. WHITE, N. D. KUNST, F. N. CARRICK, AND M. F. LAVIN. 1988. Aspects of the epidemiology of *Chlamydia psittaci* infection in a population of koalas (*Phascolarctos cinereus*) in Southeastern Queensland, Australia. Journal of Wildlife Diseases 24: 282-291.
- Received for publication 24 January 1989.