

Pleural Mesothelioma in a European Spotted Fallow Deer (Cervus dama)

Authors: Byerly, Charles S., Wilson, Ronald B., and Holscheiy, Myron A.

Source: Journal of Wildlife Diseases, 25(4) : 597-598

Published By: Wildlife Disease Association

URL: <https://doi.org/10.7589/0090-3558-25.4.597>

BioOne Complete (complete.BioOne.org) is a full-text database of 200 subscribed and open-access titles in the biological, ecological, and environmental sciences published by nonprofit societies, associations, museums, institutions, and presses.

Your use of this PDF, the BioOne Complete website, and all posted and associated content indicates your acceptance of BioOne's Terms of Use, available at www.bioone.org/terms-of-use.

Usage of BioOne Complete content is strictly limited to personal, educational, and non - commercial use. Commercial inquiries or rights and permissions requests should be directed to the individual publisher as copyright holder.

BioOne sees sustainable scholarly publishing as an inherently collaborative enterprise connecting authors, nonprofit publishers, academic institutions, research libraries, and research funders in the common goal of maximizing access to critical research.

Pleural Mesothelioma in a European Spotted Fallow Deer (*Cervus dama*)

Charles S. Byerly,¹ Ronald B. Wilson,¹ and Myron A. Holscher,² ¹Kord Animal Disease Laboratory, Nashville, Tennessee 37204, USA; ²Department of Pathology, Vanderbilt Medical Center, Nashville, Tennessee 37232, USA

ABSTRACT: An adult, captive European spotted fallow deer (*Cervus dama*) was submitted for necropsy due to sudden death. Gross lesions consisted of serosanguinous fluid in the thoracic cavity with multiple, often confluent, nodules covering visceral and parietal pleura. Microscopic examination revealed tubular structures lined by cuboidal cells covering a delicate fibrous stroma. Gross and microscopic morphology was consistent with a mesothelioma.

Key words: European spotted fallow deer, *Cervus dama*, pleura, mesothelioma, case history.

A 5-yr-old female fallow deer (*Cervus dama*) from the Opryland petting zoo (Opryland USA, Nashville, Tennessee 37214, USA) was found dead. The herd from which this deer came had been observed several times each day; there were no clinical signs seen prior to her death.

Necropsy revealed approximately 4 liters of serosanguinous fluid in the thoracic cavity. Several ribs had been fractured, probably by trauma, and were partially healed with a large callus surrounding each fracture. The pleura of the thoracic cavity, diaphragm, lung and pericardium contained numerous yellow-white, broad-based, firm tumors (Fig. 1). They were sometimes single but more often confluent and ranged in size from 1 to 4 cm in diameter. The nodules sometimes protruded as much as 3 cm into the thoracic cavity. The visceral and parietal pleura were extensively involved, yet the tumor did not infiltrate subjacent tissues and was confined to the thoracic cavity.

Histopathologic examination of the neoplasms revealed cuboidal cells with small, pleomorphic, basophilic nuclei and moderate amounts of eosinophilic, often granular or vacuolated cytoplasm. These cells formed tubular structures, usually being a single cell in thickness, over a delicate to

moderate collagenized stroma (Fig. 2). In some areas, the tumor cells were loosely arranged while in other foci, double rows and clumps of cells with a few binucleate cells were seen. Mitotic figures were not found. The adjacent pleura was edematous and contained a few dilated lymphatic vessels and multifocal lymphocytic infiltrates. The subjacent pulmonary parenchyma was partially atelectatic as a result of the expansive growth of the overlying tumors. Neoplastic cells were not found in the regional lymph nodes or the broken

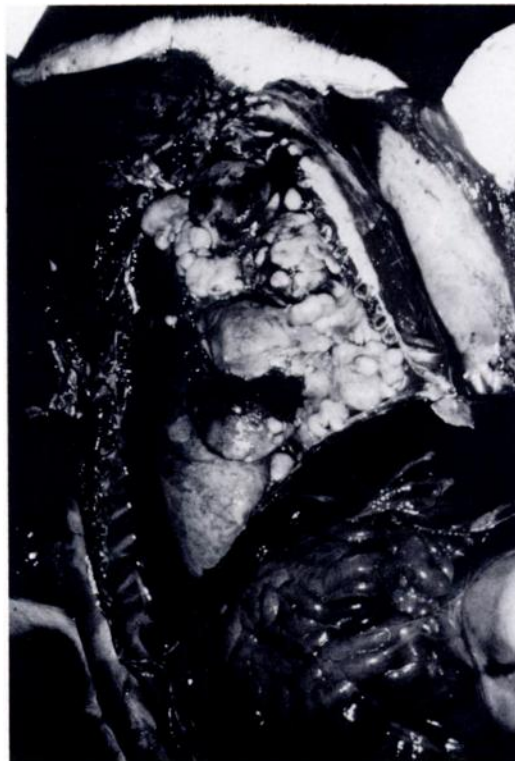

FIGURE 1. Light colored clusters of broad based tumors on the pleura of the thoracic cavity, diaphragm, lung and pericardium of a European fallow deer; fluid fills both cavities.

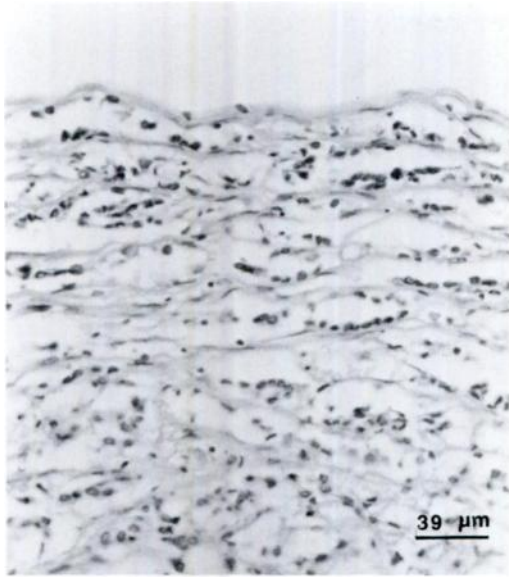


FIGURE 2. Section of a mesothelioma from a European fallow deer showing neoplastic cells which sometimes form tubular structures covering a delicate collagenous stroma. H&E.

ribs. Both gross and histopathologic evaluations were consistent with mesothelioma (Moulton, 1978). Representative tissue specimens from this case are deposited in the Registry of Comparative Pathology (Armed Forces Institute of Pathology, Washington, D.C. 20306, USA; accession number 2131042).

Mesotheliomas are tumors which spread on the mesothelial surfaces of pleural and peritoneal organs and cavity walls (Theilen and Madewell, 1987). They are rare in all species and considered malignant because of their tendency to implant and spread on the surface mesothelium of the affected body cavity (Moulton, 1978). They have been reported in humans, dogs, cats, cattle, chickens, pigs, horses, foxes, rats and rabbits (Nordstaga and Landsverk, 1981; Lichtensteiger and Leathers, 1987; Theilen and Madewell, 1987); we found no previous reports of these tumors in deer.

The cause of mesotheliomas is generally not known. Papillary epicardial mesothelioma in blue foxes was thought to have been caused by irritation of pleural sur-

faces by *Encephalitozoon cuniculi* (Nordstaga and Landsverk, 1981). In cattle, the animal species with the most reported cases, mesotheliomas occur in calves and are often congenital (Moulton, 1978). Asbestos has long been known to be one etiologic agent in humans (Theilen and Madewell, 1987). Calves from abattoirs in Wisconsin and Minnesota (USA) were found to have a significantly higher percentage of mesotheliomas than calves from other areas and asbestos fibers were found in the tissue of seven of 10 calves examined; asbestos is found in the bedrock of that geographic area (Croft, 1983). There also is a report of mesothelioma in a dog from an asbestos factory in London (Schuster, 1931). More recently, mesotheliomas in dogs have been found to be statistically related to exposure of their owners to asbestos (Glickman et al., 1988). There was no known exposure of this deer to asbestos nor were asbestos fibers or ferruginous bodies seen in the tissues by light microscopy in this case.

LITERATURE CITED

- CROFT, W. 1983. Environmental asbestos and mesotheliomas in dairy calves. *Proceedings of the American Association for Cancer Research* 24: 188.
- GLICKMAN, L. T., L. M. DOMANSKI, T. G. MAGUIRE, R. R. DUBIELIG, AND A. CHURG. 1983. Mesothelioma in pet dogs associated with exposure of their owners to asbestos. *Environmental Research* 32: 305-313.
- LICHENSTEIGER, C. A., AND C. W. LEATHERS. 1987. Peritoneal mesothelioma in a rabbit. *Veterinary Pathology* 24: 464-466.
- MOULTON, J. E. 1978. *Tumors in domestic animals*, 2nd ed. University of California Press, Berkeley, California, 465 pp.
- NORDSTAGA, K., AND T. LANDSVERK. 1981. Papillary epicardial mesotheliomas associated with encephalitozoonosis in blue foxes. *Veterinary Pathology* 18: 564-566.
- SCHUSTER, N. H. 1931. Pulmonary asbestosis in a dog. *Journal of Pathologic Bacteriology* 34: 751.
- THEILEN, G., AND B. R. MADEWELL. 1987. *Veterinary cancer medicine*, 2nd ed. Lea and Febiger, Philadelphia, Pennsylvania, 676 pp.

Received for publication 16 February 1989.