

## **Sarcocystis sp. in Muscles of Free-ranging Florida Panthers and Cougars (*Felis concolor*)**

Authors: Greiner, Ellis C., Roelke, Melody E., Atkinson, Carter T., Dubey, J. P., and Wright, Scott D.

Source: Journal of Wildlife Diseases, 25(4) : 623-628

Published By: Wildlife Disease Association

URL: <https://doi.org/10.7589/0090-3558-25.4.623>

---

BioOne Complete ([complete.BioOne.org](https://complete.BioOne.org)) is a full-text database of 200 subscribed and open-access titles in the biological, ecological, and environmental sciences published by nonprofit societies, associations, museums, institutions, and presses.

Your use of this PDF, the BioOne Complete website, and all posted and associated content indicates your acceptance of BioOne's Terms of Use, available at [www.bioone.org/terms-of-use](https://www.bioone.org/terms-of-use).

Usage of BioOne Complete content is strictly limited to personal, educational, and non - commercial use. Commercial inquiries or rights and permissions requests should be directed to the individual publisher as copyright holder.

---

BioOne sees sustainable scholarly publishing as an inherently collaborative enterprise connecting authors, nonprofit publishers, academic institutions, research libraries, and research funders in the common goal of maximizing access to critical research.

## Sarcocystis sp. in Muscles of Free-ranging Florida Panthers and Cougars (*Felis concolor*)

Ellis C. Greiner,<sup>1</sup> Melody E. Roelke,<sup>2</sup> Carter T. Atkinson,<sup>3</sup> J. P. Dubey,<sup>4</sup> and Scott D. Wright,<sup>1</sup> <sup>1</sup> Department of Infectious Diseases, College of Veterinary Medicine, University of Florida, Gainesville, Florida 32610, USA; <sup>2</sup> Florida Game and Fresh Water Fish Commission, 4005 South Main Street, Gainesville, Florida 32601, USA; <sup>3</sup> Institute of Pathology, Case Western Reserve University, Cleveland, Ohio 44106, USA; <sup>4</sup> Zoonotic Diseases Laboratory, Livestock and Poultry Sciences Institute, BARC East, ARS, USDA, Beltsville, Maryland 20705, USA

**ABSTRACT:** Sarcocysts of *Sarcocystis* sp. were found in the striated muscles from 11 of 14 wild Florida panthers (*Felis concolor coryi*) and four of four cougars (two wild *F. concolor stanleyana* and two captive *F. concolor* of undetermined subspecies). The common occurrence of sarcocysts in muscles of top carnivores such panthers and cougars is unexplained. This stage of the life cycle is normally confined to the muscles of the prey species. Because large felids are rarely preyed upon, it is unlikely that a species of *Sarcocystis* has evolved using large cats as intermediate hosts. Therefore, the presence of these sarcocysts might be an indication of immune compromise in these felids, enabling the atypical development of the sarcocysts.

**Key words:** *Sarcocystis*, sarcocysts, panthers, cougars, immunosuppression, muscle, *Felis concolor*, free-ranging, feline panleucopenia virus, feline immunodeficiency virus.

Members of the Felidae normally are definitive hosts for *Sarcocystis* spp. and typically support only the sexual phase of the parasite which results in the production of sporulated oocysts in intestinal enterocytes (Dubey et al., 1988). At least 11 species of *Sarcocystis* are known to utilize felids as definitive hosts as indicated by the production and release of sporocysts. Sporocysts of *Sarcocystis* spp. have been reported in the feces of two of 12 *Felis concolor* in Montana (Dubey, 1982).

Few reports of sarcocysts in the muscles of felids are known. Kluge (1967) reported sarcocysts in a captive cougar necropsied at a zoo in Washington, D.C. Sarcocysts were found in the heart muscle of two lions (*Panthera leo*) in a zoo in India (Bhatavdekar and Purohit, 1963), in striated and cardiac muscle from three domestic cats from the United States (Kirkpatrick et al., 1986), four domestic cats in Illinois (Everitt et al., 1987), two domestic cats in Georgia (Hill

et al., 1988) and one domestic cat from Texas (Edwards et al., 1988). Herein, we report *Sarcocystis* sp. in muscles of the endangered wild Florida panther (*Felis concolor coryi*), wild cougars (*Felis concolor stanleyana*) from Texas, and captive and captive/released cougars from Texas.

Because of the endangered status of the

TABLE 1. Presence of sarcocysts in the Florida panther and cougars.

Sex	Age (yr)	Location*	Sarcocysts
Florida panthers			
M	3–5	BCNP	— <sup>b</sup>
F	2–3	CMA	+
F	8–10	FS	+
M	12–14	FS	+
M	>12	FS	+
M	9–11	PR	+
M	1–2	FS	—
F	4–5	ENP	+
M	7–9	BI	+
F	8–10	FS	+
M	4–5	PR	+
M	3–4	FS	+
F	>14	FS <sup>c</sup>	+
F	12–14	FS	—
Cougars			
M	4–6	Western Texas	+
M	<1	Northern Florida <sup>d</sup>	+
M	2	Ocala, Florida <sup>e</sup>	+
F	3–5	Western Texas <sup>f</sup>	+

\* BCNP, Big Cypress National Preserve; CMA, Corbett Management Area; FS, Fakahatchee Strand; PR, private ranches adjacent to the BCNP; BI, Bear Island; ENP, Everglades National Park (all of previous sites are in southern Florida).

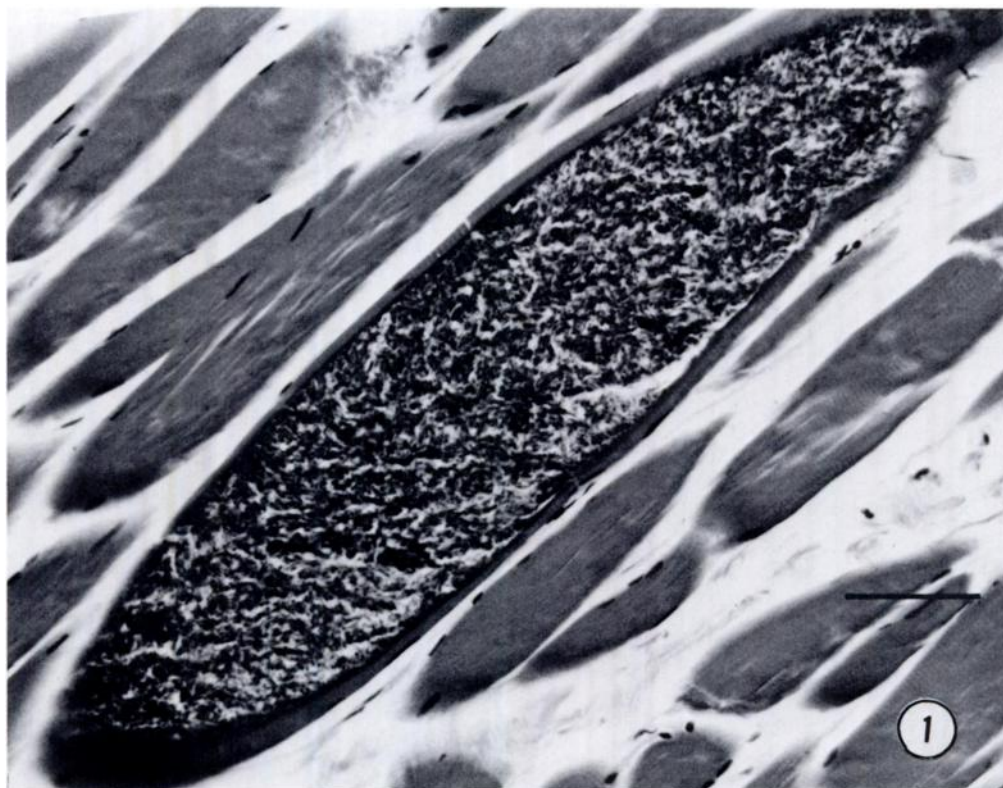
<sup>b</sup> —, absent; +, present.

<sup>c</sup> This individual had been a captive for 16 mo, and died in captivity.

<sup>d</sup> Raised in captivity until 8 mo of age, released and killed by car 2 mo later.

<sup>e</sup> Raised totally in captivity.

<sup>f</sup> This cougar was translocated to Florida and died 6 wk after being released.



FIGURES 1–5. Sarcocysts in muscles of Florida panthers.

FIGURE 1. Longitudinal section of sarcocyst from Florida panther. Bar = 100  $\mu$ m.

Florida panther, all recovered carcasses are necropsied. While six of these 14 panthers were road kills, others died of various causes including gunshot, intraspecific aggression, and disease. All Florida panthers originated in southern Florida. Routine tissues were collected including tongue, diaphragm, heart, masseter muscle and occasionally other muscles. These were fixed in 10% buffered formalin, sectioned at 4  $\mu$ m, and stained with hematoxylin and eosin. Tissues were collected also from a captive cougar that had been released illegally in Florida and was killed by a car, a cougar from western Texas that was killed during capture, another cougar from Texas that was fitted with a radio collar, sterilized and released into northern Florida before dying of unknown causes 6 wk later, and a private pet that died of complications following anesthesia. Formalin-fixed, paraffin-

embedded sarcocysts were located on the cut surface of two paraffin blocks under a dissecting microscope, trimmed from the blocks with a razor blade, and processed for transmission electron microscopy. The small blocks of tissue were deparaffinized with xylene, rehydrated through a descending series of concentrations of ethanol, and rinsed with 0.1 M phosphate buffer at pH 7.4. The tissue was fixed for 1 hr at 4 C with 1% osmium tetroxide in 0.1 M phosphate buffer, pH 7.4, washed with distilled water and stained en bloc for 1 hr with 1% uranyl acetate. The blocks were then dehydrated with ethanol and embedded in Spurr's epoxy resin (Polysciences Incorporated, Warrington, Pennsylvania 18976, USA). Ultrathin sections of four sarcocysts were cut with a diamond knife, mounted on nickel grids, and stained with 2% uranyl acetate in 50% methanol fol-

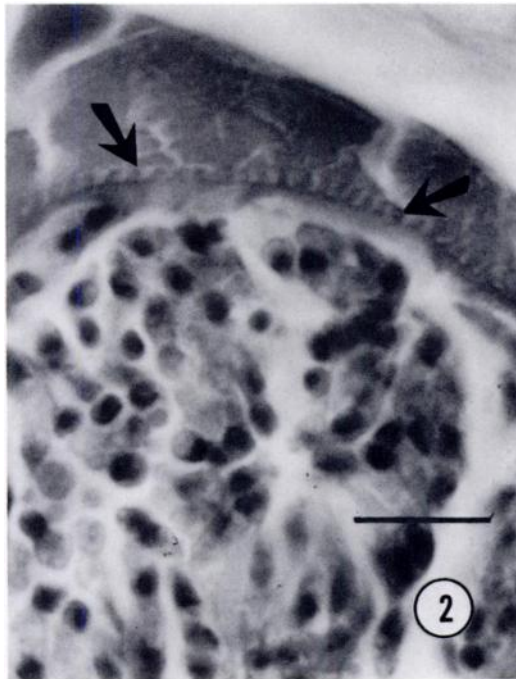


FIGURE 2. Sarcocyst wall showing equal length and evenly distributed fingerlike projections (arrows). Bar = 10  $\mu$ m.

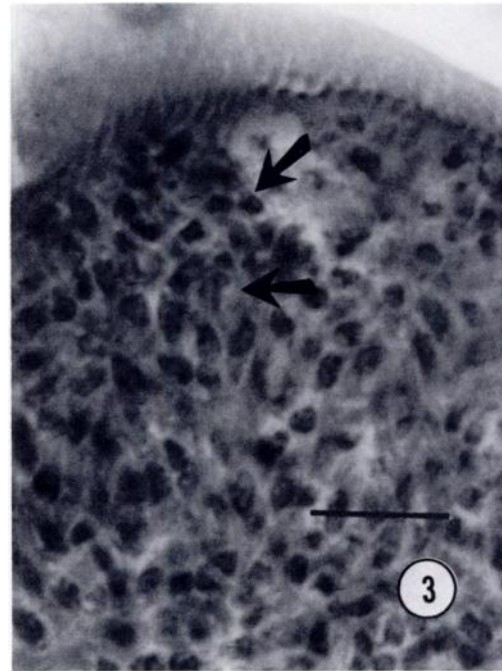


FIGURE 3. Sarcocyst showing septa (arrows). Bar = 10  $\mu$ m.

lowed by Reynolds' lead citrate (Reynolds, 1963). The sections were carbon coated with a vacuum evaporator and examined with a JEOL 100CX electron microscope (JEOL Ltd., Tokyo, Japan).

Eleven of 14 (78%) Florida panthers had sarcocysts in their muscles (Table 1). Six of those Florida panthers with sarcocysts were males and five were females. Seven of eight (88%) individuals >6-yr-old compared to four of six (67%) panthers <6-yr-old were infected with sarcocysts. The youngest Florida panther sampled was 1.5-yr-old and it was not infected (Table 1). All four cougars also contained sarcocysts in their muscles; these included the two captive individuals (Table 1).

Sarcocysts were observed most frequently in the muscles of the tongue; this was followed by skeletal muscles and then diaphragm. A single sarcocyst was observed in cardiac muscle of the captive cougar. Sarcocysts were up to 1 cm long in unstained muscle squash preparations.

In histologic sections, sarcocysts ranged in size up to 966  $\mu$ m  $\times$  28 to 93  $\mu$ m. Sarcocysts were completely filled with bradyzoites (Fig. 1). The sarcocyst wall contained fingerlike projections (evenly distributed and of equal length) protruding towards the myocytes (Fig. 2) and sarcocysts were septate (Fig. 3). Inflammatory cells were not observed surrounding any of the sarcocysts.

Electron microscopy demonstrated that the primary sarcocyst wall was folded into short, rounded, 1 by 0.5  $\mu$ m fingerlike villi (Figs. 4, 5). The primary sarcocyst wall consisted of a parasitophorous vacuole membrane (PVM) on the external surface that was underlain by a 60 to 80 nm thick, electron dense layer. This layer was modified into short, "hobnail"-like protrusions over the surface of the sarcocyst that were between or at the bases of the villi (Figs. 4, 5). The PVM on the external surface of villi was covered with a coarse surface coat composed of fibrillar material (Fig. 5). The ground substance of the sarcocyst was ap-

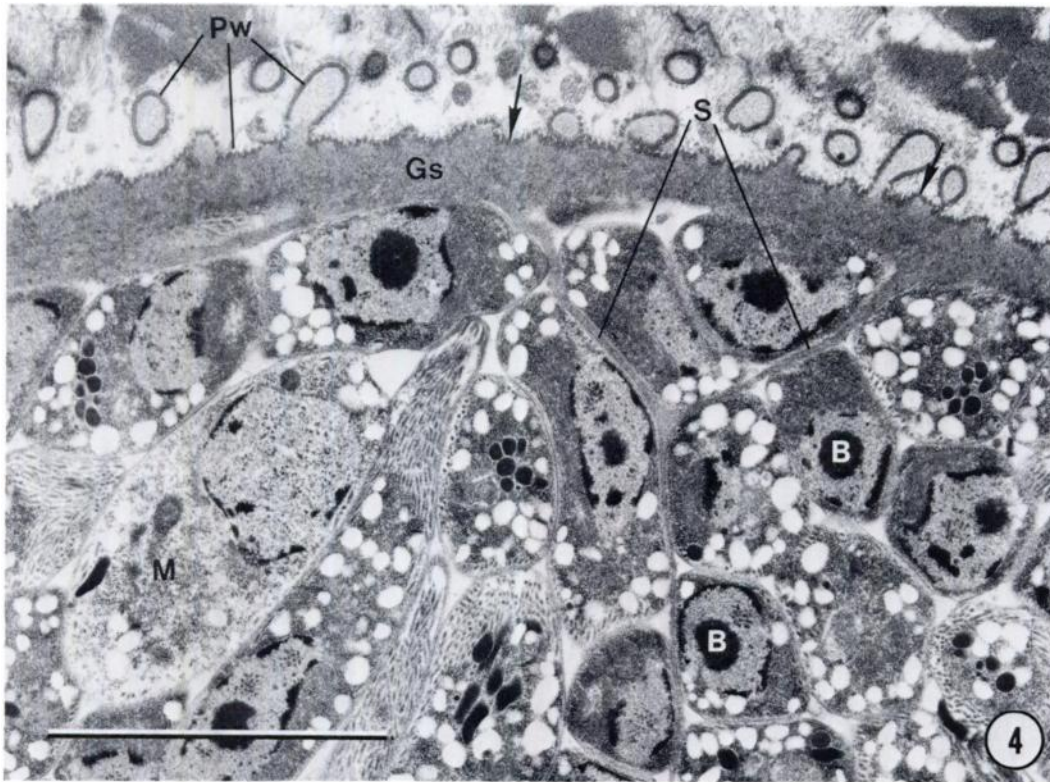


FIGURE 4. Primary sarcocyst wall (Pw) is folded into short, rounded villi. Note uneven "hobnailed" surface of the primary cyst wall (arrows) between villi. Septa (S) are continuous with the ground substance (Gs) of the wall. Numerous bradyzoites (B) and occasional metrocytes (M) were present. Bar = 5  $\mu$ m.

proximately 500 nm thick and composed of fine granules and fibrils. The sarcocyst villi contained similar granules and fibrils that were not as densely packed. Sarcocysts were divided internally by thin septa that were continuous with the ground substance of the cyst wall (Fig. 4).

Muscles (500 g) from a panther containing mature sarcocysts were fed to two laboratory reared 6-mo-old male domestic cats. These cats came from a feline colony at the Beltsville Agricultural Research Center (Beltsville, Maryland 20705, USA). They were fed only dry pelleted food and had never eaten uncooked meat. The feces of these cats were examined for *Sarcocystis* sp. sporocysts using a sugar flotation method (Dubey et al., 1988). On the thirteenth day postfeeding, the cats were euthanized and their intestinal mucosa was

scraped, digested in 5.25% sodium hypochlorite solution, washed and the sediment was examined for sporocysts as described elsewhere (Dubey et al., 1988). Sporocysts were not seen in feces or in intestinal digest.

The ultrastructure of the sarcocyst wall resembled type 9 (Dubey et al., 1988), but the granules and microtubules were not as prominent in the villi. The architecture of the sarcocyst wall in panthers was similar to that seen in some domestic cats (Everitt et al., 1987; Edwards et al., 1988; Hill et al., 1988), but contained more tightly packed villar projections than seen in those from other domestic cats (Kirkpatrick et al., 1986).

The mammalian prey items of Florida panthers include feral swine (*Sus scrofa*), white-tailed deer (*Odocoileus virgini-*

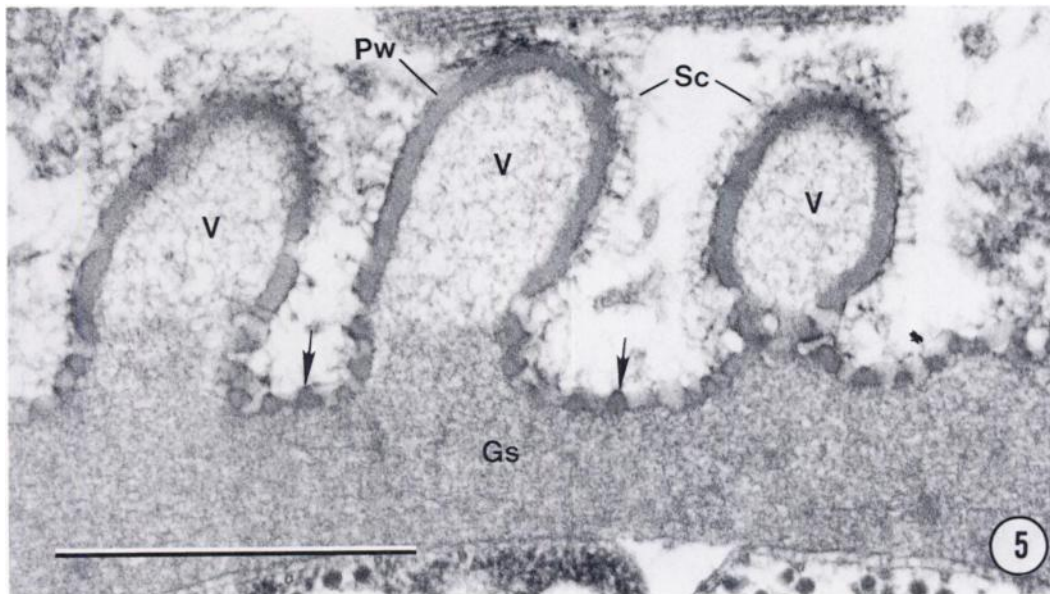


FIGURE 5. Higher magnification of the primary cyst wall (Pw). The wall is folded into short, rounded villi (V). Note thickened electron-dense layer of primary cyst wall which is modified into "hobnail"-like bumps (arrows) around the bases of the villi. The external surface of the primary cyst wall is covered with fibrillar surface coat (Sc). The ground substance (Gs) of the cyst wall consists of fine granules and fibrils. Bar = 1  $\mu$ m.

anus), raccoons (*Procyon lotor*), armadillos (*Dasypus novemcinctus*), marsh rabbits (*Sylvilagus palustris*), otters (*Lutra canadensis*), opossums (*Didelphis virginianus*), bobcats (*Lynx rufus*) and cotton rats (*Sigmodon hispidus*) (Roelke et al., 1986; Belden, 1987; O. Bass, pers. comm.). Panthers have also been documented to eat birds (unidentified species), alligators (*Alligator mississippiensis*) and snakes (unidentified species) (Roelke et al., 1986; Beldon, 1987; O. Bass, pers. comm.). Numerous cases of cannibalism have been documented in cougars in the western United States (Anderson, 1983) and two cases of cannibalism have been reported in Florida panthers (Roelke et al., 1986). Thus, if the sarcocysts in the panthers originated from sarcocysts in prey species, they probably came from one of these species, but there is no evidence that ingestion of sarcocysts directly give rise to sarcocysts. If the source of infection were sporocysts in feces, then the list of potential host species could be much wider.

Both the Florida panther and the cougar are top carnivores. Few species feed upon these felids. A possible exception in Florida would be the black bear (*Ursus americanus*) with panther kittens and juveniles the most vulnerable individuals to attack. Carrion feeders such as raccoons, foxes (*Vulpes fulva* and *Urocyon cinereoargenteus*), alligators, and vultures (*Cathartes aura*) might also play a role in this cycle. The presence of sarcocysts in these top carnivores is similar to finding this stage of *Sarcocystis* sp. in the human population because no other animals prey upon humans in a regular manner. Forty-six cases of sarcocysts have been reported from humans (Dubey et al., 1988).

It is possible that these infections resulted from immunological compromise as was suggested in some domestic cats (Kirkpatrick et al., 1986; Edwards et al., 1988; Hill et al., 1988). In support of an immune compromise hypothesis, it should be stated that the sera from 25 of 32 (78%) of Florida panthers examined contained antibodies to

feline panleucopenia virus (Roelke, 1988). This virus is known to cause an acute state of immunosuppression through the destruction of all components of the white blood series (Fenner et al., 1987). Although immune suppression caused by this virus would be short term, the possibility of being infected with *Sarcocystis* sp. during this time of immune suppression could result in the formation of these long lasting stages. Another virus that could have contributed to this problem is the recent finding of feline immunodeficiency virus in 6 of 20 (30%) panthers examined (M. E. Roelke, unpubl. data).

The species of *Sarcocystis* present in the Florida panther and the cougars in this study was not identified, nor was the species of *Sarcocystis* determined for other reports of sarcocysts in felids. Limited studies suggest that the domestic cat is unlikely to be the definitive host. Whether the presence of sarcocysts is a consequence of immune suppression remains to be determined.

We would like to thank J. K. Frenkel for advice, Michelle Wells for supplying the information on the sarcocyst in the heart of the captive cougar, and Linda F. Siedzik for technical assistance. Partial funding of this project was from the United States Fish and Wildlife Service through the Endangered Species Program. This paper is published as Florida Agricultural Experiment Station Journal Series No. 9635.

#### LITERATURE CITED

- ANDERSON, A. E. 1983. A critical review of literature on puma (*Felis concolor*). Special Report number 54, Colorado Division of Wildlife, Denver, Colorado, 91 pp.
- BELDEN, R. C. 1987. Florida panther recovery plan implementation—A 1983 progress report. In *Cats of the world: Biology, conservation and management*, S. D. Miller and D. D. Everett (eds.). Proceedings of the Second International Cat Symposium, Kingsville, Texas, pp. 159–172.
- BHATAVDEKAR, M. Y., AND B. L. PUROHIT. 1963. A record of sarcosporidiosis in lion. *Indian Veterinary Journal* 40: 44–45.
- DUBEY, J. P. 1982. *Sarcocystis* and other coccidia in foxes and other wild carnivores from Montana. *Journal of the American Veterinary Medical Association* 181: 1270–1271.
- , C. A. SPEER, AND R. FAYER. 1988. *Sarcocystosis of animals and man*. CRC Press, Boca Raton, Florida, 215 pp.
- EDWARDS, J. F., M. D. FICKEN, P. J. LUTTGEM, AND M. S. FREY. 1988. Disseminated sarcocystosis in a cat with lymphosarcoma. *Journal of the American Veterinary Medical Association* 193: 831–832.
- EVERITT, J. E., E. D. BASGALL, S. B. HOOSER, AND K. S. TODD, JR. 1987. *Sarcocystis* sp. in the striated muscle of domestic cats, *Felis catus*. *Proceedings of the Helminthological Society of Washington* 54: 279–281.
- FENNER, F., P. A. BACHMANN, E. P. J. GIBBS, F. A. MURPHY, M. J. STUDDERT, AND D. O. WHITE. 1987. *Veterinary virology*. Academic Press, Orlando, Florida, 660 pp.
- HILL, J. E., W. L. CHAPMAN, JR., AND A. K. PRESTWOOD. 1988. Intramuscular *Sarcocystis* sp. in two cats and a dog. *The Journal of Parasitology* 74: 724–727.
- KIRKPATRICK, C. E., J. P. DUBEY, M. H. GOLDSCHMIDT, J. E. SAIK, AND J. A. SCHMITZ. 1986. *Sarcocystis* sp. in muscles of domestic cats. *Veterinary Pathology* 23: 88–90.
- KLUGE, J. P. 1967. Trichinosis and sarcosporidiosis in a puma. *Bulletin of the Wildlife Disease Association* 3: 110–111.
- REYNOLDS, E. S. 1963. The use of lead nitrate at high pH as an electron opaque stain in electron microscopy. *Journal of Cell Biology* 17: 208.
- ROELKE, M. E. 1988. Florida panther recovery. Florida Panther Biomedical Investigation, Annual Performance Report, 1 July 1987 to 30 June 1988. Florida Game and Fresh Water Fish Commission, Gainesville, Florida, 47 pp.
- , E. R. JACOBSON, G. V. KOLLIAS, AND D. J. FORRESTER. 1986. Medical management and biomedical findings on the Florida panther, *Felis concolor coryi*, 1 July 1985 to 30 June 1986. Annual Performance Report. Florida Game and Fresh Water Fish Commission, Gainesville, Florida, 65 pp.

*Received for publication 16 January 1989.*