

Acute Disseminated Toxoplasmosis in a Red Fox (*Vulpes vulpes*)

Authors: Dubey, J. P., Hamir, A. N., and Rupprecht, C. E.

Source: Journal of Wildlife Diseases, 26(2) : 286-290

Published By: Wildlife Disease Association

URL: <https://doi.org/10.7589/0090-3558-26.2.286>

BioOne Complete (complete.BioOne.org) is a full-text database of 200 subscribed and open-access titles in the biological, ecological, and environmental sciences published by nonprofit societies, associations, museums, institutions, and presses.

Your use of this PDF, the BioOne Complete website, and all posted and associated content indicates your acceptance of BioOne's Terms of Use, available at www.bioone.org/terms-of-use.

Usage of BioOne Complete content is strictly limited to personal, educational, and non - commercial use. Commercial inquiries or rights and permissions requests should be directed to the individual publisher as copyright holder.

BioOne sees sustainable scholarly publishing as an inherently collaborative enterprise connecting authors, nonprofit publishers, academic institutions, research libraries, and research funders in the common goal of maximizing access to critical research.

Acute Disseminated Toxoplasmosis in a Red Fox (*Vulpes vulpes*)

J. P. Dubey,¹ A. N. Hamir,² and C. E. Rupprecht,³ ¹ Zoonotic Diseases Laboratory, Livestock and Poultry Sciences Institute, Agricultural Research Service, U.S. Department of Agriculture, Beltsville, Maryland 20705, USA; ² New Bolton Center School of Veterinary Medicine, University of Pennsylvania, Kenneth Square, Pennsylvania 19348, USA; ³ The Wistar Institute, Philadelphia, Pennsylvania 19104, USA

ABSTRACT: A red fox (*Vulpes vulpes*) with signs of neurological disease was captured in Fairmount Park, Philadelphia, Pennsylvania (USA). The animal died in captivity and was examined because of suspected rabies. The liver had pale foci up to 4 mm in diameter. Foci of necrosis were associated with *Toxoplasma gondii* tachyzoites in several organs including liver, lungs and adrenal glands. Rabies antigen and distemper virus inclusions were not detected. The diagnosis of acute disseminated toxoplasmosis was confirmed by immunohistochemical staining.

Key words: *Toxoplasma gondii*, red fox, *Vulpes vulpes*, hepatic necrosis, tachyzoites, acute disseminated toxoplasmosis, case report.

Toxoplasma gondii infection is common in many species of homoiothermic animals (Dubey and Beattie, 1988). Results of studies in natural (Lalla et al., 1967; Wawrzekiewicz and Uminski, 1961; Noviskaya, 1977) and experimental (Dubey, 1983) infections indicate that *T. gondii* infections in foxes (*Vulpes vulpes*) are generally subclinical. Occasionally, acute toxoplasmosis has been reported in red foxes (*Vulpes vulpes*) from Denmark (Møller, 1952) and the United States (Helmboldt and Jungherr, 1955; Møller and Nielsen, 1964; Reed and Turek, 1985). Toxoplasmosis in the latter cases was associated with concurrent canine distemper virus infection. Herein, we report a case of primary acute toxoplasmosis in a red fox without concurrent infection.

A female red fox kit was captured by hand by park employees without resistance in West Fairmount Park, Philadelphia, Pennsylvania (USA; 39°59'N, 75°12'W). The animal was incoordinated and appeared to be unaware of its surroundings. When placed in lateral recumbency, it started paddling movements and attempted to bite the handlers. The animal

died while being transported and was submitted for necropsy.

The carcass was in fair nutritional condition. Grossly, the liver had numerous, randomly scattered irregularly-sized pale foci up to 4 mm in diameter and observed throughout the organ (Fig. 1). Similar, but fewer and isolated, foci also were seen in the lungs.

Because the animal was collected in an area enzootic for rabies and had signs of neurologic disease, brain tissue was submitted for fluorescent antibody testing (FAT) for the detection of rabies antigen (Goldwasser and Kissling, 1959). Heart blood for serology was collected at the time of necropsy. Tissue from the heart, skin, liver, lungs, kidneys, adrenals, pancreas, spleen, stomach, intestines, lymph nodes, urinary bladder, tongue, masseter muscles and brain were fixed in 10% buffered formalin. Paraffin sections were cut at 6 μ m and stained with hematoxylin and eosin for examination by light microscopy. Selected tissue sections also were stained by Giemsa and periodic acid-Schiff (PAS) stains and with anti-*T. gondii* and anti-*Neospora caninum* rabbit serum (Lindsay and Dubey, 1989). The serum sample was assayed for *T. gondii* antibodies with the agglutination test using whole formalin-fixed and acetone-fixed tachyzoites (Dubey and Thulliez, 1989).

Microscopic lesions were seen in the heart, lung, liver, tongue, pancreas, adrenal glands, skin and the brain. The most severe lesions were present in the liver where there were numerous, randomly scattered, multifocal to coalescing foci of necrosis. Within the necrotic areas there was variable amounts of hemorrhage, ex-

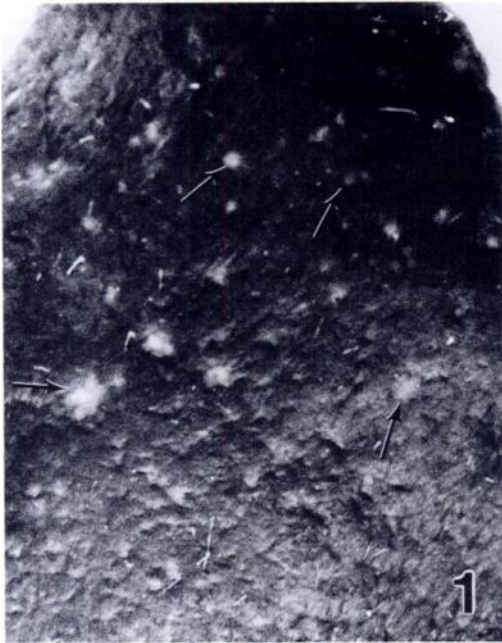

FIGURE 1. Foci of necrosis (arrows) resulting from toxoplasmosis in the liver of a red fox.

tensive nuclear debris and some mononuclear cells (predominately histiocytes). Individual and clusters of *T. gondii* tachyzoites (Fig. 2) were seen in the hepatocytes, macrophages or were free in the sinusoids. Organisms also often were seen either at the periphery of the lesions or in the unaffected areas of the tissue. These organisms were not associated with the inflammatory reaction. In the striated muscles (heart and tongue), lungs, pancreas and the adrenal glands a few isolated foci of necrosis and variable numbers of tachyzoites were seen (Figs. 3–5). Necrosis was minimal in the striated muscles, but there was a marked inflammatory response consisting predominantly of histiocytes. Two roughly circular areas of acute necrosis were seen in the adipose tissue of the subcutis. These appeared like thrombosed blood vessels and contained extensive cel-

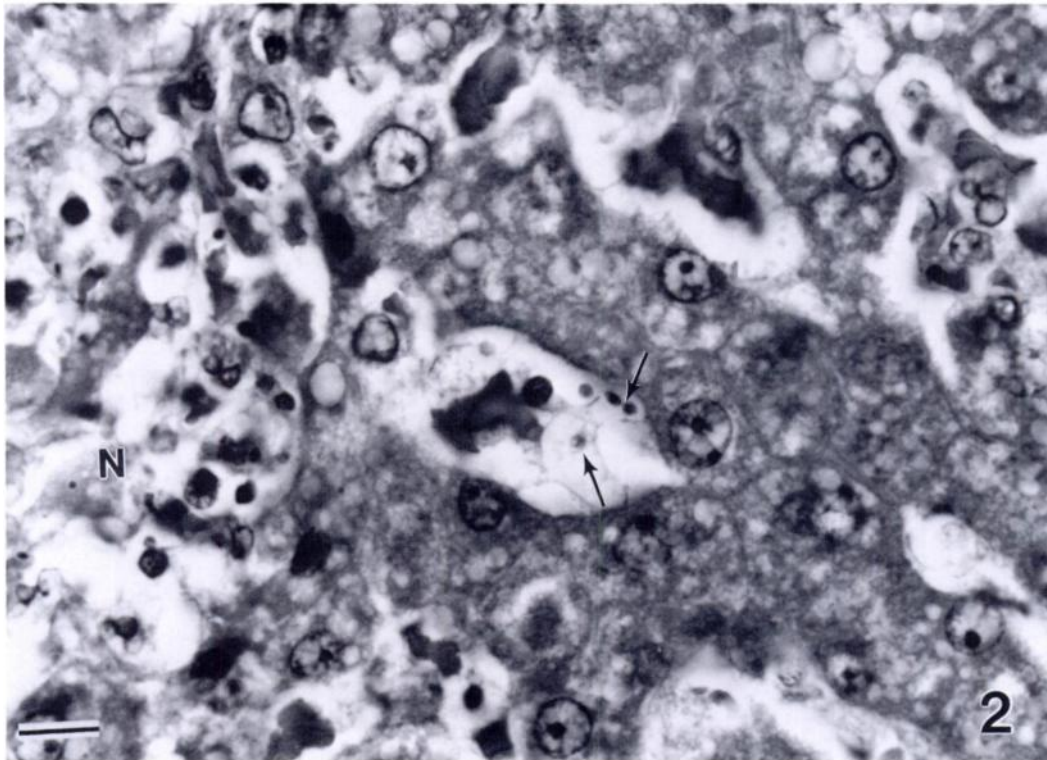


FIGURE 2. Necrosis (N) of hepatocytes and individual tachyzoites (arrows) of *T. gondii* in liver of a red fox. H&E. Bar = 10 μ m.

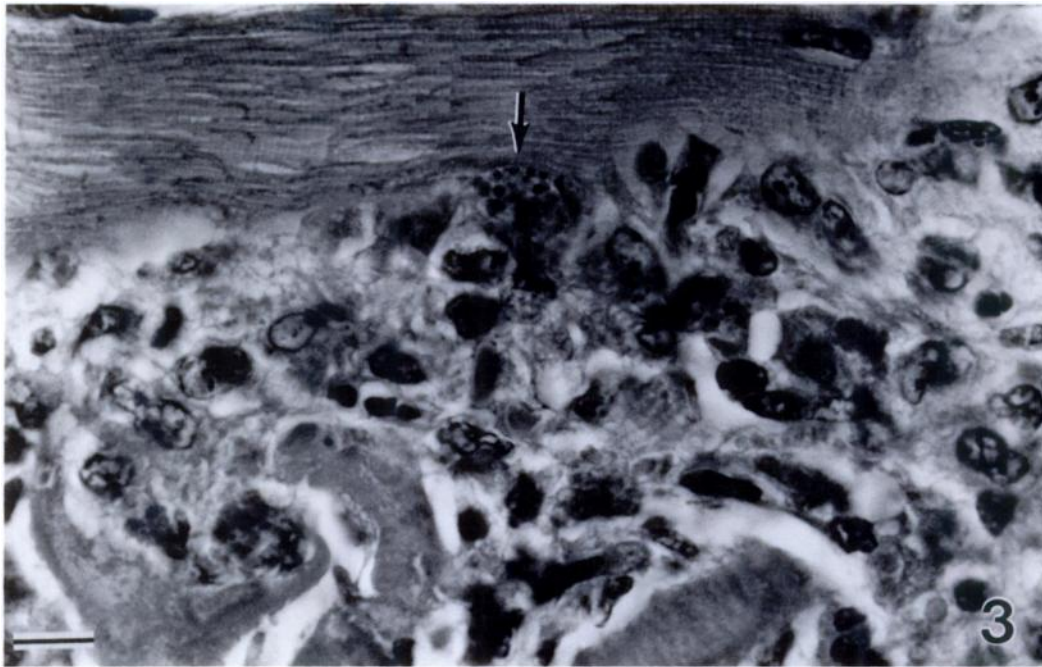


FIGURE 3. Mononuclear cell infiltration in tongue of a red fox with toxoplasmosis. Tachyzoites (arrow) are present at the periphery of the lesion. H&E. Bar = 10 μ m.

lular debris. A few tachyzoites were seen along the periphery of the lesions. In the cerebrum, cerebellum and the brainstem there were randomly distributed areas of glial nodules; however, protozoa were not seen in any of the brain sections.

Tachyzoites in lungs, liver, tongue and adrenal glands were stained positively with anti-*T. gondii* serum but not *N. caninum* serum. *Toxoplasma gondii* antibodies were detected in 1:8 and 1:4 dilutions of the fox serum using formalin-fixed and acetone-fixed tachyzoites, respectively. Viral inclusions or bacteria were not seen in any of the tissues. Rabies antigen was not detected in the brain. Lesions associated with distemper virus infection were not seen (Jubb et al., 1985).

This case of acute toxoplasmosis in the red fox is unusual because the clinical signs simulated rabies and there was no evidence of canine distemper virus infection and rabies. Møller and Nielsen (1964), Reed and Turek (1985) and Helmboldt and Jungherr (1955) reported similar cases in

red foxes from the United States and Møller (1952) described a similar disease in silver foxes (*Vulpes vulpes*); however, in all these cases there was concurrent canine distemper virus infection.

The present case was diagnosed as primary acute toxoplasmosis based on a finding of extensive necrosis in association with tachyzoites and/or absence of tissue cysts and other concurrent infections. The etiologic diagnosis was confirmed by immunohistochemical staining. The low *T. gondii* antibody titers in the serum of fox is unusual and might be related to the acute stage of infection. The fox might have been recently infected, or antibody synthesis might have been delayed. The immunohistochemical reaction ruled out infection of *Neospora caninum*, a recently recognized protozoan parasite of dogs misdiagnosed as *T. gondii* (Dubey and Beattie, 1988).

This study was supported in part by a grant from the Commonwealth of Pennsylvania Department of Agriculture.

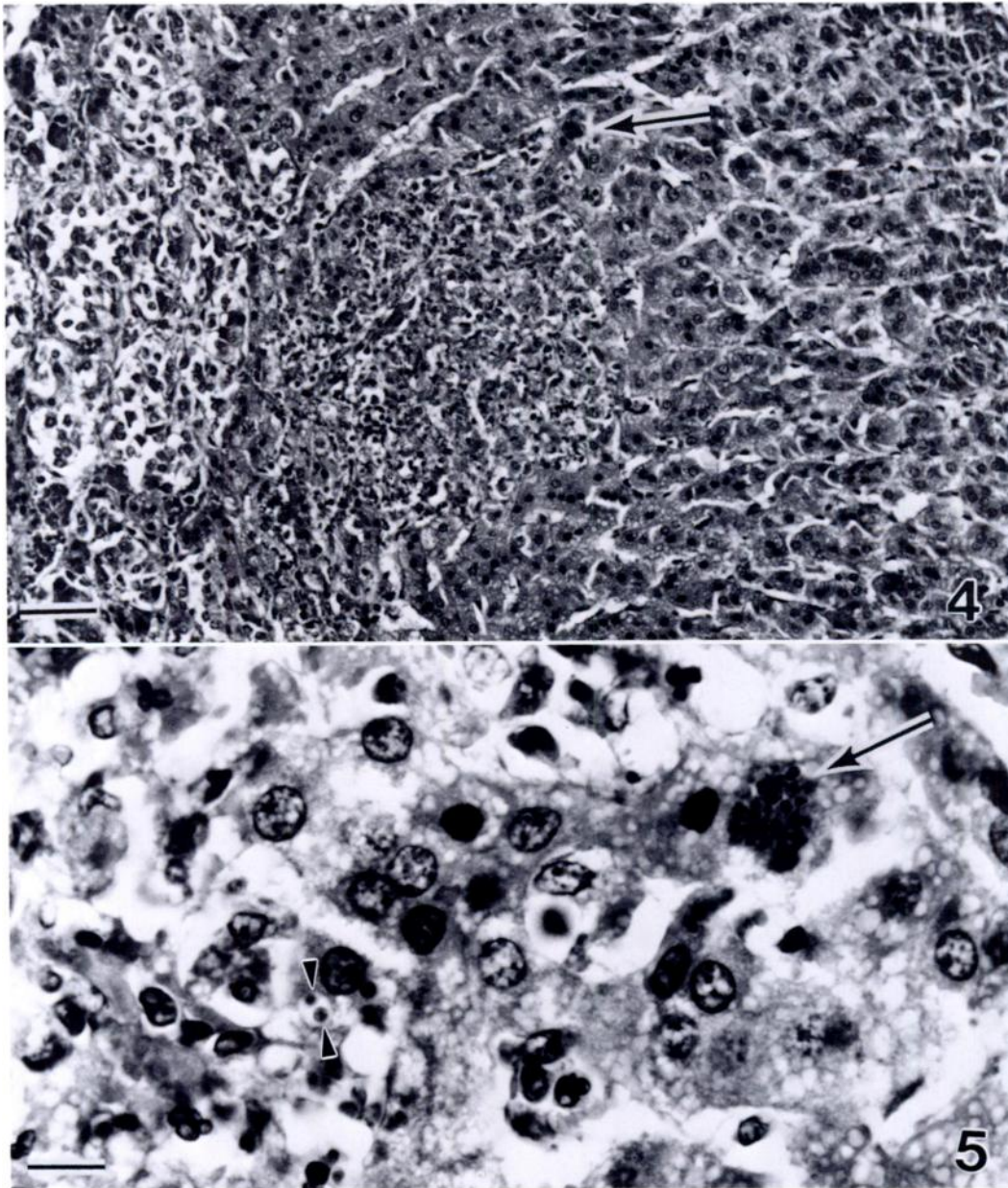


FIGURE 4. Focus of necrosis in adrenal cortex of a red fox with toxoplasmosis. Tachyzoites (arrow) are not visible at this magnification. H&E. Bar = 50 μ m.

FIGURE 5. Higher magnification of the tachyzoites from adrenal cortex of a red fox with toxoplasmosis arrowed in Figure 4. A large (arrow) and a small group (arrowhead) of tachyzoites are present. H&E. Bar = 10 μ m.

LITERATURE CITED

- DUBEY, J. P. 1983. Experimental infections of *Sarcocystis cruzi*, *Sarcocystis tenella*, *Sarcocystis capracanis* and *Toxoplasma gondii* in red foxes (*Vulpes vulpes*). *Journal of Wildlife Diseases* 19: 200-203.
- , AND C. P. BEATTIE. 1988. *Toxoplasmosis of animals and man*. CRC Press, Boca Raton, Florida, 220 pp.

- , AND P. THULLIEZ. 1989. Serologic diagnosis of toxoplasmosis in cats fed tissue cysts. *Journal of American Veterinary Medical Association* 194: 1297-1299.
- GOLDWASSER, R. A., AND R. E. KISSLING. 1959. Fluorescent antibody staining of street and fixed rabies virus antigen. *Proceedings of the Society for Experimental Biology and Medicine* 98: 219-223.
- HELMBOLDT, C. F., AND E. L. JUNGHER. 1955. Distemper complex in wild carnivores simulating rabies. *American Journal of Veterinary Research* 16: 463-469.
- JUBB, K. V. F., P. C. KENNEDY, AND N. PALMER. 1985. *Pathology of domestic animals*, Vol. 2, 3rd ed. Academic Press, New York, pp. 476-481.
- LALLA, F. DE, G. BECHELLI, AND L. CAVALLINI SAMPIERI. 1967. Osservazioni sierologiche e parassitologiche sulla diffusione della toxoplasmosi nelle volpi dell'area di Siena. *La Clinica Veterinaria* 90: 393-400.
- LINDSAY, D. S., AND J. P. DUBEY. 1989. Immunohistochemical diagnosis of *Neospora caninum* in tissue sections. *American Journal of Veterinary Research* 50: In press.
- MØLLER, T. 1952. Toxoplasmosis *Vulpes vulpes* (fox toxoplasmosis). *Acta Pathologica Microbiologica Scandinavia Supplement* 93: 308-320.
- , AND S. W. NIELSEN. 1964. Toxoplasmosis in distemper-susceptible carnivora. *Pathologica Veterinaria* 1: 189-203.
- NOVISKAYA, V. F. 1977. Toxoplasmosis of silver-black and Arctic foxes. *Biulletin Vsesoiuznyi Institut eksperimental' Noi, Veterinarii* 31: 61-62. [In Russian.]
- REED, W. M., AND J. J. TUREK. 1985. Concurrent distemper and disseminated toxoplasmosis in a red fox. *Journal of the American Veterinary Medical Association* 187: 1264-1265.
- WAWRZKIEWICZ, J., AND J. UMIŃSKI. 1961. Badania lisow hodowlanych w kierunku toksoplazmozy. *Wiadomości Parazytologiczne* 7: 407-409.

Received for publication 17 July 1989.