



Osteoporosis and Cranial Asymmetry in a Mountain Sheep (*Ovis canadensis*)

Authors: Bleich, Vernon C., Stahmann, Julia G., Bowyer, R. Terry, and Blake, John E.

Source: Journal of Wildlife Diseases, 26(3) : 372-376

Published By: Wildlife Disease Association

URL: <https://doi.org/10.7589/0090-3558-26.3.372>

BioOne Complete (complete.BioOne.org) is a full-text database of 200 subscribed and open-access titles in the biological, ecological, and environmental sciences published by nonprofit societies, associations, museums, institutions, and presses.

Your use of this PDF, the BioOne Complete website, and all posted and associated content indicates your acceptance of BioOne's Terms of Use, available at www.bioone.org/terms-of-use.

Usage of BioOne Complete content is strictly limited to personal, educational, and non - commercial use. Commercial inquiries or rights and permissions requests should be directed to the individual publisher as copyright holder.

BioOne sees sustainable scholarly publishing as an inherently collaborative enterprise connecting authors, nonprofit publishers, academic institutions, research libraries, and research funders in the common goal of maximizing access to critical research.

SHORT COMMUNICATIONS

Journal of Wildlife Diseases, 26(3), 1990, pp. 372-376
© Wildlife Disease Association 1990

Osteoporosis and Cranial Asymmetry in a Mountain Sheep (*Ovis canadensis*)

Vernon C. Bleich,^{1,2} Julia G. Stahmann,¹ R. Terry Bowyer,¹ and John E. Blake,¹ ¹ Institute of Arctic Biology, and Department of Biology and Wildlife, University of Alaska Fairbanks, Fairbanks, Alaska 99775, USA; ² California Department of Fish and Game, 407 W. Line St., Bishop, California 93514, USA

ABSTRACT: The skull of a mountain sheep (*Ovis canadensis cremnobates*) exhibiting osteoporosis was recovered from San Diego County, California. This specimen also exhibited lateral asymmetry of the cranium and rostrum, malocclusion of molars, and mandibular asymmetry. Investigators are cautioned about potentially confusing lesions associated with chronic frontal sinusitis with lesions of osteoporosis in mountain sheep. To our knowledge this is the first report of osteoporosis in this species.

Key words: Osteoporosis, asymmetry, mountain sheep, *Ovis canadensis*, malocclusion, case report.

Osteomyelitis of cranial bones occurs frequently among mountain sheep (*Ovis canadensis*) and often is linked to a condition termed "chronic sinusitis" (Bunch and Allen, 1981). Indeed, 20% of 630 skulls of mountain sheep exhibited anomalies associated with pyogenic osteomyelitis (Bunch and Allen, 1981). Such conditions have been associated with secondary bacterial infections resulting from aberrant migrations of nasal bot fly larvae (*Oestrus ovis*) (Paul and Bunch, 1978; Bunch et al., 1978). Turner (1982), however, cautioned against hastily drawn conclusions regarding the etiologies of these lesions. Others (Allred and Bradley, 1965, 1966; Allred et al., 1966; Turner, 1982) also described cranial lesions, as well as various dental anomalies for this species (Cowan, 1940; Benson, 1943; Dalquest and Hoffmeister, 1948; Kiger, 1963; Bradley and Allred, 1966).

On 31 May 1986, we obtained the skull of a mature male mountain sheep (*O. canadensis cremnobates*) from the Vallecito Mountains (San Diego County, California,

USA; 32°20'N, 117°15'W), a geographic area harboring a relatively small population of that subspecies (Russi, 1978). The animal was 4 to 5 yr old as determined by horn annuli (Geist, 1966), and had been dead approximately 1 wk. Advanced autolysis precluded an adequate post mortem examination and made it undesirable to salvage material other than the skull. Horns of this animal were extremely reduced in size relative to those of a normal male; estimated horn volume was <50% of normal.

The cleaned skull, excluding horn sheaths and mandible, weighed 665 g; a skull from a normal male animal of the same age weighed 1,480 g. The lighter skull was characterized by a generalized porosity of bone and a lateral deviation of the rostrum (Fig. 1). Multiple areas showed thinning, pitting and absence of compact bone that exposed the underlying cancellous bone; trabeculae appeared thin and were reduced in number. These areas included the alveolar process of the maxilla, a small area just rostral to the infraorbital foramen, the lacrimal bullae, tympanic bullae, right mastoid process, vomer, body of the basisphenoid, alveolar margin of the palatine process of the maxilla, and the left condyloid fossa and hypoglossal canal. The left hypoglossal canal measured 10 × 4 mm, whereas the right canal measured 5 × 2 mm. Trabeculae were particularly evident on the maxillary tuber where they were reduced to a delicate filigree of bone.

Trabeculae also were apparent on the

mandible, especially on the ventral margin of the incisive part, and alveolar borders of the molar part. On the left ramus of the mandible, alveolar bone had receded approximately 2 cm on the lateral side, almost to the level of the tooth roots; there was little lateral support to cheek teeth M2 and M3. A 2 to 3 mm lateral expansion of bone occurred on the left ramus of the mandible in the area of P3.

An area of lytic bone overlaid the dorsal nasal meatus on the caudal portion of the right nasal bone. Small pitted depressions and numerous trabeculae were visible surrounding a triangular lesion measuring 1.5×0.4 cm. A protuberance from the skull of 3 to 4 mm occurred alongside the lesion at the junction of the right nasal, frontal and maxillary bones.

The skull showed marked asymmetry and left lateral deviation of the rostrum (Fig. 1). This deviation, as measured from the median palatine suture to the midline of the basilar part of the occipital, was approximately 10 degrees, with maximum curvature occurring at the level of the basisphenoid. A marked asymmetry of the occlusal surfaces of the occipital and temporo-mandibular joints was present. On the occipital, distances between the intercondyloid notch and tip of the jugular process were 4 cm on the right and 2.4 cm on the left. The left ramus of the mandible was 0.6 cm shorter than the right, but the occlusal surface of the condylar process was 0.4 cm longer on the right. Asymmetry of the maxilla and mandible resulted in irregularities in dental occlusion for right molars and premolars: little wear of buccal edges of upper cheek teeth and lingual edges of lower cheek teeth resulted in sharp points and elongated tooth lengths (Fig. 1).

Radiographs of this abnormal skull and the skull of a normal male (Fig. 2) were made on 35×43 cm sheets of Kodak General Purpose Ultra Blue 50® (Eastman Kodak Co., Rochester, New York 14650, USA) film using a Dupont Cronex® (DuPont, Burbank, California 91505, USA) intensi-

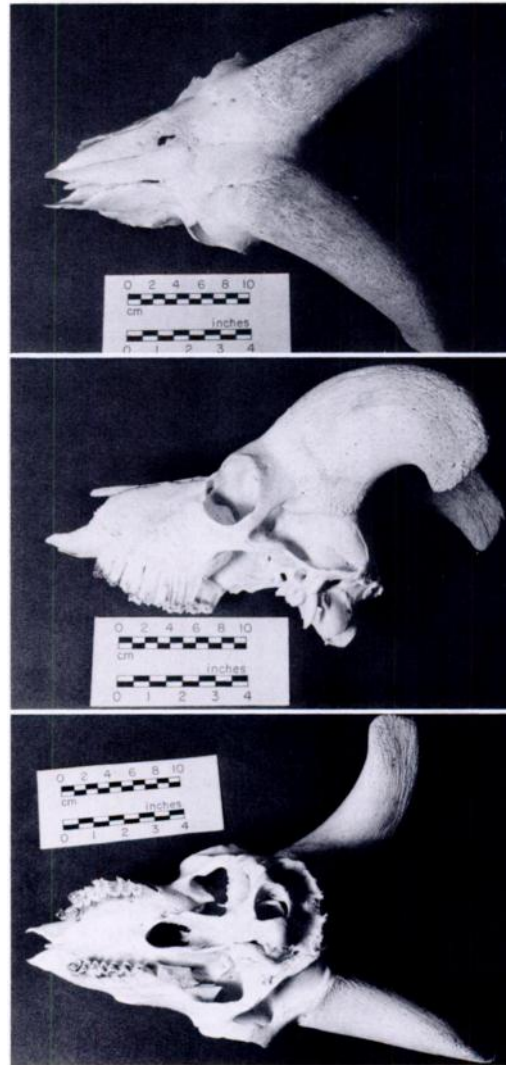


FIGURE 1. Skull of a male mountain sheep from San Diego County, California showing marked asymmetry in dorsal (above), lateral (middle), and ventral (lower) views. Note the lesion on the right nasal (dorsal view), and lack of osseous support for cheek teeth (lateral view).

fying screen and radiographic settings of 200 MaS and 74 kVp (dorso-ventral aspect) and 64 kVp (lateral aspect). Radiographs were exposed using a bucky and 1:8 grid at a focal-film distance of 100 cm. These radiographs demonstrated a discernable difference in bone density between the two skulls; the abnormal skull showed in-

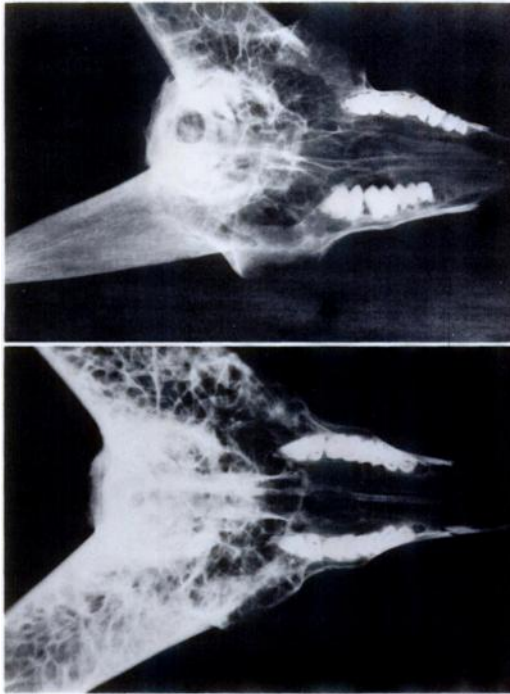


FIGURE 2. Radiographs of abnormal (above) and normal (below) male mountain sheep skulls. The abnormal skull exhibited an increased lucency and decreased numbers of trabeculae in cranial bones and cornual processes.

creased lucency, and decreased numbers and thickness of trabeculae in cranial bones and cornual processes. These findings are consistent with a diagnosis of osteoporosis.

To further evaluate potential causes of osteoporosis, microradiographic procedures of Eagle et al. (1982) were performed on subsamples of horn core and occipital bone collected from the same sites on normal and affected skulls.

The absence of indentations in microradiographs, which would be suggestive of Howship's lacunae, indicates a lack of osteoblastic resorption. Also microradiographs ruled out osteomalacia as the cause of osteoporosis in the affected skull because soft seams were absent along the apposition surfaces of Haversian and Volkmann's Canals (Fig. 3). No evidence of bone resorption was present.

Potential etiologies of osteoporosis are numerous and diverse (Jubb et al., 1985).

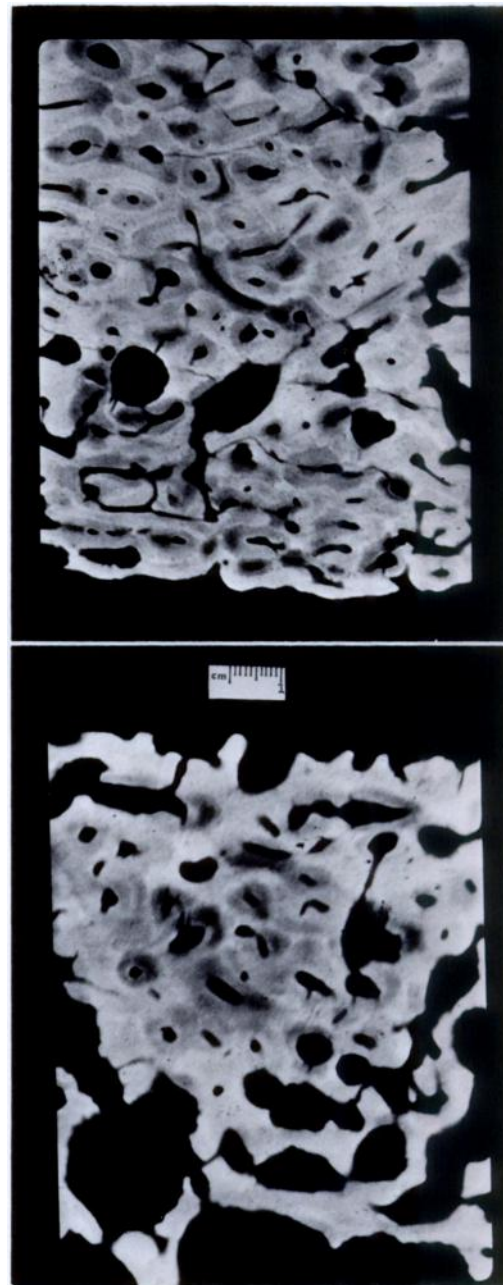


FIGURE 3. Comparative microradiographs of horn core of normal (top) and abnormal (bottom) mountain sheep. Note pronounced osteoporosis in lower third of micrograph of the affected sheep. 1 cm = 220 μ m.

If the lateral asymmetry of this specimen was related to a congenital defect, or resulted from trauma at an early age, a protein deficiency linked to malnutrition re-

sulting from the inability to forage efficiently may have occurred. We suspect that a congenital defect was unlikely, because a free-ranging mountain sheep probably would have succumbed prior to four years of age. In any case, malocclusion of the molars would result in an inability to properly masticate forage. Horn growth is related to nutrition in wild sheep (Bunnell, 1978). The extremely reduced horn size of this animal suggests malnutrition may have been a factor contributing to the osseous lesions. Other potential causes of osteoporosis include nutritional or renal hyperparathyroidism and rickets (Jubb et al., 1985).

Lesions with concurrent focal osteomyelitis have been described in association with chronic sinusitis (Bunch, 1979). However, the lack of reactive bone associated with the osteolysis seen in this specimen suggests that the triangular lesion is linked with generalized osteoporosis. Dalquest and Hoffmeister (1948) and Allred et al. (1966) have documented lateral deflection of the basioccipital region from the plane of the rostrum in male mountain sheep. Allred and Bradley (1965) speculated that unequal weight of horns may be a causative factor in such deviations. Jenks et al. (1986) described lateral deviation of a skull from a white-tailed deer (*Odocoileus virginianus*) fawn, but concluded that anomalous condition was congenital; we remain uncertain of the causative factors associated with asymmetry and osteoporosis in our specimen.

Although large numbers of skulls from desert-dwelling mountain sheep have been examined (Allred and Bradley, 1966; Bunch and Allen, 1981) osteoporosis was not reported. Similarities between lesions reported herein and those commonly associated with chronic frontal sinusitis (Bunch, 1979), might lead to misdiagnosis of some specimens. Consequently, investigators should evaluate each case carefully to distinguish between causes of these lesions.

This study was supported in part by grants from the Society for the Conser-

vation of Bighorn Sheep (SCBS), National Rifle Association, and Foundation for North American Wild Sheep. We thank D. and C. Jones (SCBS) for assistance with retrieving the specimen described herein, and especially L. Krook and C. Smith for preparation and microradiography of bone specimens.

LITERATURE CITED

- ALLRED, L. G., L. R. BAKER, AND W. G. BRADLEY. 1966. Additional studies of anomalies of the skull in desert bighorn sheep. Transactions of the California-Nevada Section of the Wildlife Society 1: 40-47.
- , AND W. G. BRADLEY. 1965. Necrosis and anomalies of the skull in desert bighorn sheep. Transactions of the Desert Bighorn Council 9: 75-81.
- , AND ———. 1966. Comparative study of necrosis associated with teeth in desert bighorn sheep. Transactions of the Desert Bighorn Council 10: 86-97.
- BENSON, S. B. 1943. Occurrence of upper canines in mountain sheep (*Ovis canadensis*). American Midland Naturalist 30: 786-789.
- BRADLEY, W. G., AND L. G. ALLRED. 1966. A comparative study of dental anomalies in desert bighorn sheep. Transactions of the Desert Bighorn Council 10: 78-85.
- BUNCH, T. D. 1979. Skeletal lesions associated with desert bighorn chronic sinusitis. Transactions of the Desert Bighorn Council 23: 27-32.
- , AND S. D. ALLEN. 1981. Survey of chronic sinusitis-induced skull anomalies in desert bighorn sheep. Journal of the American Veterinary Medical Association 179: 1150-1152.
- , H. E. MCCUTCHEN, AND S. R. PAUL. 1978. Desert bighorn—Doomed by a fly. Utah Science 39: 97-103.
- BUNNELL, F. L. 1978. Horn growth and population quality in Dall sheep. The Journal of Wildlife Management 42: 764-775.
- COWAN, I. M. 1940. Distribution and variation in the mountain sheep of North America. American Midland Naturalist 24: 505-580.
- DALQUEST, W. W., AND D. F. HOFFMEISTER. 1948. Mountain sheep from the state of Washington in the collection of the University of Kansas. Transactions of the Kansas Academy of Sciences 51: 224-234.
- EAGLE, M. E., D. B. KOCH, J. P. WHELAN, H. F. HINTZ, AND L. KROOK. 1982. Mineral metabolism and immobilization osteopenia in ponies treated with 25-Hydroxycholesterol. The Cornell Veterinarian 72: 372-393.
- GEIST, V. 1966. Validity of horn segment counts in aging bighorn sheep. The Journal of Wildlife Management 30: 634-646.

- JENKS, J. A., D. M. LESLIE, JR., AND H. C. GIBBS. 1986. Anomalies of the skull of a white-tailed deer fawn from Maine. *Journal of Wildlife Diseases* 22: 286-289.
- JUBB, K. V. F., P. C. KENNEDY, AND N. PALMER. 1985. *Pathology of domestic animals*, Vol. 1, 3rd ed. Academic Press, Orlando, Florida, 574 pp.
- KIGER, J. H. 1963. Sheep skull study. *Transactions of the Desert Bighorn Council* 7: 145-148.
- PAUL, S. R., AND T. D. BUNCH. 1978. Chronic frontal sinusitis and osteolysis in desert bighorn sheep. *Journal of the American Veterinary Medical Association* 173: 1178-1180.
- RUSSI, T. L. 1978. Notes on a group of peninsular bighorn. *Transactions of the Desert Bighorn Council* 22: 43-44.
- TURNER, J. C. 1982. Chronic cranial osteitis in a Rocky Mountain bighorn sheep. *Journal of Wildlife Diseases* 18: 373-379.

Received for publication 19 October 1988.