

Strongyloidiasis in Cotton Rats (*Sigmodon hispidus*) from Central Oklahoma

Authors: Chandikumar S. Elangbam, Charles W. Qualls Jr., Robert L. Lochmiller, and James F. Boggs

Source: Journal of Wildlife Diseases, 26(3) : 398-402

Published By: Wildlife Disease Association

URL: <https://doi.org/10.7589/0090-3558-26.3.398>

BioOne Complete (complete.BioOne.org) is a full-text database of 200 subscribed and open-access titles in the biological, ecological, and environmental sciences published by nonprofit societies, associations, museums, institutions, and presses.

Your use of this PDF, the BioOne Complete website, and all posted and associated content indicates your acceptance of BioOne's Terms of Use, available at www.bioone.org/terms-of-use.

Usage of BioOne Complete content is strictly limited to personal, educational, and non-commercial use. Commercial inquiries or rights and permissions requests should be directed to the individual publisher as copyright holder.

BioOne sees sustainable scholarly publishing as an inherently collaborative enterprise connecting authors, nonprofit publishers, academic institutions, research libraries, and research funders in the common goal of maximizing access to critical research.

Strongyloidiasis in Cotton Rats (*Sigmodon hispidus*) from Central Oklahoma

Chandikumar S. Elangbam,¹ Charles W. Qualls, Jr.,¹ Robert L. Lochmiller,² and James F. Boggs,² ¹ Department of Veterinary Pathology, College of Veterinary Medicine, Oklahoma State University, Stillwater, Oklahoma 74078, USA; ² Department of Zoology, Oklahoma State University, Stillwater, Oklahoma 74078, USA

ABSTRACT: Thirty-one of 40 cotton rats (*Sigmodon hispidus*) collected from central Oklahoma were infected with *Strongyloides* sp. (78% prevalence). Larvae of *Strongyloides* sp. (rhabditiform or filariform) were not demonstrable in intestinal contents and scrapings. Female nematodes recovered from intestinal contents and scrapings had morphological similarities with *Strongyloides sigmodontis*. Cotton rats infected with *Strongyloides* sp. were indistinguishable clinically from non-infected hosts. Infected animals had no significant gross lesions, but the presence of *Strongyloides* sp. in the intestinal mucosa was associated with villus atrophy and mild to moderate infiltration of the lamina propria by lymphocytes, plasma cells and occasional eosinophils. Other organs or tissues examined were free from lesions induced by *Strongyloides* sp.

Key words: *Strongyloides* sp., nematode infection, prevalence, pathology, cotton rats, *Sigmodon hispidus*.

Species within the genus *Strongyloides* parasitize many domestic and wild animals, including humans (Flynn, 1973; Stewart et al., 1976; Moqbel, 1980; Clark, 1984). Although species of *Strongyloides* have been reported from all regions of the gastrointestinal tract, including the stomach (Winter, 1958) and large intestine (Little, 1966), most species infect the anterior small intestine where larvae are found in tunnels within the intestinal mucosa. Infections of high intensity can cause mortality in neonatal animals under appropriate epizootiologic circumstances (McClure and Guilloud, 1971). Clinical signs of infected animals often include diarrhea, weight loss, dehydration, hypoproteinemia, eosinophilia, anorexia and debility (McClure et al., 1973).

Infection of cotton rats with *Strongyloides* sp. was first reported by Baylis (1945). Melvin and Chandler (1950) subsequently described *Strongyloides sig-*

modontis and reported its prevalence in populations of cotton rats. High prevalences of *S. sigmodontis* have been reported among cotton rat populations in Florida and Texas (Kinsella, 1974; Martin and Huffman, 1980); but the pathology associated with these infections has not been described. The aim of this study was to describe the gross and microscopic lesions resulting from infections of *Strongyloides* sp. in wild cotton rats collected from central Oklahoma, a region where *Strongyloides* sp. has not been reported previously.

We collected cotton rats from two distinct populations inhabiting similar habitats in McClain County, central Oklahoma (USA; 34°58'N, 97°35'W), in January and August of 1987. Animals were collected from un-grazed, tall-grass prairie within a post oak (*Quercus stellata*)-blackjack oak (*Quercus marilandica*) savanna ecosystem using Sherman live-traps (Sherman Traps, Inc., Tallahassee, Florida 32316, USA) baited with rolled oats. Cotton rats were returned to the laboratory, placed in individual polycarbonate cages with wire tops containing wood-chips as bedding, and fasted overnight with water provided ad libitum. Age of cotton rats (Stafford and Stout, 1983) was determined using body weight criteria (<60 g, juvenile; 60 to <100 g, subadult; >100 g, adult). Cotton rats were then killed by cervical dislocation and necropsied. Liver, kidney, adrenal, pancreas and representative samples of intestinal areas, reproductive organs, brain, heart and skin were fixed in 10% buffered formalin and processed for paraffin embedment. Tissue samples were sectioned at 6 µm and stained with hematoxylin and eosin. Gastrointestinal contents

TABLE 1. Prevalence and intensity of *Strongyloides* sp. in cotton rats collected from central Oklahoma, January and August 1987.

Sex	Age	Prevalence		Intensity
		Number infected/ number examined	%	
Male	Adult	11/11	100	69.3 ± 25.7*
	Subadult	11/13	85	9.0 ± 4.4
	Juvenile	1/3	33	3.0
Female	Adult	2/6	33	8.5 ± 5.5
	Subadult	5/5	100	6.2 ± 2.1
	Juvenile	1/2	50	1.0

* Mean ± standard error.

and mucosal scrapings were examined for *Strongyloides* sp. with the aid of a dissecting microscopy.

Nematodes were mounted in lactophenol for study of their morphologic characters. Only female *Strongyloides* sp. were found. Eleven randomly selected worms from five cotton rats had the following morphologic features: body length, 3.45 to 4.56 mm; diameter in esophageal region, 30 µm; diameter just anterior to anus, 25 to 30 µm; length of esophagus, 0.71 to 0.82 mm (18 to 21% of total body length); vulva with slightly elevated lips located 2.08 to 2.90 mm from anterior end (60 to 64% of total body length); uteri with 10 to 18 eggs and eggs, 23 to 42 µm long; and tail constricted just posterior to anus and ends bluntly. These morphologic characters were similar to the description provided by Melvin and Chandler (1950) for *S. sigmodontis*. We did not attempt to culture larvae and free-living adults. Representative specimens of *Strongyloides* sp. collected in this study were deposited in the U.S. National Parasite Collection (Animal Parasitology Institute, USDA, Beltsville, Maryland 20705, USA; accession number 80566).

Forty wild cotton rats were collected from the two study locations. No clinical signs were observed in any cotton rats collected. Examination of intestinal contents and mucosal scrapings revealed *Strongy-*

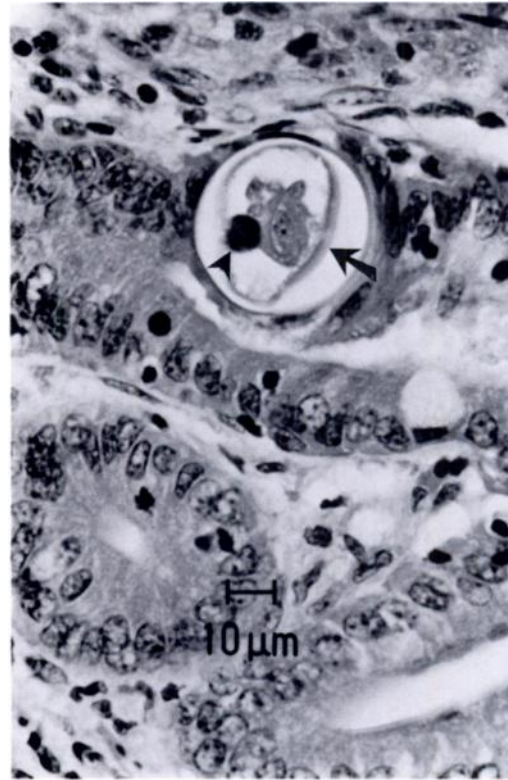


FIGURE 1. Histological section of small intestine from a cotton rat with cross sections of adult *Strongyloides* sp.; note smooth cuticle (arrow) and characteristic dark staining ovary (arrowhead). H&E.

loides sp. in 31 animals (78% prevalence) with a mean intensity of 29.5 ± 10.3 worms per infected host (Table 1). Range was 1 to 261 worms.

Gross lesions associated with *Strongyloides* sp. infection were not observed in any of the cotton rats. Histological examination revealed that 22 of 40 cotton rats had microscopic lesions associated with *Strongyloides* sp. The lesions of strongyloidiasis were confined to the small intestine with mild to moderate inflammatory responses. A few adults, eggs and numerous larvae of *Strongyloides* sp. were present in interepithelial tunnels at the base of villi and within crypt lumina (Figs. 1-3). Both rhabditiform and filariform (Fig. 3) larvae were present. Cross-sections of adult *Strongyloides* sp. in intestinal epithelium were characterized by a smooth cuticle,

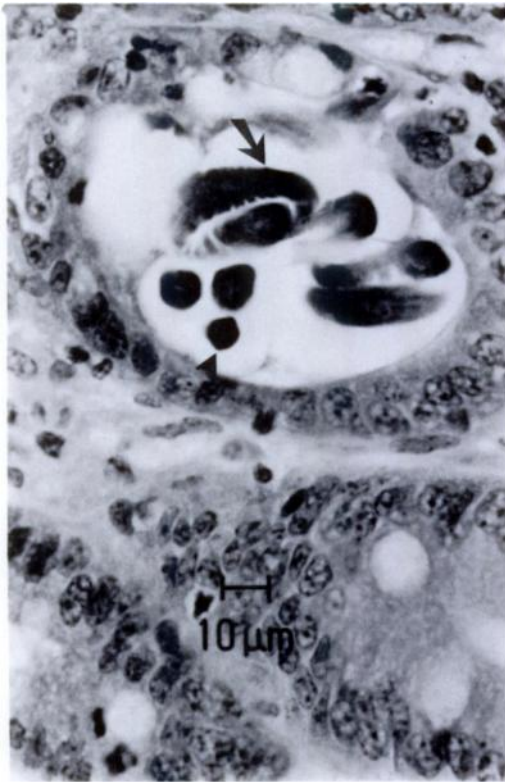


FIGURE 2. Eggs (arrowhead) and rhabditiform larva (arrow) of *Strongyloides* sp. within the intestinal crypt of a cotton rat. H&E.

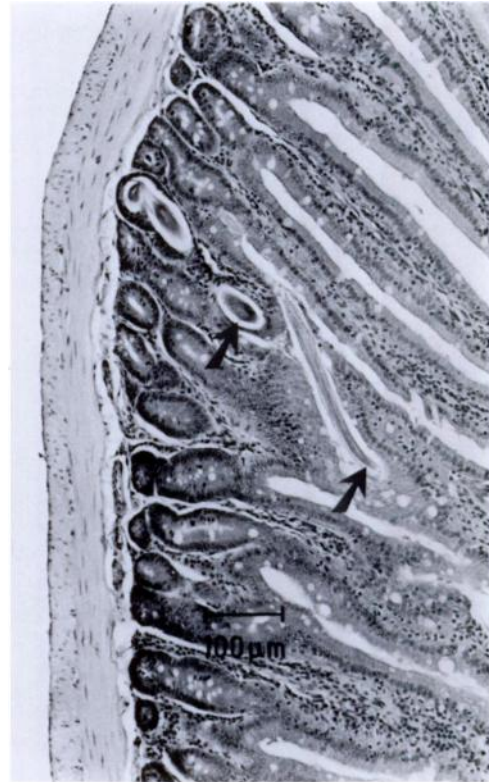

FIGURE 3. Small intestine from a cotton rat; note fragments of migrating larva (arrows) of *Strongyloides* sp. within the small intestinal crypts. H&E.

small body diameter (21 to 42 μm) and darkly stained ovaries and ova (Fig. 1). Diagnosis was supported by their intense staining capacity, size of ova, site of infection and frequent presence of eggs in cross sections (Chitwood and Lichtenfels, 1972). A moderate inflammatory response to the larvae of *Strongyloides* sp. characteristically included atrophic villi, moderately hyperactive crypts, epithelial hyperplasia and infiltration with lymphocytes, plasma cells, and eosinophils in the lamina propria (Fig. 4). Occasionally, the crypt lumina contained degenerate, necrotic sloughed epithelial cells. In mild inflammatory responses, changes in the villi and crypts of Lieberkuhn, including infiltration with lymphocytes and plasma cells in the lamina propria, were minimal. Submucosa and serosa of the small intestine essentially were normal. Microscopic

changes of the small intestine observed in our study were similar to infections of *Strongyloides ratti* of laboratory rats (Moqbel, 1980). *Strongyloides* sp. was not observed in the esophagus, stomach and large intestine of infected cotton rats. Likewise, histologic examination of other organs (liver, kidney, lung, heart, adrenals, genital organs, brain, skin and pancreas) showed no lesions associated with *Strongyloides* sp.

Prevalence of *Strongyloides* sp. infection observed in our study was greater than the 49% reported for *S. sigmodontis* in cotton rat populations in Texas (Martin and Huffman, 1980) and 14% in Florida (Kinsella, 1974), but similar to the 70% reported by Melvin and Chandler (1950) in Texas. Melvin and Chandler (1950) attempted to infect a variety of potential

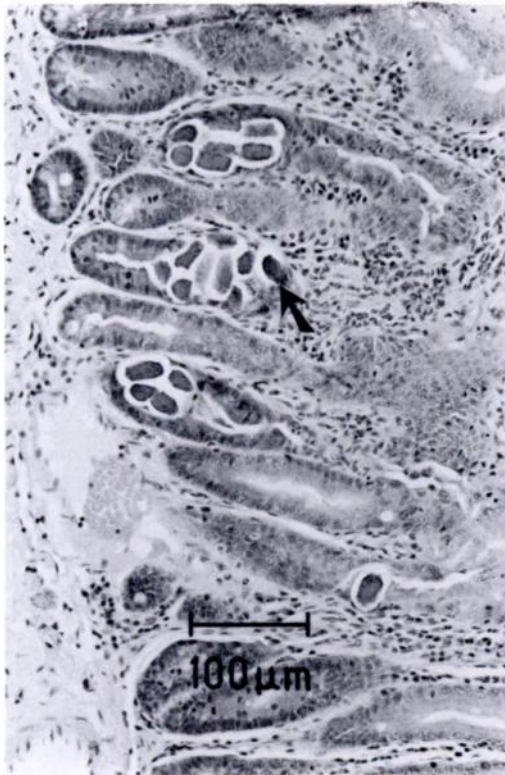

FIGURE 4. Moderately hyperactive crypts and infiltration of mononuclear cells and eosinophils through lamina propria of small intestine of a cotton rat with *Strongyloides* sp.; note embryonated egg within the crypts (arrow). H&E.

hosts, including hamsters, guinea pigs, white rats, mice and rabbits, with subcutaneous injections of large numbers (1,000 to 1,200) of filariform larvae. They were unsuccessful at infecting these potential hosts, concluding that *S. sigmodontis* is host-specific for the cotton rat.

Autoinfection has been reported for *S. stercoralis* and *S. felis*, where eggs discharged from adult females develop into larvae without the need to exit the host. In cases where autoinfection has occurred, changes in small and large intestines in response to invasion by filariform larvae range from a mild inflammatory cell response to severe, acute, or granulomatous or necrotizing enterocolitis. Larval invasion of the submucosal and serosal lymphatics during autoinfection can result in

severe endolymphangitis with various degrees of lymphatic obstruction and submucosal and serosal edema, fibrosis or both (Deppaoli and Johnsen, 1978). Some *Strongyloides* spp. apparently can be transmitted in utero and through mammary secretions (Flynn, 1973). *Strongyloides* sp. reported in this study has the potential of autoinfection as evidenced by presence of larvae in the crypts. However, we were unable to find any evidence of *Strongyloides* sp. lesions in the large intestine, liver, lung, esophagus or skin sections of infected cotton rats. Furthermore, no filariform larvae were demonstrable in intestinal contents, including mucosal scrapings. Autoinfection undoubtedly can contribute to the severity of infection in a host, but further study is needed to assess its role and impact in the cotton rat.

This paper is submitted as College of Veterinary Medicine, Oklahoma State University, manuscript number 89-003.

LITERATURE CITED

- BAYLIS, H. A. 1945. Helminths from the American cotton rat (*Sigmodon hispidus*). *Annals and Magazine of Natural History*, Series 12: 189-195.
- CHITWOOD, M., AND J. R. LICHTENFELS. 1972. Identification of parasite metazoa in tissue sections. *Experimental Parasitology* 32: 407-519.
- CLARK, D. J. 1984. Biology and diseases of other rodents. In *Laboratory animal science*, J. G. Fox, B. J. Cohen, and D. Loew (eds.). Academic Press, Orlando, Florida, pp. 183-206.
- DEPPAOLI, A., AND D. O. JOHNSEN. 1978. Fatal strongyloidiasis in gibbons (*Hylobates lar*). *Veterinary Pathology* 17: 48-70.
- FLYNN, R. J. 1973. Nematodes. In *Parasites of laboratory animals*. Iowa University Press, Ames, Iowa, 320 pp.
- KINSELLA, J. M. 1974. Comparison of helminth parasites of the cotton rat, *Sigmodon hispidus*, from several habitats in Florida. *American Museum Novitates* 2540: 1-11.
- LITTLE, M. D. 1966. Seven new species of *Strongyloides* (Nematoda) from Louisiana. *The Journal of Parasitology* 52: 85-97.
- MARTIN, J. L., AND D. G. HUFFMAN. 1980. An analysis of the community and population dynamics of the helminths of *Sigmodon hispidus* (Rodenta: Cricetidae) from three central Texas vegetational regions. *Proceedings of the Helminthological Society of Washington* 47: 247-255.
- MCCLURE, H. M., AND N. B. GUILLOU. 1971.

- Comparative pathology of the chimpanzee. In *The chimpanzee*, G. H. Bourne and S. Karger (eds.). Basel, Switzerland, pp. 103-273.
- , L. M. STROZIER, M. E. KEELING, AND G. R. HEALY. 1973. Strongyloidosis in two infant orangutans. *Journal of the American Veterinary Medical Association* 163: 629-632.
- MELVIN, D. M., AND A. C. CHANDLER. 1950. New helminth records from the cotton rat, *Sigmodon hispidus*, including a new species, *Strongyloides sigmodontis*. *The Journal of Parasitology* 36: 505-510.
- MOQBEL, R. 1980. Histopathological changes following primary, secondary, and repeated infections of rats with *Strongyloides ratti* with special reference to tissue eosinophils. *Parasite Immunology (Oxford)* 2: 11-17.
- STAFFORD, S. R., AND I. J. STOUT. 1983. Dispersal of the cotton rat, *Sigmodon hispidus*. *Journal of Mammalogy* 64: 210-217.
- STEWART, T. B., W. M. STONE, AND O. G. MARTI. 1976. *Strongyloides ransomi*: Prenatal and transmammary infection of pigs of sequential litters from dams experimentally exposed as weanlings. *American Journal of Veterinary Research* 37: 541-544.
- WINTER, H. 1958. Gastric strongyloidiasis in kangaroos. *Australian Veterinary Journal* 34: 118-120.

Received for publication 20 February 1989.