BioOne COMPLETE

Congenital Osteopetrosis in White-tailed Deer (Odocoileus Virginianus)

Authors: Smits, Bronwyn, and Bubenik, George A.

Source: Journal of Wildlife Diseases, 26(4) : 567-571

Published By: Wildlife Disease Association

URL: https://doi.org/10.7589/0090-3558-26.4.567

BioOne Complete (complete.BioOne.org) is a full-text database of 200 subscribed and open-access titles in the biological, ecological, and environmental sciences published by nonprofit societies, associations, museums, institutions, and presses.

Your use of this PDF, the BioOne Complete website, and all posted and associated content indicates your acceptance of BioOne's Terms of Use, available at www.bioone.org/terms-of-use.

Usage of BioOne Complete content is strictly limited to personal, educational, and non - commercial use. Commercial inquiries or rights and permissions requests should be directed to the individual publisher as copyright holder.

BioOne sees sustainable scholarly publishing as an inherently collaborative enterprise connecting authors, nonprofit publishers, academic institutions, research libraries, and research funders in the common goal of maximizing access to critical research.

Downloaded From: https://bioone.org/journals/Journal-of-Wildlife-Diseases on 28 Mar 2024
Terms of Use: https://bioone.org/terms-of-use

Journal of Wildlife Diseases, 26(4), 1990, pp. 567–571
© Wildlife Disease Association 1990

Congenital Osteopetrosis in White-tailed Deer (*Odocoileus virginianus*)

Bronwyn Smits[1] **and George A. Bubenik,**[2] [1] Department of Pathology, Ontario Veterinary College, University of Guelph, Guelph, Ontario, Canada N1G 2W1; [2] Department of Zoology, University of Guelph, Guelph, Ontario, Canada N1G 2W1

ABSTRACT: Inferior brachygnathia in neonatal fawns occurred sporadically over a 10 yr period in a captive herd of white-tailed deer (*Odocoileus virginianus*) in southern Ontario. Two fawns submitted for necropsy had marked inferior brachygnathia, protruding tongues, and fractured long bones. Radiographs of the limbs revealed longitudinal striations of relatively translucent immature woven bone that caused loss of distinction between medullary cavities and cortices. Microscopically, there was failure of remodelling of the primary spongiosa and filling of the medulla by cone-shaped chondro-osseous cores. The findings supported a diagnosis of osteopetrosis, usually a hereditary disease characterized by absence of marrow cavities as a result of defective bone remodelling. Osteopetrosis has not been reported previously in deer.

Key words: Osteopetrosis, *Odocoileus virginianus*, inferior brachygnathia, congenital anomaly, bone, case report.

This report describes an unusual congenital anomaly which occurred in an inbred captive herd of white-tailed deer (*Odocoileus virginianus*). The herd was formed in 1973 from one buck and one doe, both originating from a small captive herd of <10 does in the locality of Minesing, Ontario (Canada; 44°26′N, 79°50′W). The mating resulted in the birth of twin females which were subsequently bred by their father. By July, 1989, the herd consisted of 12 does and nine normal fawns. Over the years 1979, 1983, 1985 and 1989, six fawns, representing 6% of the fawns born over the 11 yr period, had inferior brachygnathia, protruding tongues and fragile long bones. Those affected which were born in 1983 and 1985 also had domed skulls. Three of the six fawns were born in 1989. Two of these were thought to be twins because they were found dead, lying together. The third, a singleton, was found alive but recumbent, and died within a few hours of birth. One of the twins (a female) and the singleton (also female) were submitted for necropsy.

Gross findings were similar in both animals. There was marked inferior brachygnathia and protrusion of the tongue (Fig. 1). Mandibular molar teeth were impacted, with some teeth oriented horizontally and medially. No ingesta was found in the abomasum of either fawn. The long bones were laterally bowed and fractured easily with lateral manual pressure. Mid-shaft calluses were present on several ribs of each animal, indicating in utero fracture. Both fawns had fractures of the tibias, and the singleton also had a fractured humerus. Hemorrhages associated with the fractures indicated that they were ante mortem. The singleton had lost the eponychium from its hoofs and its lungs were inflated. Radiographically, the medullary cavities of the humerus, femur, tibia and radius were indistinguishable from the cortices. Prominent striations caused by alternating radiolucent and radiodense metaphyseal bands were oriented along the long axes of the bones. The growth plates appeared normal. Centrally located wedge-shaped densities were present in the vertebral bodies. The medullary cavities of longitudinally sectioned bones (femur, tibia, humerus, radius, metacarpus, metatarsus) of both fawns were each occupied by two cone-shaped masses of dense chondro-osseous tissue. The bases of these cones were positioned at the proximal and distal physes and the apices met almost mid-shaft (Fig. 2).

Samples of liver and lung were plated onto blood agar and MacConkey's agar for routine bacterial isolation. Recovery of many hemolytic and non-hemolytic *Esch-*

Downloaded From: https://bioone.org/journals/Journal-of-Wildlife-Diseases on 28 Mar 2024
Terms of Use: https://bioone.org/terms-of-use

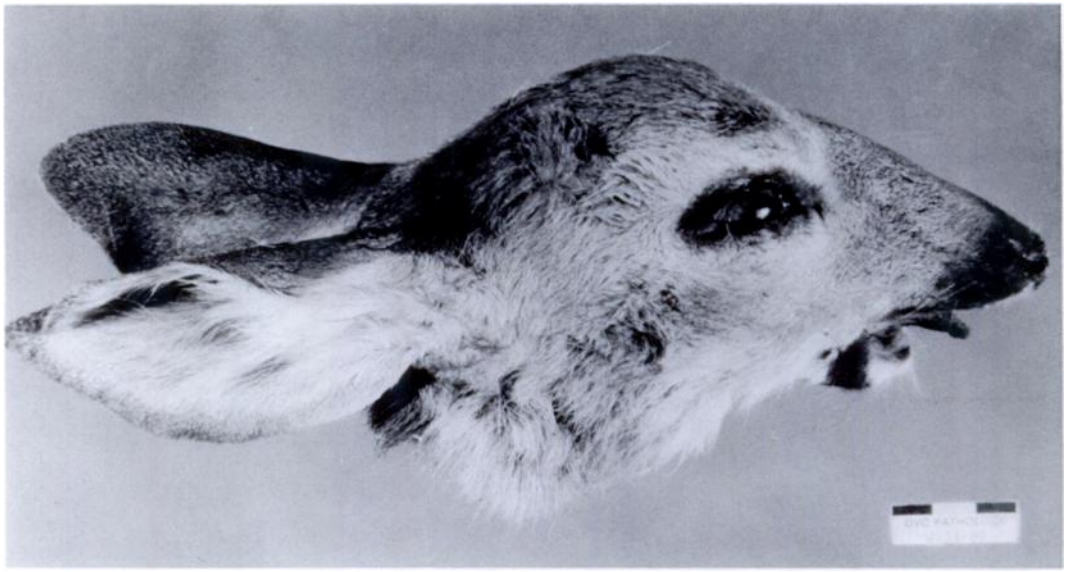

FIGURE 1. Head of affected fawn exhibiting inferior brachygnathia and mild protrusion of the tongue.

erichia coli was deemed an insignificant findings.

For histological examination, samples of physes, metaphyses and diaphyses of long bones and mandibles were fixed in 10% neutral buffered formalin, decalcified, sectioned routinely and stained with hematoxylin and eosin. Matched control samples were obtained from another, apparently normal, white-tailed deer fawn of equivalent age, and were treated similarly. Microscopic lesions in the affected fawns were found in the metaphyses and diaphyses of the long bones. There was failure of remodelling of the primary spongiosa, characterized by persistent primary trabeculae with little maturation. The resultant cone-shaped chondro-osseous bone in the medullary cavity was sharply demarcated from the surrounding cortical laminae (Fig. 3). The cones consisted of persistent primary spongiosa that originated at the physis. This spongiosa contained intact columns of calcified central cartilaginous cores, many with hypertrophied chondrocytes. The columns were surrounded by woven bone. There was limited amalgamation of the immature trabeculae into secondary spongiosa. Surrounding the cones, cortical bone formed thin lamellar trabeculae, with no zone of compaction of endochondral bone. No such changes were present in the bones of the control fawn. Cement lines indicating alternating periods of osteoclastic activity and rest were readily apparent in affected and control bones. Other histological findings in the fawn found dead included fetal pulmonary atelectasis and numerous intra-alveolar amniotic squames, indicative of fetal distress. The cause of death in this fawn was uncertain. Death of the singleton was considered to be due to starvation and/or hypothermia. On the basis of the characteristic gross and microscopic skeleton lesions, a diagnosis of osteopetrosis was established in both animals (Jubb et al., 1985).

The characteristic microscopic skeletal lesions and inferior brachygnathia observed in these fawns were similar to those found in Aberdeen Angus and Hereford calves with osteopetrosis (Greene et al., 1974; Leipold et al., 1970). Ojo et al. (1975) also described cysts in the frontal bones and metaphyses of most long bones of affected Hereford calves. Additional findings reported in affected calves include abnormal skull development, resulting in

Downloaded From: https://bioone.org/journals/Journal-of-Wildlife-Diseases on 28 Mar 2024
Terms of Use: https://bioone.org/terms-of-use

FIGURE 2. Longitudinal sections of humerus (left), radius (center), and femur (right) from affected fawn. Notice absence of medullary cavity due to the presence of conical bone cores, with bases at the proximal and distal epiphyses, and apices meeting mid-shaft.

FIGURE 3. Photomicrograph of longitudinal section of humerus taken mid-diaphysis and showing the tip of the endo-chondral bone core (a) within the laminar cortical layer (b). H&E.

cerebral compression and cerebellar herniation, and hypoplasia of the optic nerve. Such lesions were not found in these fawns. However, two other fawns born in 1983 and 1985 that were observed to have inferior brachygnathia, but were not necropsied, did have domed skulls.

The herd history of a small genetic base and considerable inbreeding suggested the possibility of an autosomally recessive mode of inheritance of the disease. The founding buck was kept as the sole breeding male until 1975. A second buck replaced the founder in 1976 and 1977, and he was succeeded by a third buck, who was the only breeding male between 1978 and 1980. In 1979 the first case of inferior brachygnathia was seen in an offspring of the third buck. It is possible that either the founding doe or founding buck was heterozygous for the gene involved and the third buck, which came from the same small captive herd as these founding members, was similarly heterozygous. This may explain why no cases were seen prior to 1979. During the breeding seasons of 1981–1984, a fourth buck was the only male used. He sired two affected fawns. The fifth buck, the son of the third buck, sired the fawns born in 1985 to 1989. Both the fourth and fifth bucks also originated from the same small captive herd as the founding deer and were possibly heterozygotes. It is not known if the disease has been seen in the original herd.

During the 17 yr period of the herd's existence only two new does were introduced, so the herd concentrated its genetic pool by considerable inbreeding. This may account for the initial sporadic occurrence of the disease, and in 1989 the appearance of three cases, as the gene spread in the

Downloaded From: https://bioone.org/journals/Journal-of-Wildlife-Diseases on 28 Mar 2024
Terms of Use: https://bioone.org/terms-of-use

female population. Herd records are incomplete and the genealogy of the necropsied fawns is unknown, but it is probable that they resulted from father-daughter or sibling-sibling matings. Until 1989 it was not clear that more than one doe was involved, but the birth of three affected fawns indicates that if the disease is due to an autosomal recessive gene, then the genotype may be spreading in the herd. Although a viral etiology cannot be ruled out, the pattern of emergence of the disease would suggest vertical transmission, and random, sporadic occurrence. Similarly, a toxic agent may be responsible, but the long history of sporadic occurrence of the disease tends to preclude such etiologies.

Mandibular anomalies are commonly seen in deer, as many thousands of mandibles of white-tailed deer are examined each year for age determination. However, the skeletal deformities recorded concomitantly have not included osteopetrosis. Inferior brachygnathia has been reported in association with arthrogryposis (Barrett and Chalmers, 1975) and limb rotation (Scanlon, 1973; Wobeser and Runge, 1973). It is also seen in mature deer, indicating that in a mild form, and unassociated with other skeletal abnormalities, it need not impede survival (Ryel, 1963).

Osteopetrosis in humans is an hereditary disease first described by Karshner (1926). Studies have indicated that in humans the disease is due to abnormally decreased activity of osteoclasts (Marks and Walker, 1976). Two genetic variants of the disease are recognized in humans: an autosomal dominant type and a so-called malignant recessive type. Only the latter has been described in animals. Osteopetrosis has been described in cattle (Leipold et al., 1970; Greene et al., 1974; Ojo et al., 1975), mutant strains of rats and mice, rabbits, dogs, sheep, pigs (Jubb et al., 1985) and horses (Nation and Klavano, 1986). Osteopetrosis in the murine forms is characterized by both increased bone formation and decreased bone resorption, whereas in the rabbit it is attributable to osteoblastic incompetence (Bollerslev, 1989).

The cervine and bovine forms of osteopetrosis appear to be of the malignant recessive type as described in humans. The small sample size and incomplete herd records in this report preclude anything more than a suggestion that inferior brachygnathia may be a phenotypic marker for the lesions of osteopetrosis. For the same reasons it can only be postulated that the disease is due to the inheritance of a recessive gene. However, when environmental or artificial circumstances cause inbreeding of animals and offspring are born with inferior brachygnathia, osteopetrosis should be considered.

This report was supported in part by the Ontario Ministries of Natural Resources and Health. The assistance and encouragement of N. C. Palmer, I. K. Barker and R. B. Miller is gratefully acknowledged. Thanks are similarly extended to Pat Weir, Helga Hunter, Tim Sullivan and Ted Eaton for their technical help.

LITERATURE CITED

BARRETT, M. W., AND G. A. CHALMERS. 1975. Congenital anomalies in a neonatal white-tailed deer in Alberta. Journal of Wildlife Diseases 11: 497–501.

BOLLERSLEV, J. 1989. Autosomal dominant osteopetrosis: Bone metabolism and epidemiological, clinical and hormonal aspects. Endocrine Reviews 10: 45–67.

GREENE, H. J., H. W. LEIPOLD, C. M. HIBBS, AND C. A. KIRKBRIDE. 1974. Congenital osteopetrosis. Journal of the American Veterinary Medical Association 164: 389–395.

JUBB, K. V. F., P. C. KENNEDY, AND N. C. PALMER (editors). 1985. Diseases of bone. *In* The pathology of domestic animals, Vol. 1, 3rd ed. Academic Press, Inc., Orlando, Florida, pp. 1–138.

KARSHNER, R. G. 1926. Osteopetrosis. American Journal of Roentgenology 16: 405–419.

LEIPOLD, H. W., C. E. DOIGE, M. M. KAYE, AND P. H. CRIBB. 1970. Congenital osteopetrosis in Aberdeen Angus calves. Canadian Veterinary Journal 11: 181–185.

MARKS, S. C., JR., AND D. G. WALKER. 1976. Mammalian osteopetrosis: A model system for studying cellular and humoral factors in bone resorption. *In* The biochemistry and physiology of

Downloaded From: https://bioone.org/journals/Journal-of-Wildlife-Diseases on 28 Mar 2024
Terms of Use: https://bioone.org/terms-of-use

bone, Vol. 4, G. Bourne (ed.). Academic Press, New York, New York, pp. 227–301.

NATION, P. N., AND G. G. KLAVANO. 1986. Osteopetrosis in two foals. Canadian Veterinary Journal 27: 74–77.

OJO, S. A., H. W. LEIPOLD, D. Y. CHO, AND M. M. GUFFY. 1975. Osteopetrosis in two Hereford calves. Journal of the American Veterinary Medical Association 166: 781–783.

RYEL, L. A. 1963. The occurrence of certain anomalies in Michigan white-tailed deer. Journal of Mammalogy 44: 79–98.

SCANLON, P. F. 1973. Abnormalities of mandibles and limbs in white-tailed deer from Virginia. Proceedings of the Southeastern Association of Game and Fish Commissioners 27: 301–302.

WOBESER, G., AND W. RUNGE. 1973. Multiple anomalies in a white-tailed deer fetus. Journal of Wildlife Diseases 9: 356–358.

Received for publication 18 October 1989.

Downloaded From: https://bioone.org/journals/Journal-of-Wildlife-Diseases on 28 Mar 2024
Terms of Use: https://bioone.org/terms-of-use