

OBSERVATIONS OF VAGINAL CALCULI IN DOLPHINS

Authors: Woodhouse, Charles D., and Rennie, Charles J.

Source: Journal of Wildlife Diseases, 27(3) : 421-427

Published By: Wildlife Disease Association

URL: <https://doi.org/10.7589/0090-3558-27.3.421>

BioOne Complete (complete.BioOne.org) is a full-text database of 200 subscribed and open-access titles in the biological, ecological, and environmental sciences published by nonprofit societies, associations, museums, institutions, and presses.

Your use of this PDF, the BioOne Complete website, and all posted and associated content indicates your acceptance of BioOne's Terms of Use, available at www.bioone.org/terms-of-use.

Usage of BioOne Complete content is strictly limited to personal, educational, and non - commercial use. Commercial inquiries or rights and permissions requests should be directed to the individual publisher as copyright holder.

BioOne sees sustainable scholarly publishing as an inherently collaborative enterprise connecting authors, nonprofit publishers, academic institutions, research libraries, and research funders in the common goal of maximizing access to critical research.

OBSERVATIONS OF VAGINAL CALCULI IN DOLPHINS

Charles D. Woodhouse and Charles J. Rennie III

Department of Vertebrate Zoology, Santa Barbara Museum of Natural History,
2559 Puesta del Sol Road, Santa Barbara, California 93105, USA

ABSTRACT: Vaginal calculi have been described from the common (*Delphinus delphis*), Pacific white-sided (*Lagenorhynchus obliquidens*) and spotted (*Stenella attenuata*) dolphins. We describe additional calculi found in six sexually mature *D. delphis* from southern California. Three calculi were large (ca. 7 × 5 cm), exhibited concentric layer crystallization, and were unique from previously published descriptions. One calculus described previously and one in our sample appeared to be a fetal skeleton and skull respectively. Using CAT scans of a first trimester northern right whale dolphin (*Lissodelphis borealis*) and of a near term *Delphinus delphis*, we discuss the potential origin and development of vaginal calculi through analysis of ossification in embryonic delphinids. We hypothesize that the calculi represented spontaneous incomplete abortion with retention of part or all of the fetus in the distal reproductive tract. The form of the calculus relates to the degree of skeletal development at the time of fetal death. Calculi from a pregnant dolphin provided one measure of residence time.

Key words: Vaginal calculi, *Delphinus delphis*, common dolphin, *Lissodelphis borealis*, northern right whale dolphin, fetal skeleton, necropsy, CAT scan.

INTRODUCTION

Occurrences of vaginal calculi have been described from three species of delphinid cetaceans, *Delphinus delphis*, *Lagenorhynchus obliquidens* and *Stenella attenuata* (Harrison, 1969; Sawyer and Walker, 1977; Benirschke et al., 1984). Harrison (1969) was among the first to describe these structures and proposed that they were vaginal plugs formed from coagulated seminal fluid. Sawyer and Walker (1977) reported on nine instances of vaginal calculi from sexually mature dolphins and demonstrated that they are composed of four types of calcium phosphate compounds also found in mammalian bone.

Benirschke et al. (1984) described vaginal calculi from a common dolphin. They recovered 35 fetal bones from the vaginal tract including 15 ribs, skull fragments, and apparently pelvic bones. They also mentioned the absence of vertebrae. Their paper was the first to postulate a relationship between cetacean vaginal calculi and aborted fetuses. They further suggested that elements of the aborted fetal skeleton, trapped in the vagina, will eventually crystallize and coalesce.

Our objectives in this study are to present additional unique cases of vaginal cal-

culi found in *D. delphis* and to extend an interpretation of the phenomenon through skeletal analysis of early, late and term delphinid fetuses.

MATERIALS AND METHODS

Dolphin specimens were obtained as part of the Santa Barbara Museum of Natural History's (SBMNH; Santa Barbara, California 93105, USA) marine mammal salvage program. One additional calculus was obtained from the Natural History Museum of Los Angeles County (NHMLAC; Los Angeles, California 90007, USA). In each case, calculi were recovered as part of routine post-mortem analysis. After reproductive tracts were dissected, calculi were photographed in situ, subsequently weighed dry, and measured.

Eosin and hematoxylin stained preparations of vaginal wall, pseudo-cervix and cervix for histological analysis were made from formalin preserved tissues.

Three, fluid preserved, delphinid fetuses were studied using Computer Axial Tomography (CAT scan) to delineate skeletal features and skeletal development. These included two near term *D. delphis* fetuses (SBMNH 76-45A and 82-13A) and one early, probably first trimester *Lissodelphis borealis* fetus (SBMNH 81-26A). All are in the SBMNH collections. The latter is the only early stage fetus that was readily available in the SBMNH collection, but the authors feel it is representative of Delphinids in general. In addition, a fourth, term *D. delphis* specimen (SBMNH 88-43A) was obtained from a beach cast adult that appeared to die while calving.

TABLE 1. Specimen and calculi data from common dolphins (*Delphinus delphis*) obtained by the Santa Barbara Museum of Natural History (SBMNH) and the Natural History Museum of Los Angeles County (NHMLAC).

Field number	Specimen			Calculi			Dimensions (mm)		
	Length (cm)	Weight (kg)	Ovarian condition	Number of calculi	Dry weight (g)	Description	Maximum length	Maximum width	Maximum thickness
75-45 (SBMNH)	177.0	72.0	12 corpora albicantia in left ovary	1	85.6	stone-like	70.1	55.6	33.4
76-45 (SBMNH)	176.0	66.4	1 corpus luteum 12 c. albicantia in left ovary	15	28.8	flat and rod-like	see Fig. 2B		
77-63 (SBMNH)	185.4	54.0	15 corpora albicantia in left ovary	1	194.9	stone-like	106.4	54.0	42.3
82-10 (SBMNH)	212.0	82.4	unknown	3	0.2	irregular fragments	14.3	6.0	2.5
							10.1	5.6	3.6
							9.7	8.5	3.5
84-26 (SBMNH)	180.0	54.0	unknown	1	1.8	plate-like	25.4	19.1	4.3
JEH-374 (NHMLAC)	181.5	68.2	unknown	1	357.6	stone-like	100.0	60.0	60.0

The specimen was studied using plain radiographs. Subsequently its skeleton was prepared and is catalogue number 3895 in the SBMNH vertebrate osteology collection. All four fetal specimens allowed us to approximately bracket the progress of ossification in the fetal dolphin skeleton as well as contribute to the limited amount of information on size at birth for the species.

RESULTS

Six dolphins salvaged between 1975 and 1989 bore calculi. All were adult specimens and were within the size range for sexual maturity to the extent size-maturity data are available for *D. delphis* (Kleinenberg, 1956; Nishiwaki, 1972; Perrin and Reilly, 1984). Table 1 provides specific information on each specimen. The calculi occur either as small, separate fragments or as single, large stones with concentric layers.

In the six cases that we report, all calculi were found distal to the pseudo-cervix (Fig. 1), and they exhibit a range in shape, size and number (Fig. 2A–D). The three stone-like calculi (solid concretions) bear impressions of the pseudo-cervix suggesting

the possibility of formation in this part of the reproductive tract. Their concentric rings resemble the crystallization mentioned by Sawyer and Walker (1977). The reproductive tract from specimen 75-45 illustrates the juxtaposition of a large calculus in the lower reproductive tract (Fig. 1).

In two cases where calculi occur as separate fragments, each reveals a thin layered deposit which tends to flake off easily. In another specimen, 82-10, the three small fragments show the porosities one observes in fractured or chipped bone, and they have no layered coating (Fig. 2D (upper)).

There are some interesting concomitants to these calculi. The calculi from specimen 76-45 show a degree of symmetry, and when layed out as shown, they reflect the ossified elements of a fetal skull (Fig. 2B). The premaxillary and maxillary bones of the rostrum are apparent as are elements of the occipital condyle, and portions of the exoccipitals. Another piece exhibits the inverted “U”-shape characteristic of the basioccipital.

Female 76-45, from which these cranial

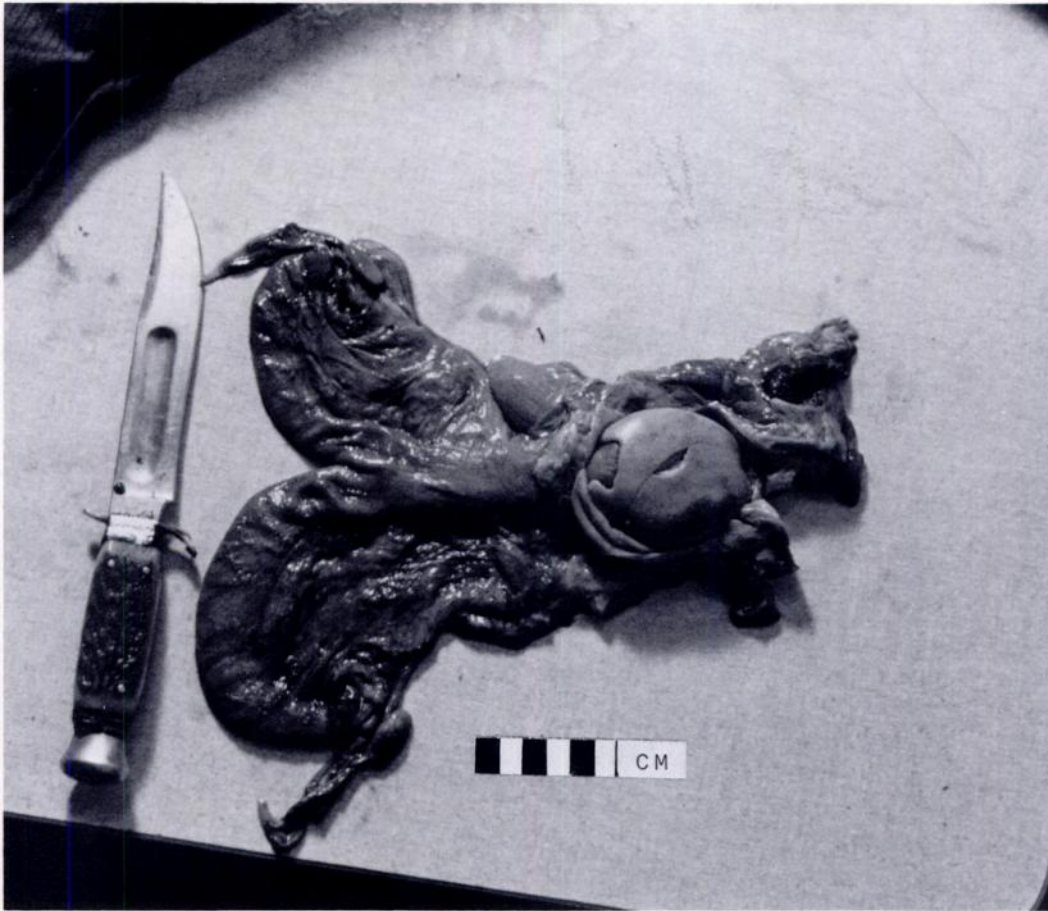


FIGURE 1. Vaginal calculus in *Delphinus delphis* (SBMNH 75-45) showing impression of distal surface of pseudocervix.

and rostral elements were recovered, was pregnant. The fetus was in the left uterine horn, measured 84.4 cm snout-notch (S-N), and weighed 5.6 kg. The calculi were abrading the vaginal epithelium but whether this occurred pre- or post-mortem could not be ascertained.

The calculus recovered by NHMLC (JEH-374), the largest single concretion, was associated with infected vaginal tissue. The reproductive tract was heavily infested with small cysts tentatively identified as the cestode *Monorygma* sp., and the broad ligament was notably congested with blood.

CAT scans of the fetuses provided a relative measure of ossification at various stages of development. The smallest fetus,

an 18.8 cm S-N, male *L. borealis*, showed no detectable ossification in the post cranial skeleton. Centers of early ossification were apparent in several places on the cranium: the occipital condyles, the midline of the supraoccipital and basioccipital, the otic capsules, the center of the basisphenoid and anterior portion of the presphenoid. Ossification was beginning in the exoccipitals. In the anterior portion of the head, centers of early ossification were noted in the pterygoid, posterior palatines, and the mandibles. Finally, centers of early ossification were evident right and left of the rostrum's midline incorporating portions of the palatine, premaxillary and mesial surface of maxillary bones, as well as the left and right sides of the vomer.

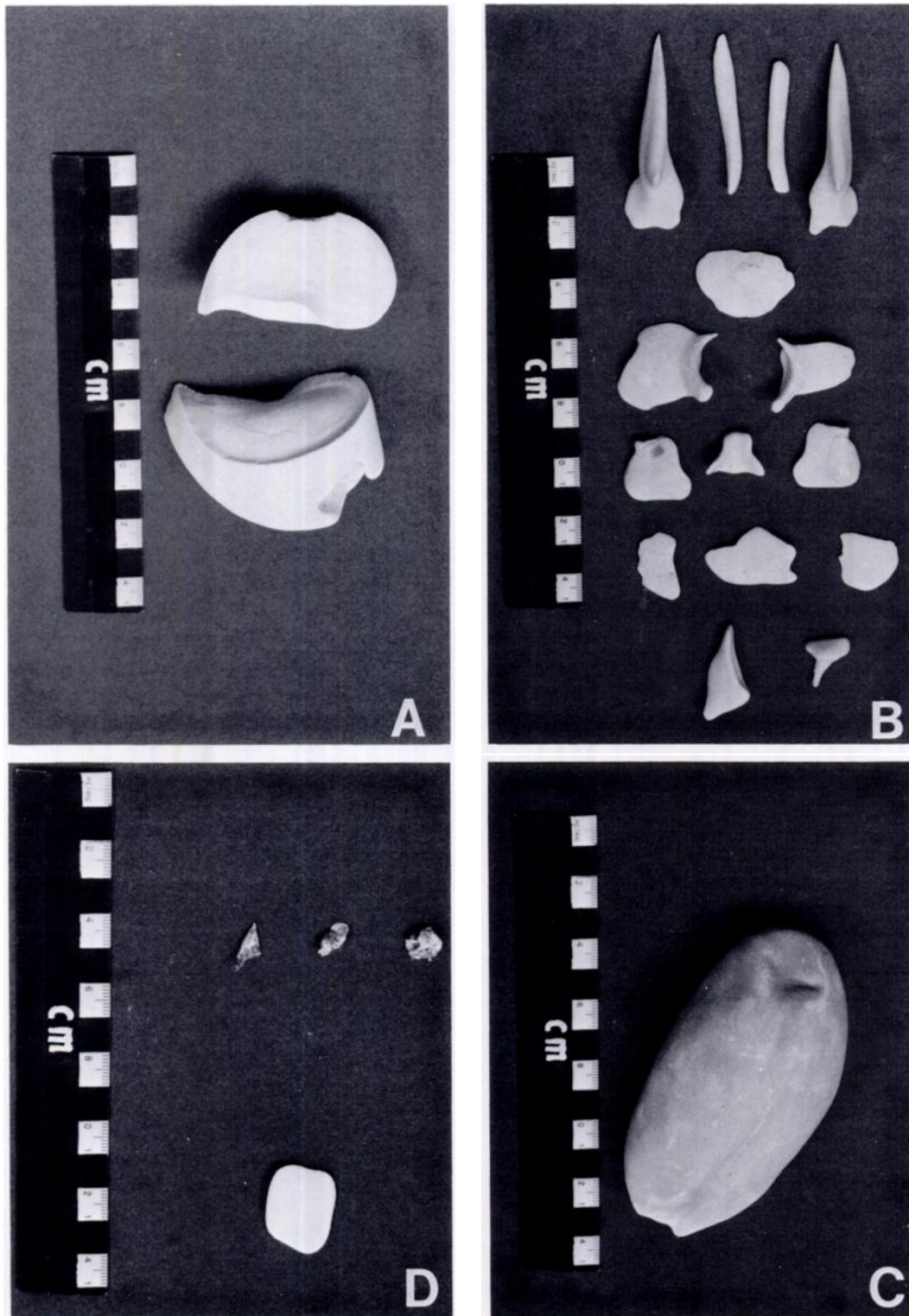


FIGURE 2. Vaginal calculi recovered from beach cast *Delphinus delphis* collected by SBMNH. A: single stone from specimen 75-45; B: apparent cranial fragments from specimen 76-45; C: single stone from specimen 77-63; D: (upper) irregular fragments from specimen 82-10; (lower) single plate-like fragment from specimen 84-26.

These centers appeared at the rostrum's proximal end and continued to be detectable about mid-way distally along its length, at which point they gradually diminished in degree of ossification until they appeared as two ossificatory foci on either side of the midline.

The near-term fetus (82-13A), a 91.0 cm S-N, female *D. delphis* showed considerably more ossification. Postcranial elements were ossified including ribs, vertebrae, scapulae, and elements of the pectoral skeleton. Elements of the cranium, rostrum, otic capsules and mandibles were strongly ossified with obvious suture lines between the major elements.

All elements of the 91.0 cm S-N, 7.65 kg term fetal skeleton (SBMNH 88-43A) showed signs of ossification, although the ribs were incompletely ossified. The pelvic bones appeared only slightly ossified.

Tissue samples taken from the vaginal wall, pseudo-cervix and true cervix of specimens with calculi were examined histologically and did not reveal evidence of unusual secretory activity.

DISCUSSION

The SBMNH sample of five females with calculi is drawn from a total of 16 females beach cast from 1975 through 1988. This 31% occurrence compares to a 40% occurrence reported from a sample of 10 *D. delphis* taken in a marine mammal salvage program from southern California during the years 1970 to 1973 (Cowan et al., 1986). The same authors report on a sample of six *Lagenorhynchus obliquidens* females, two of which contained vaginal calculi for a prevalence of 33%.

Sawyer and Walker (1977) established the similarity in chemistry between bone and vaginal calculi. In the series of samples gathered by the SBMNH study, there is a range from bone fragments exhibiting porosity but no coating to symmetrical fragments that are coated with thin layered deposits to large single stones exhibiting concentric layer crystallization. Benirschke et al. (1984) suggested that skel-

etal elements trapped in the vagina will crystallize and coalesce in time. The layered nature of the stone-like calculi and the manner in which they form an impression around the pseudo-cervix suggests formation in situ by deposition of calcium phosphate compounds.

By incorporating observations of previous authors with those presented here, one can demonstrate a range of calcular states. Some of the smaller calculi clearly represent fetal skeletal elements. This suggests that in some cases of fetal death, part or all of the fetus may lodge in the vagina. In time, decay may cause breakdown of non-ossified soft tissue including cartilage. The necrotic tissue is either expelled or in part redeposits on those bony elements which remain and, in turn, function as a nidus for "crystal" formation. Despite the lack of histological evidence for secretory activity in our tissue samples from the lower reproductive tract, the thin layered deposits on the individual fragments (Fig. 2B and 2D (bottom)) suggest that deposition of hard material nevertheless occurs. Other, unknown, mechanisms may favor calcium phosphate deposition, with the fetal skeletal element(s) again acting as a nidus.

The nature of the calculus(i) in each case will be a function of fetal development and residence time of the calcified fetal remains. It appears as though ossification of the fetal dolphin skeleton proceeds in a typical mammalian pattern. Hence, very young fetuses with little ossified skeleton may not be as likely to form calculi as second or third trimester fetuses. Larger stones are unlikely to represent the cementing together of smaller skeletal elements; were this so, one would expect to discern the skeletal parts in the larger calculus much like fossil bone embedded in rock. In our limited sample, this is not the case. Likewise, it is difficult to postulate a mechanism whereby smaller skeletal elements would fully coalesce. It is likely that large stones represent expulsion of all fetal elements from the vaginal tract save one, which then goes on to act as a nidus for

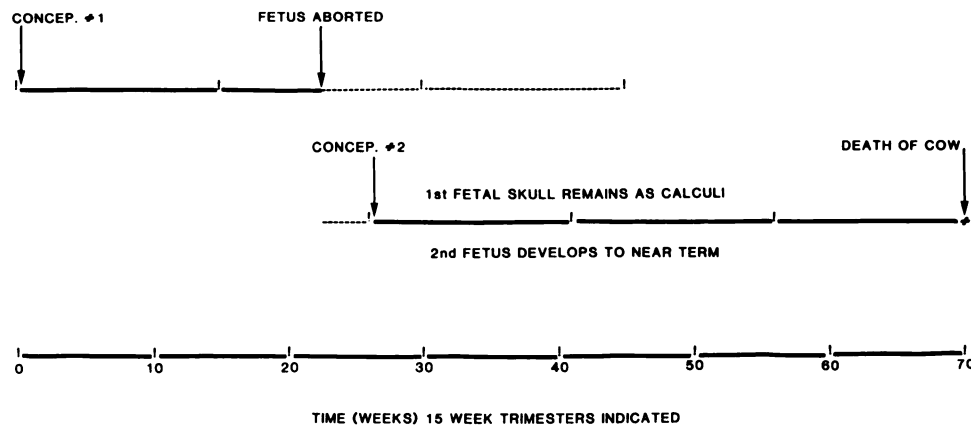


FIGURE 3. Estimation of minimal residence time for calculi of specimen 76-45. Length of rostral elements suggest a fetus aborted in second trimester. Gestation period is rounded for convenience of division into trimesters but is within the published range estimates for the species following Perrin and Reilly (1984).

calcium phosphate deposition for a protracted period of time.

Residence time of vaginal calculi remains a question. In two instances, vaginal calculi have been recovered from pregnant dolphins. Sawyer and Walker (1977) recovered three small (2.0 cm × 0.8 cm) calculi from a *D. delphis* with a 5.3 cm S-N fetus. We recovered an 84.4 cm S-N, 5.6 kg fetus from the specimen with calculi resembling fetal skull elements. In the latter case, since the fetus was near term, we have a preliminary measure of residence time and rate of crystallization of calculi (Fig. 3). Although we cannot ascertain the maximum time the calculi were in place, we can demonstrate an approximate minimal time from second conception by the cow to her death which is a span of approximately 43 wk. Over this period, the calculi exhibit signs of layered crystallization. We assume a 45 wk gestation period. This is within the range of values for *D. delphis* gestation (Perrin and Reilly, 1984), and was chosen for convenience of evenly dividing gestation into trimesters.

Finally, position of calculi in the lower reproductive tract appears to be variable. While no mention of precise position is made in the cases reported by Harrison (1969), Sawyer and Walker (1977) and Benirschke et al. (1984), Perrin and Donovan (1984) mention three cases of calculi con-

sisting of fetal bones, and in each instance, the calculi were located between the cervix and pseudo-cervix. In our sample, calculi were found in the vagina either closely associated with the pseudo-cervix or located more distally.

ACKNOWLEDGMENTS

The authors would like to thank John Heyning and the Natural History Museum of Los Angeles County for making their calculus specimen available to us. We appreciate the encouragement and suggestions of William A. Walker. The photographs in figure 2 were taken gratis by Mark Lewis of the Brook's Institute of Photography, Santa Barbara. We greatly appreciate the assistance of Chizuku Hara, Chief Histological Technician, Harbor-UCLA Medical Center, Los Angeles, California.

LITERATURE CITED

- BENIRSCHKE, K., J. R. HENDERSON, AND J. C. SWEENEY. 1984. A vaginal mass, containing fetal bones, in a common dolphin, *Delphinus delphis*. In Reproduction in whales, dolphins and porpoises, W. F. Perrin, R. L. Brownell, Jr., and D. P. DeMaster (eds.). Reports of the International Whaling Commission, Special Issue 6, Cambridge, United Kingdom, pp. 457-458.
- COWAN, D. F., W. A. WALKER, AND R. L. BROWNELL, JR. 1986. Pathology of small cetaceans stranded along southern California beaches. In Research on dolphins, M. M. Bryden and R. Harrison (eds.). Oxford University Press, Oxford, United Kingdom, pp. 323-367.
- HARRISON, R. J. 1969. Reproduction and reproductive organs. In The biology of marine mam-

- mals, H. T. Andersen (ed.). Academic Press, New York, New York, pp. 253–348.
- KLEINENBERG, S. E. 1956. Mlekopitauishchenie Chernogo i Azovskogo Morei. (Mammals of the Black Sea and the Sea of Azov). Akademiya Nauk, Moscow, 288 pp. (Translation series No. 4319, Fisheries and Marine Service, Quebec, 1978, 428 pp.)
- NISHIWAKI, M. 1972. General biology. *In* Mammals of the sea, biology and medicine, S. H. Ridgway (ed.). Charles C. Thomas, Publisher, Springfield, Illinois, pp. 3–204.
- PERRIN, W. F., AND G. P. DONOVAN. 1984. Report of the workshop. *In* Reproduction in whales, dolphins and porpoises, W. F. Perrin, R. L. Brownell, Jr., and D. P. DeMaster (eds.). Reports of the International Whaling Commission, Special Issue 6, Cambridge, United Kingdom, pp. 2–24.
- , AND S. B. REILLY. 1984. Reproductive parameters of dolphins and small whales of the family Delphinidae. *In* Reproduction in whales, dolphins and porpoises, W. F. Perrin, R. L. Brownell, Jr., and D. P. DeMaster (eds.). Reports of the International Whaling Commission, Special Issue 6, Cambridge, United Kingdom, pp. 97–133.
- SAWYER, J. E., AND W. A. WALKER. 1977. Vaginal calculi in the dolphin. *Journal of Wildlife Diseases* 13: 346–348.

Received for publication 29 May 1990.