

A Sarcocystis sp.-like Protozoan and Concurrent Canine Distemper Virus Infection Associated with Encephalitis in A Raccoon (*Procyon lotor*)

Authors: Stoffregen, D. A., and Dubey, J. P.

Source: Journal of Wildlife Diseases, 27(4) : 688-692

Published By: Wildlife Disease Association

URL: <https://doi.org/10.7589/0090-3558-27.4.688>

BioOne Complete (complete.BioOne.org) is a full-text database of 200 subscribed and open-access titles in the biological, ecological, and environmental sciences published by nonprofit societies, associations, museums, institutions, and presses.

Your use of this PDF, the BioOne Complete website, and all posted and associated content indicates your acceptance of BioOne's Terms of Use, available at www.bioone.org/terms-of-use.

Usage of BioOne Complete content is strictly limited to personal, educational, and non - commercial use. Commercial inquiries or rights and permissions requests should be directed to the individual publisher as copyright holder.

BioOne sees sustainable scholarly publishing as an inherently collaborative enterprise connecting authors, nonprofit publishers, academic institutions, research libraries, and research funders in the common goal of maximizing access to critical research.

A *Sarcocystis* sp.-like Protozoan and Concurrent Canine Distemper Virus Infection Associated with Encephalitis in A Raccoon (*Procyon lotor*)

D. A. Stoffregen¹ and J. P. Dubey,² ¹ Department of Pathology and New York State Diagnostic Laboratory, New York State College of Veterinary Medicine, Cornell University, Ithaca, New York 14850, USA; ² Zoonotic Diseases Laboratory, Livestock and Poultry Sciences Institute, Bldg. 1040, Barc-East, Beltsville, Maryland 20705, USA

ABSTRACT: A raccoon (*Procyon lotor*) with signs of weakness was captured in upstate New York (USA). Despite attempted care in a rehabilitation facility, the animal died and was examined because of suspected infectious neurologic disease. The cerebrum had a marked, locally extensive, neutrophilic, necrotizing encephalitis with numerous associated intralésional protozoal organisms, and a moderate to marked multifocal perivascular nonsuppurative meningoencephalitis. Based on morphology and immunohistochemical staining, the organism was a *Sarcocystis* sp.-like protozoan. Rabies antigen and canine distemper virus (CDV) inclusions were not detected. However, the animal was positive for canine distemper virus based on peroxidase anti-peroxidase staining.

Key words: *Sarcocystis* sp.-like protozoan, schizonts, raccoon, *Procyon lotor*, necrotizing encephalitis, canine distemper virus, case report.

Toxoplasma gondii and *Neospora caninum* are two apicomplexan protozoan parasites often associated with clinical encephalomyelitis in carnivores (Dubey and Beattie, 1988). Most cases of clinical toxoplasmosis in dogs, raccoons and foxes are associated with concurrent canine distemper virus infection (CDV). Alternatively, clinical neosporosis is often a primary pathogen in dogs (Dubey et al., 1988). Recently, a new *Sarcocystis* sp.-like protozoan parasite was found concurrently with CDV infection in a raccoon with encephalitis from Ohio (USA) (Dubey et al., 1990). We report a similar case in a raccoon from near Ithaca, New York (USA).

A mature, female raccoon was noted to be weak and wandering in a residential area in upstate New York (Tompkins County; 42°20'N, 76°20'W). At a wildlife rehabilitation facility the animal had a good appetite and grew stronger and more

active for several days. The raccoon then became depressed, had upper airway congestion, and subsequently developed seizures. It was euthanized with ether and submitted to the Necropsy Service of the New York State College of Veterinary Medicine (Cornell University, Ithaca, New York 14850, USA).

The raccoon weighed 3.55 kg and was in good nutritional condition. There was bilateral mucopurulent oculonasal discharge. No other gross abnormalities were noted. The presumptive diagnosis was canine distemper virus (CDV) infection. Specimens of liver, skeletal muscle, kidney, lung, small intestine, spleen, urinary bladder, colon, heart, pancreas, duodenum, jejunum, zygomatic gland, brainstem, cerebellum and cerebrum were fixed in 10% buffered neutral formalin, processed in a routine manner, embedded in paraffin, cut at 4 μ m and stained with hematoxylin and eosin.

Histologic examination revealed a marked, locally extensive, neutrophilic, necrotizing encephalitis with numerous intralésional protozoal organisms, and moderate to marked multifocal, perivascular, nonsuppurative meningoencephalitis with lesser number of eosinophils (Figs. 1, 2). Other findings included mild multifocal interstitial pneumonia, moderate multifocal nonsuppurative interstitial nephritis, and *Sarcocystis kirkpatricki* sarcocysts (Snyder et al., 1990) in skeletal and cardiac muscles. There were no CDV inclusion bodies noted in any tissues. A fluorescent antibody test for rabies virus (Trimarchi et al, 1991) on cerebrum, cerebellum, and brainstem was negative at the New York

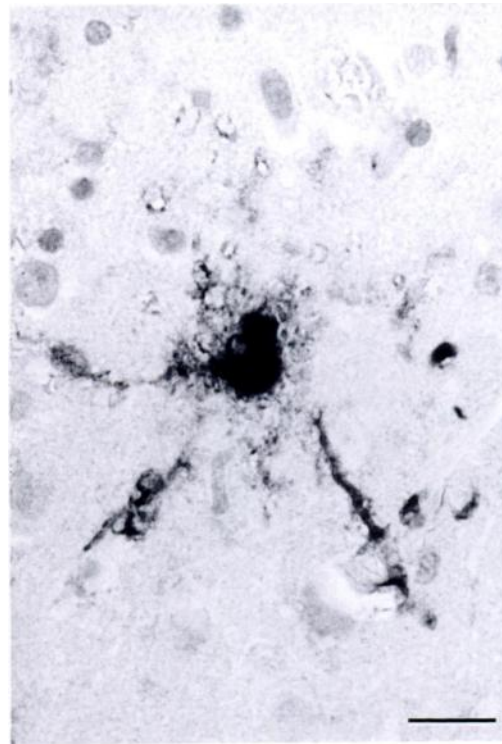
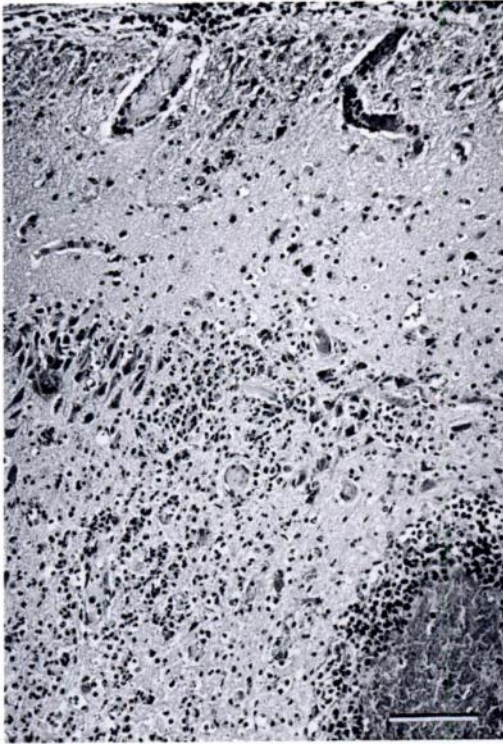
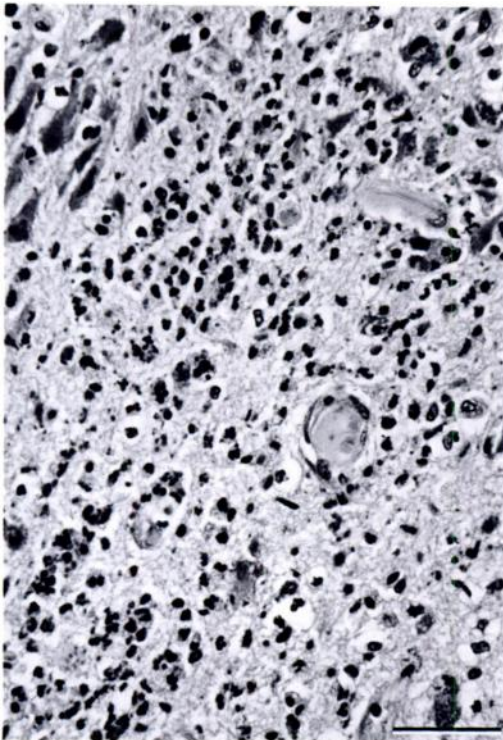


FIGURE 3. Astroglial cell stained with CDV monoclonal antibody in the lesion of a raccoon. Diaminobenzidine (DAB) chromagen and hematoxylin counterstain. Bar = 20 μm .



State Department of Health (Rabies Laboratory, Albany, New York 12201, USA). A peroxidase-antiperoxidase (PAP) immunohistochemical procedure (Sternberger, 1979) utilizing a monoclonal antibody to the NP protein of CDV (gift of Dr. C. Orvell, Stockholm, Sweden) on unstained 4 μm brain sections gave positive results, especially in corona radata and parahippocampal white matter, as well as mononuclear cells and fibroblasts in leptomen-

←

FIGURE 1. Marked multifocal to locally extensive encephalitis and moderate to marked multifocal perivascular nonsuppurative meningoencephalitis in the cerebral cortex of a raccoon. H&E. Bar = 100 μm .

FIGURE 2. Higher magnification showing the neutrophilic necrotizing inflammatory response to the *Sarcocystis* sp.-like organism in a raccoon. H&E Bar = 50 μm .

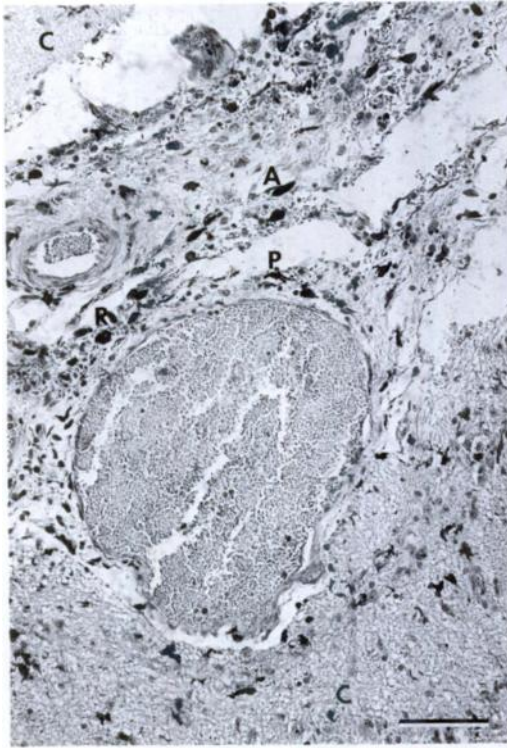


FIGURE 4. Meningeal fold between cortical gyri (C) of a raccoon. Note the stained round cells (R) and fibroblasts, both adventitial (A) and perivascular (P). DAB/hematoxylin. Bar = 100 μ m.

ingeal and perivascular adventitia (Figs. 3, 4); an irrelevant monoclonal antibody (ascitic fluid) was used as the negative control on the same tissue; both monoclonal antibodies were used at a 1:1,000 dilution. Diaminobenzidine (DAB) was the chromagen used and hematoxylin was the counterstain.

Within the cerebral malacic foci, protozoa were seen in neurons and in macrophages (Figs. 5, 6). The parasite divided by endopolygeny (Dubey et al., 1989). Uninucleated to fully developed schizonts were seen, sometimes in one field (Fig. 7). Merozoites were arranged haphazardly or in a rosette around a residual body. Merozoites were approximately $4 \times 1 \mu$ m. The organisms stained with *S. cruzi* antiserum but not with antisera against *T. gondii* and *N. caninum* in an immunohistochemical test (Lindsay and Dubey, 1989). The antisera were prepared in rabbits and appropriate

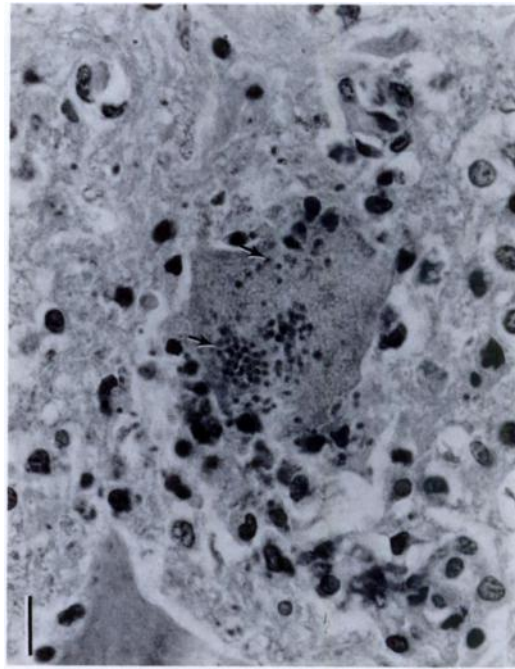


FIGURE 5. Numerous individual merozoites (arrows) of *Sarcocystis* sp.-like organism in a degenerating neuron of a raccoon. H&E. Bar = 10 μ m.

controls were included (Lindsay and Dubey, 1989; Dubey et al., 1990).

Based on morphologic and antigenic differences, the organism was not *T. gondii* or *N. caninum* because these pathogens divide by endodyogeny whereas the organism in our raccoon divide by endopolygeny. It is identical structurally with the *Sarcocystis*-like protozoan recently found in a raccoon from Ohio (Dubey et al., 1990) and to the organism (*S. neurona*) causing equine protozoal myeloencephalitis (Dubey et al., 1991).

The relative role of apicomplexan protozoa and CDV infection in the etiology of clinical encephalitis is not fully understood. Canine distemper virus is known to be immunosuppressive and has often been associated with canine, fox, and raccoon cerebral toxoplasmosis. The toxoplasmosis may result from reactivation of latent encysted bradyzoites.

A recent case of concurrent cerebral *Sarcocystis* sp.-like protozoal encephalitis and CDV infection in an Ohio raccoon

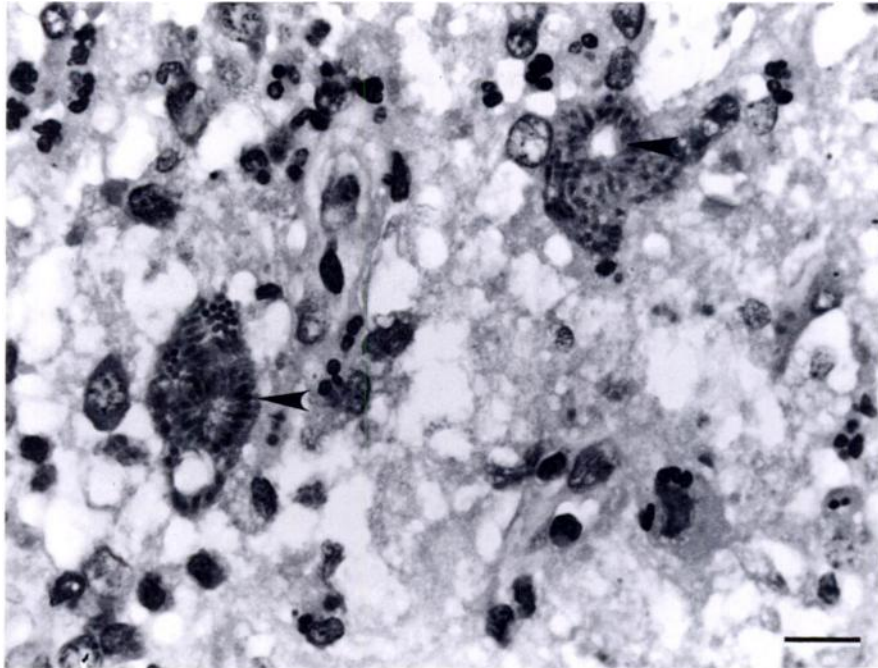


FIGURE 6. Several schizonts of a *Sarcocystis* sp.-like protozoan in a malacic area of a raccoon brain. Note the rosette arrangement of merozoites (arrows). H&E. Bar = 10 μ m.

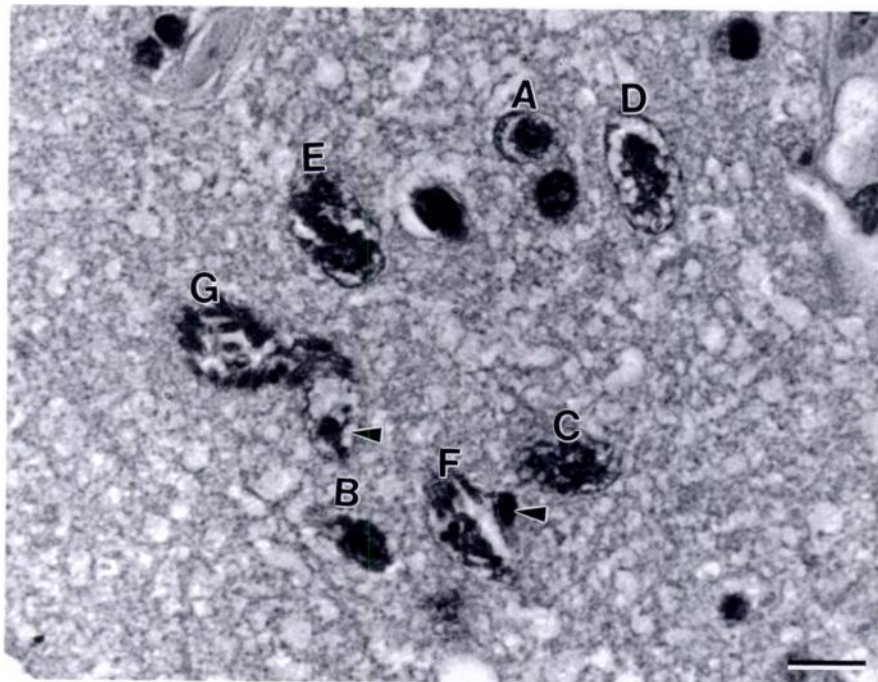


FIGURE 7. Seven schizonts (A to G) of a *Sarcocystis* sp.-like organism in presumed order of development. A is an uninucleate schizont with a prominent nucleolus and E is a schizont with a multilobulated nucleus. F and G are mature schizonts with merozoites. The host cell nucleus (arrowheads) is indented. H&E. Bar = 10 μ m.

(Dubey et al., 1990), followed by the same two infections in our raccoon, indicate a newly described coinfection, presently recognized only in the northeast United States of America. The central nervous system origin of these protozoal organisms is unknown, there being no recognized CNS cysts. The schizont is the only known stage of the raccoon parasite and *Sarcocystis neurona*. *Sarcocystis neurona* was recently cultured in vitro (Dubey et al., 1991) and attempts are underway to study its transmission and life cycle.

Canine Distemper Virus-induced immunosuppression may allow CNS-located apicomplexan protozoal organisms to flourish and ultimately lead to clinical encephalitis and death of the host.

LITERATURE CITED

- DUBEY, J. P., AND C. P. BEATTIE. 1988. Toxoplasmosis of animals and man. CRC Press, Boca Raton, Florida, 220 pp.
- , J. L. CARPENTER, C. A. SPEER, M. J. TOPPER, AND A. UGGLA. 1988. Newly recognized fatal protozoan disease of dogs. *Journal of the American Veterinary Medical Association* 192: 1269–1285.
- , S. W. DAVIS, C. A. SPEER, D. D. BOWMAN, A. DE LAHUNTA, D. E. GRANSTROM, M. J. TOPPER, A. N. HAMIR, J. F. CUMMINGS, AND M. M. SUTER. 1991. *Sarcocystis neurona* (Protozoa: Apicomplexa), the etiologic agent of equine protozoal myeloencephalitis. *The Journal of Parasitology* 77: 212–218.
- , A. N. HAMIR, C. A. HANLON, M. J. TOPPER, AND C. E. RUPPRECHT. 1990. Fatal necrotizing encephalitis in a raccoon associated with a *Sarcocystis*-like protozoon. *Journal of Veterinary Diagnostic Investigation* 2: 345–347.
- , C. A. SPEER, AND R. FAYER. 1989. *Sarcocystosis of animals and man*. CRC Press, Boca Raton, Florida, 215 pp.
- LINDSAY, D. S., AND J. P. DUBEY. 1989. Immunohistochemical diagnosis of *Neospora caninum* in tissue sections. *American Journal of Veterinary Research* 50: 1981–1983.
- SNYDER, D. E., G. C. SANDERSON, M. TOIVIO-KINNUCAN, AND B. L. BLAGBURN. 1990. *Sarcocystis kirkpatricki* n. sp. (Apicomplexa: Sarcocystidae) in muscles of raccoons (*Procyon lotor*) from Illinois. *The Journal of Parasitology* 76: 495–500.
- STERNBERGER, L. A. 1979. *Immunohistochemistry*, 2nd ed. John Wiley & Sons, New York, New York, 354 pp.
- TRIMARCHI, C. N., AND J. G. DEBBIE. 1991. The fluorescent antibody in rabies. In *The natural history of rabies*, Vol. 1, 2nd ed. CRC Press, Boca Raton, Florida. In press.

Received for publication 4 September 1990.