



Nasitrema sp.-associated Encephalitis in a Striped Dolphin (*Stenella coeruleoalba*) Stranded in the Gulf of Mexico

Authors: O'Shea, Thomas J., Homer, Bruce L., Greiner, Ellis C., and Layton, A. William

Source: Journal of Wildlife Diseases, 27(4) : 706-709

Published By: Wildlife Disease Association

URL: <https://doi.org/10.7589/0090-3558-27.4.706>

BioOne Complete (complete.BioOne.org) is a full-text database of 200 subscribed and open-access titles in the biological, ecological, and environmental sciences published by nonprofit societies, associations, museums, institutions, and presses.

Your use of this PDF, the BioOne Complete website, and all posted and associated content indicates your acceptance of BioOne's Terms of Use, available at www.bioone.org/terms-of-use.

Usage of BioOne Complete content is strictly limited to personal, educational, and non - commercial use. Commercial inquiries or rights and permissions requests should be directed to the individual publisher as copyright holder.

BioOne sees sustainable scholarly publishing as an inherently collaborative enterprise connecting authors, nonprofit publishers, academic institutions, research libraries, and research funders in the common goal of maximizing access to critical research.

***Nasitrema* sp.-associated Encephalitis in a Striped Dolphin (*Stenella coeruleoalba*) Stranded in the Gulf of Mexico**

Thomas J. O'Shea,¹ Bruce L. Homer,² Ellis C. Greiner,³ and A. William Layton,² ¹ U.S. Fish and Wildlife Service, National Ecology Research Center, Gainesville Field Station, 412 NE 16th Ave., Gainesville, Florida, 32601, USA; ² Department of Comparative and Experimental Pathology, College of Veterinary Medicine, Box J-145 JHMHC, University of Florida, Gainesville, Florida 32610, USA; ³ Department of Infectious Diseases, College of Veterinary Medicine, Box J-137 JHMHC, University of Florida, Gainesville, Florida 32610, USA

ABSTRACT: An immature female striped dolphin (*Stenella coeruleoalba*) found dead on a northwestern Florida beach in 1988 exhibited severe inflammation bilaterally in the dorsal and mid-thalamus in association with adult trematodes (*Nasitrema* sp.) and trematode eggs. Numerous specimens of *Nasitrema* sp. also were present in the pterygoid sinuses. Pneumonia in association with a heavy growth of *Vibrio damsela* was observed also. This report confirms the occurrence of *Nasitrema* sp.-associated encephalitis in striped dolphins and in small cetaceans from the Gulf of Mexico.

Key words: Brain, case history, encephalitis, *Nasitrema* sp., pathology, *Stenella coeruleoalba*, striped dolphin, *Vibrio*.

Brain lesions produced by parasitic trematodes of the genus *Nasitrema* have been implicated as a cause of death in single strandings of small cetaceans along the Pacific coast of North America (Parker et al., 1977; Dailey and Walker, 1978; Cowan et al., 1986; Lewis and Berry, 1988). *Nasitrema* sp.-associated encephalitis has not been confirmed for striped dolphins (*Stenella coeruleoalba*) and is not well known in marine mammals from the Gulf of Mexico. In this report we implicate brain lesions associated with *Nasitrema* sp. as a major factor in the death of a striped dolphin from northwestern Florida.

An immature female was found dead at Panama City Beach (30°10'50"N, 85°49'05"W) on 8 November 1988. Time since death was unknown, but little decomposition was evident. The carcass was kept under ice during transport to the University of Florida College of Veterinary Medicine (Gainesville, Florida 32610, USA), where a necropsy was conducted about 24 hr later. Weight was 53.5 kg. Total length was 173 cm. The most sig-

nificant gross findings were related to trematode infection. We counted 43 trematodes (*Nasitrema* sp.) in the right pterygoid sinus and 71 in the left. The mucosa had multiple erosions associated with attachment of the trematodes. A single *Nasitrema* sp. was noted in the trachea.

The brain was removed and immersed in 10% neutral buffered formalin. Serial coronal sections of the fixed brain revealed multiple 0.5 to 2.0 cm diameter, irregularly shaped brown cavitated areas of necrosis in the right and left dorsal to mid-thalamic regions and parietal cortices (Fig. 1). Cavitated areas contained several 0.5 × 0.25 cm flattened fragments of trematodes identified as *Nasitrema* sp. The left dorsal thalamus also contained dark brown, interlacing streaks. Lungs were meaty (weight 1.8 kg) and were mottled red, purple and tan with reddened cut surfaces. A moderate ulcerative gastritis was present in the pylorus. Other organs had parasitic or incidental lesions at gross necropsy.

Tissues were fixed in 10% neutral buffered formalin, embedded in paraffin, thin sectioned at 6 μm, stained with hematoxylin and eosin, and examined with light microscopy. The most significant microscopic lesions were present in the brain. Areas of cavitated brain contained large cystic foci of liquefactive necrosis bordered by diffuse infiltrates of macrophages with fewer hemosiderophages, clusters of lymphocytes and scattered multinucleated giant cells (Figs. 2, 3). Many glial cells were present. Sections of *Nasitrema* sp. were characterized by a thin tegument with segmental spine-covered areas, an acetabulum, an oral sucker, and absence of a coe-

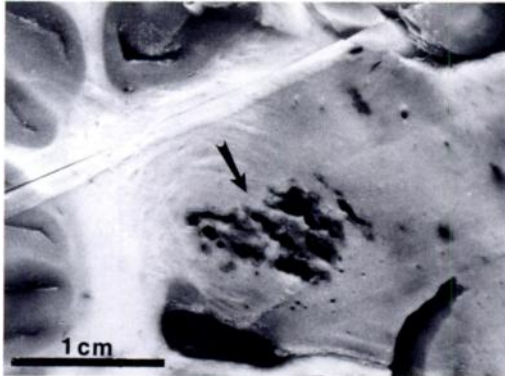


FIGURE 1. Irregular cavitated area (arrow) in the right dorsal thalamus of a striped dolphin. Lateral ventricle is below this area in the figure. The crevice on the bottom right is an artifact. Formalin-fixed gross specimen.

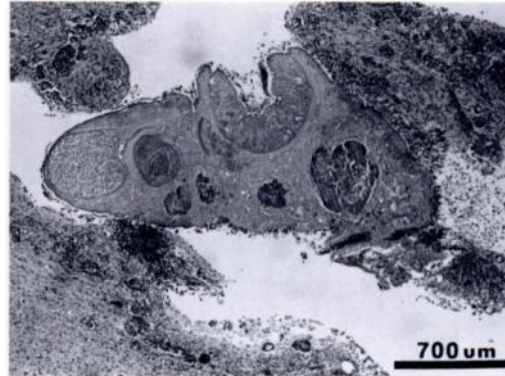

FIGURE 2. Section through a cavitated area of a striped dolphin brain containing a *Nasitrema* sp. trematode. The surrounding neuropil is hypercellular due to infiltrates of macrophages and lymphocytes, and increased numbers of glial cells. H&E.

lom (Fig. 2). Most internal structures were indistinct (because of necrosis) and much of the tegument was covered by macrophages and multinucleated giant cells. There were also numerous oval or triangular eggs (60 to 80 μm the long axis) with an approximately 6 to 8 μm wide refractile, slightly birefringent golden brown wall (Fig. 3). A single operculum was sometimes identified. Most eggs were fractured and/or distorted and many were partially encompassed by multinucleated giant cells. Capillaries within the lesion were hyperplastic and had degenerate (basophilic) walls. Scarred areas of brain contained proliferations of fibrous astrocytes. The surrounding parenchyma contained numerous vacuoles, increased numbers of glial cells, and scattered swollen axons.

Other significant microscopic alterations included a chronic hyperplastic pterygoid sinusitis associated with trematode eggs in the underlying stroma, as described in the brain. The lungs had a subacute, moderate, multifocal bronchointerstitial pneumonia. Trematode (not identified, but morphologically distinct from *Nasitrema* sp.)-associated pancreatitis and periportal hepatitis were present also.

Bacteriological studies yielded heavy growth of a pure isolate of *Vibrio damsela* from a section of lung obtained aseptically

at necropsy. Recovery and identification of the microorganism followed standardized laboratory protocol. The lung sample was minced, and planted on a Columbia agar plate with 5% sheep blood, a MacConkey plate, and a Columbia CNA (colistin nalidixic acid) agar plate with 5% sheep blood. After a 24-hr incubation period at 35 C with 5% CO_2 , the plates were evaluated and it was determined that the only growth was an oxidase-positive, Gram-negative, non-enteric, slightly curved rod. Further identification was pursued using an API rapid NFT identification system. This system is designed to classify non-fermentative organisms and some fermenters not belonging to the Enterobacteriaceae, such as the vibrios.

The presence of adult *Nasitrema* sp. or *Nasitrema* sp.-like eggs in association with lesions in the brain has been reported for common dolphins (*Delphinus delphis*), Pacific white-sided dolphins (*Lagenorhynchus obliquidens*), Dall's porpoises (*Phocoenoides dalli*), and northern right whale dolphins (*Lissodelphis borealis*), all from the Pacific coast of North America (Parker et al., 1977; Dailey and Walker, 1978; Cowan et al., 1986; Lewis and Berry, 1988). Forrester (1991) reviewed four unpublished case reports from the files of The University of Florida College of Veteri-

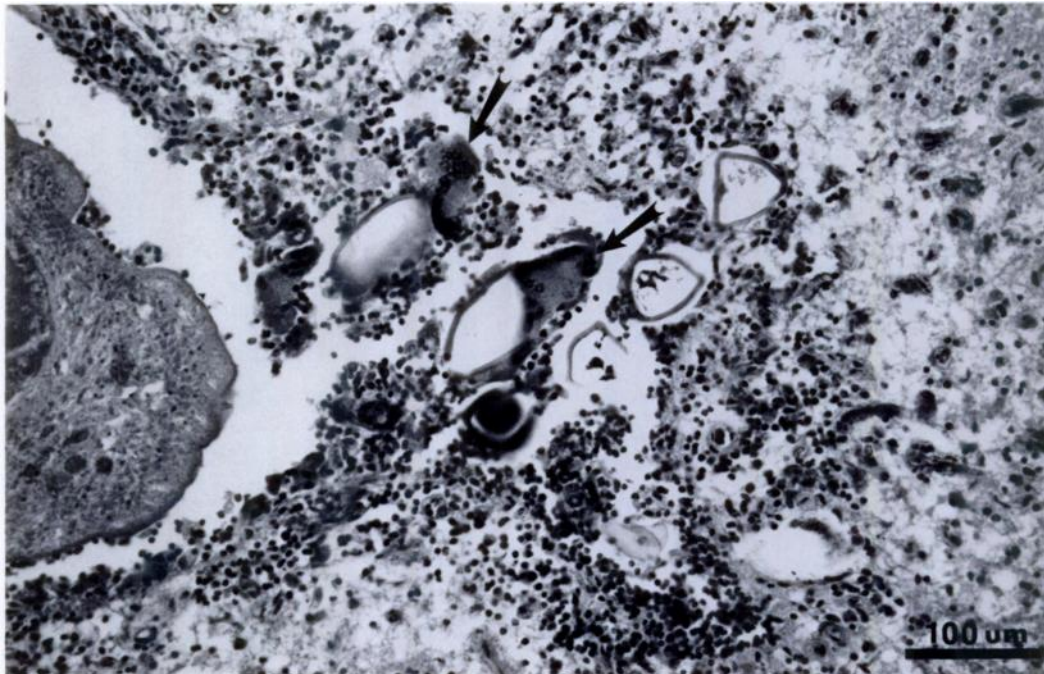


FIGURE 3. Fractured and distorted triangular and oval trematode eggs surrounded by infiltrates of macrophages, lymphocytes, multinucleated giant cells (arrows), and increased numbers of glial cells within a striped dolphin brain. Part of a *Nasitrema* can be seen adjacent to this area. H&E.

nary Medicine which also indicate the occurrence of trematode-associated encephalitis in small cetaceans from the Gulf of Mexico. These reports were based on strandings of one striped dolphin, one rough-toothed dolphin (*Steno bredanensis*), and two pantropical spotted dolphins (*Stenella attenuata*). Strandings occurred between 1980 and 1985 on northwestern Florida beaches within 150 km of the 1988 striped dolphin stranding. Associated pathology was similar to the case reported above. Numerous trematode eggs were noted, but only one intact adult was observed microscopically. It appeared morphologically similar to *Nasitrema*, but its identification was not confirmed (Forrester, 1991). Encephalitis associated with *Campula* sp. has been reported in small cetaceans, but the diagnosis of *Campula* sp. was based on the morphology of the eggs in the brain (Ridgway and Dailey, 1972; Sweeney and Ridgway, 1975). However, it is now recognized that the eggs of

both *Nasitrema* sp. and *Campula* sp. are similar morphologically, and when adult trematodes have been found in the brains of cetaceans only *Nasitrema* sp. has been identified (Parker et al., 1977; Howard et al., 1983).

Nasitrema sp.-associated lesions have been suggested to be a cause of strandings and deaths of some small cetaceans from the Pacific coast. However, it has not always been clear whether the trematode infection in the brain also debilitated the animal, leading to death from some secondary cause, or other events weakened the animals and allowed the parasites to invade the brain (Cowan et al., 1986). Both scenarios are possible, and generalizations beyond each specific case are inappropriate. *Nasitrema* sp. normally reside in the air sinuses of small cetaceans. Cowan et al. (1986) suggested that aberrant migration of *Nasitrema* occurs directly from the air sinus-inner ear complex to the subdural space and that this migration is due to

other complicating factors that disturb the host-parasite relationship. In contrast to findings in stranded individuals, many clinically normal small cetaceans taken in fishing nets have a high prevalence of *Nasitrema* sp. infection in the sinuses without the presence of adults or eggs in the brain (Dailey and Walker, 1978; Cowan et al., 1986). In addition to encephalitis, the female striped dolphin we examined also had a subacute pneumonia, which was less chronic than the encephalitis, indicating that the pneumonia developed after the onset of encephalitis. *Vibrio damsela* was the only bacterium isolated from the lung, and we speculate that it is likely to have been the cause of the pneumonia. This organism has apparently not been reported previously in association with pneumonia in striped dolphins, although other species of *Vibrio* have been isolated from tissues of four other species of cetaceans (Dailey, 1985). *Vibrio damsela* is a common bacterium in Gulf waters and its presence is normally non-pathogenic. However, it has also been reported to be a primary pathogen causing infections of wounds in bottlenose dolphins, *Tursiops truncatus* (Fujioka et al., 1988). In this particular case severity and duration of lesions suggest that the encephalitis resulted in debilitation of the striped dolphin, which in turn resulted in pneumonia, seemingly due to a *Vibrio damsela* infection. Both the encephalitis and pneumonia contributed to the cause of death.

Personnel of the Gulf World aquarium in Panama City notified us of the stranding. J. Gore, Florida Game and Fresh Water Fish Commission, expedited transfer of the carcass. C. Beck and R. Bonde provided critical assistance at necropsy. R. Appy verified the identification of *Nasitrema*. B. Purich, University of Florida

Veterinary Medical Teaching Hospital, interpreted microbiological results. D. Forrester and C. Beck reviewed the manuscript. The dolphin was recovered through the Southeastern U.S. Marine Mammal Stranding Network, under authorization of the National Marine Fisheries Service.

LITERATURE CITED

- COWAN, D. F., W. A. WALKER, AND R. L. BROWNELL, JR. 1986. Pathology of small cetaceans stranded along southern California beaches. *In* Research on dolphins, M. M. Bryden and R. Harrison (eds.). Oxford University Press, Oxford, England, pp. 323-367.
- DAILEY, M. D. 1985. Diseases of Mammalia: Cetacea. *In* Diseases of marine animals, Vol. IV, Part 2, O. Kinne (ed.). Biologische Anstalt Helgoland, Hamburg, Germany, pp. 805-847.
- , AND W. A. WALKER. 1978. Parasitism as a factor (?) in single strandings of southern Californian cetaceans. *The Journal of Parasitology* 64: 593-596.
- FORRESTER, D. J. 1991. Parasites and diseases of wild mammals in Florida. University of Florida Press, Gainesville, Florida. In press.
- FUJIOKA, R. S., S. B. GRECO, M. B. CATES, AND J. P. SCHROEDER. 1988. *Vibrio damsela* from wounds in bottlenose dolphins *Tursiops truncatus*. *Diseases of Aquatic Organisms* 4: 1-8.
- HOWARD, E. B., J. O. BRITT, AND G. MATSUMOTO. 1983. Parasitic diseases. *In* Pathobiology of marine mammals, Vol. 1, E. B. Howard (ed.). CRC Press, Boca Raton, Florida, pp. 119-232.
- LEWIS, R. J., AND K. BERRY. 1988. Brain lesions in a Pacific white-sided dolphin (*Lagenorhynchus obliquidens*). *Journal of Wildlife Diseases* 24: 577-581.
- PARKER, G. A., G. MIGAKI, AND W. A. WALKER. 1977. Cerebral trematodiasis in a dolphin. *Military Medicine* 142: 861-871.
- RIDGWAY, S. H., AND M. D. DAILEY. 1972. Cerebral and cerebellar involvement of trematode parasites in dolphins and their possible role in strandings. *Journal of Wildlife Diseases* 8: 33-43.
- SWEENEY, J. C., AND S. H. RIDGWAY. 1975. Common diseases of small cetaceans. *Journal of the American Veterinary Medical Association* 167: 533-540.

Received for publication 25 February 1991.