



## **Concomitant Cryptosporidia, Coronavirus and Parvovirus Infection in a Raccoon (*Procyon lotor*)**

Authors: Martin, H. D., and Zeidner, N. S.

Source: Journal of Wildlife Diseases, 28(1) : 113-115

Published By: Wildlife Disease Association

URL: <https://doi.org/10.7589/0090-3558-28.1.113>

---

BioOne Complete ([complete.BioOne.org](https://complete.BioOne.org)) is a full-text database of 200 subscribed and open-access titles in the biological, ecological, and environmental sciences published by nonprofit societies, associations, museums, institutions, and presses.

Your use of this PDF, the BioOne Complete website, and all posted and associated content indicates your acceptance of BioOne's Terms of Use, available at [www.bioone.org/terms-of-use](https://www.bioone.org/terms-of-use).

Usage of BioOne Complete content is strictly limited to personal, educational, and non - commercial use. Commercial inquiries or rights and permissions requests should be directed to the individual publisher as copyright holder.

---

BioOne sees sustainable scholarly publishing as an inherently collaborative enterprise connecting authors, nonprofit publishers, academic institutions, research libraries, and research funders in the common goal of maximizing access to critical research.

## Concomitant Cryptosporidia, Coronavirus and Parvovirus Infection in a Raccoon (*Procyon lotor*)

H. D. Martin<sup>1</sup> and N. S. Zeidner,<sup>2</sup> <sup>1</sup> Department of Clinical Sciences and <sup>2</sup> Department of Pathology, College of Veterinary Medicine and Biomedical Sciences, Colorado State University, Fort Collins, Colorado 80523, USA

**ABSTRACT:** A juvenile raccoon (*Procyon lotor*) was found moribund near Fort Collins, Colorado (USA). Upon examination, the raccoon was dehydrated, had a mucopurulent oculonasal discharge and diarrhea, and was euthanized. Post-mortem examination revealed emaciation, severe fibrinous gastroenteritis and a small, firm liver. Histopathological findings included blunting of villi, infiltration of lamina propria with neutrophils and plasma cells, and mild bronchopneumonia. *Cryptosporidium* sp. was demonstrated on intestinal villi and coronavirus and parvovirus were identified in feces. Fluorescent antibody test for rabies was negative and no evidence of canine distemper was found.

**Key words:** Raccoon, *Procyon lotor*, *Cryptosporidium* sp., coronavirus, parvovirus, gastroenteritis, case report.

Gastroenteritis has been documented in wild and captive raccoon populations (Nettles et al., 1980; Walker, 1940), and a parvovirus has been isolated (Nettles et al., 1980). Raccoon parvovirus causes mortality in raccoons, particularly juveniles (Budd, 1982). Other important infectious causes of mortality include canine distemper and rabies viruses (Budd, 1982). Coronavirus infection has not been reported previously in raccoons and cryptosporidial infection has been found only incidentally in an apparently healthy animal (Carlson and Nielson, 1982). Both agents have been documented as pathogens in domestic dogs, coyotes and cats (Current, 1985; Foreyt, 1985).

In spring 1988, a juvenile raccoon, estimated to be from 6- to 12-mo-old was presented to the Colorado State University Veterinary Teaching Hospital (Fort Collins, Colorado 80523, USA) in a moribund condition. It had been found alongside a creek in Fort Collins, Colorado (41°00'N, 105°00'W). The animal was emaciated and approximately 10% dehydrated, with diarrhea on the rear legs and anus, and a

mucoid oculonasal discharge. The raccoon was euthanized with injectable barbiturate solution. Gross necropsy findings included emaciation and fibrinous gastroenteritis involving approximately 90% of the small intestine. Brain was negative for rabies by fluorescent antibody test. Microscopically, there was mild bronchopneumonia, with coalescent areas of pulmonary edema, and diffuse blunting and fusion of intestinal villi, and infiltration of lamina propria with neutrophils and plasma cells in small intestine (Fig. 1). Round to ovoid, approximately 2 to 7  $\mu$ m in diameter protozoa were identified on intact villi, often in association with adherent bacilli (Fig. 2). Electron microscopy demonstrated both coronavirus and parvovirus in feces. No evidence of canine distemper was found in lung or nervous tissue examined. Although the cause of clinical disease is difficult to ascribe to any one agent, cryptosporidia, coronavirus and parvovirus may have all played significant roles.

Cryptosporidia have been demonstrated in a wide range host species, including reptiles, carnivores and bovids (Current, 1985), and may cause malabsorption, maldigestion and diarrhea. In dogs and cats terminal portions of the small intestine are the primary site of infection, leading to chronic intermittent diarrhea and weight loss. In a previous report, organisms were attached to blunted villi, with infiltration of lamina propria by eosinophils and mononuclear cells (Carlson and Nielson, 1982). However, no clinical disease was seen.

Coronaviruses commonly cause gastroenteritis in swine, dogs, cats and bovids and have been implicated as a pathogen in wild coyote populations (Evermann et al., 1980). Infections are usually self-limiting but may be fatal in young animals

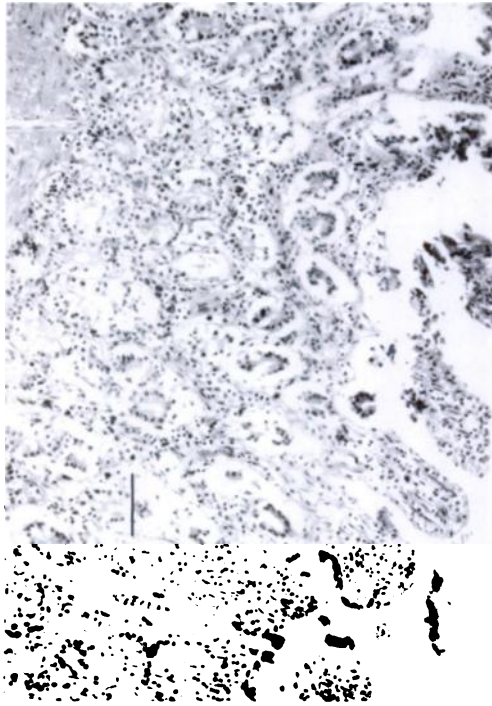


FIGURE 1. Diffuse blunting and fusion of intestinal villi and a moderate infiltration of the lamina propria with neutrophils and plasma cells. Bar = 50  $\mu$ m.

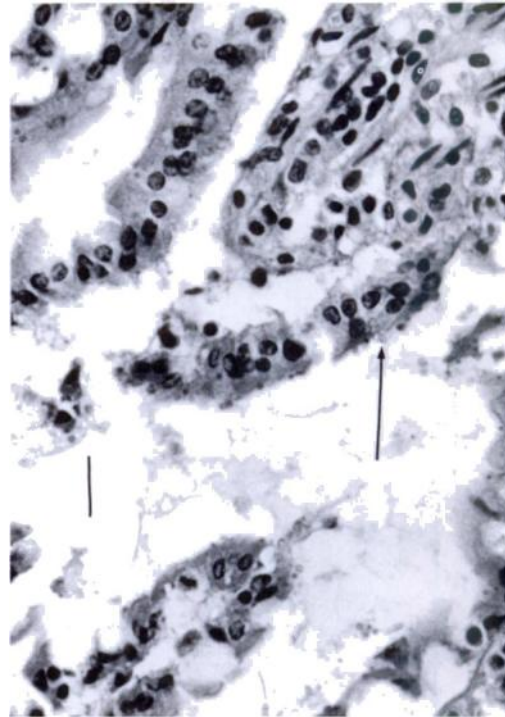


FIGURE 2. Intestinal epithelium showing round protozoa 2 to 7  $\mu$ m in diameter (arrow), attached to the brush border of intact epithelium. Bar = 20  $\mu$ m.

(Evermann et al., 1980). The jejunum is the preferential site of infection. Histopathologic findings in dogs include atrophy and fusion of villi, deepening of crypts and inflammatory infiltration of the lamina propriae. Canine coronavirus is often seen in combination with canine parvovirus infection. In domestic cats, two variants of coronavirus are identified; one resulting in feline infectious peritonitis, the other in an enteric form associated with diarrhea in kittens.

Parvoviruses have been documented as a common cause of severe diarrheal disease in domestic dogs, raccoons, mink, nondomestic canids, and felids (Mann et al., 1980; Nettles et al., 1980). Diarrhea is usually severe and often hemorrhagic, with sloughing of intestinal mucosa and replacement by cuboidal epithelium. Wild populations of raccoons have been found to be affected by parvoviruses (Nettles et

al., 1980; Walker, 1940). The raccoon parvovirus seems more closely related to the feline form rather than the canine parvovirus (Appel and Parrish, 1982).

In this case, parvovirus and coronavirus may have acted synergistically to cause disease, along with the cryptosporidia, which is most often a secondary invader (Current, 1985). Cryptosporidiosis frequently occurs concurrently with *Escherichia coli*, rotavirus and coronavirus in neonatal ruminants. This case demonstrates coronavirus and cryptosporidia as potential causes of disease in raccoons.

#### LITERATURE CITED

- APPEL, M. J. G., AND C. R. PARRISH. 1982. Raccoons are not susceptible to canine parvovirus. *Journal of the American Veterinary Medical Association* 181: 489.
- BUDD, J. 1982. Distemper. *In Infectious diseases of wild mammals*, 2nd ed., J. W. Davis, L. H. Kar-

- stad, and D. O. Trainer (eds.). Iowa State University Press, Ames, Iowa, pp. 31-44.
- CARLSON, B. S., AND S. W. NIELSON. 1982. Cryptosporidiosis in a raccoon. *Journal of the American Veterinary Medical Association* 181: 11.
- CURRENT, W. L. 1985. Cryptosporidiosis. *Journal of the American Veterinary Medical Association* 187: 1334-1338.
- EVERMANN, J. F., W. FOREYT, L. MAAG-MILLER, C. W. LEATHERS, A. J. MCKEIRNAN, AND B. LEA MASTER. 1980. Acute hemorrhage enteritis associated with canine coronavirus and parvovirus infections in a captive coyote population. *Journal of the American Veterinary Medical Association* 177(9): 784-786.
- FOREYT, W. J. 1985. Serologic survey of canine coronavirus in wild coyotes in the Western U.S. 1972-82. *Journal of Wildlife Diseases* 21: 428-430.
- MANN, P. C. et al. 1980. Canine parvovirus infection in South American canids. *Journal of the American Veterinary Medical Association* 177: 779-780.
- NETTLES, V. F., J. E. PEARSON, G. A. GUSTAFSON, AND J. L. BLUE. 1980. Parvovirus infection in translocated raccoons. *Journal of the American Veterinary Medical Association* 177: 787-789.
- WALKER, E. F. 1940. Infectious gastroenteritis in raccoons. *Journal of the American Veterinary Medical Association* 96: 266-269.

*Received for publication 21 August 1990.*