

PARATUBERCULOSIS IN SAIGA ANTELOPE (SAIGA TATARICA) AND EXPERIMENTAL TRANSMISSION TO DOMESTIC SHEEP

Authors: Dukes, Thomas W., Glover, Gordon J., Brooks, Brian W., Duncan, J. Robert, and Swendrowski, Mark

Source: Journal of Wildlife Diseases, 28(2) : 161-170

Published By: Wildlife Disease Association

URL: <https://doi.org/10.7589/0090-3558-28.2.161>

BioOne Complete (complete.BioOne.org) is a full-text database of 200 subscribed and open-access titles in the biological, ecological, and environmental sciences published by nonprofit societies, associations, museums, institutions, and presses.

Your use of this PDF, the BioOne Complete website, and all posted and associated content indicates your acceptance of BioOne's Terms of Use, available at www.bioone.org/terms-of-use.

Usage of BioOne Complete content is strictly limited to personal, educational, and non - commercial use. Commercial inquiries or rights and permissions requests should be directed to the individual publisher as copyright holder.

BioOne sees sustainable scholarly publishing as an inherently collaborative enterprise connecting authors, nonprofit publishers, academic institutions, research libraries, and research funders in the common goal of maximizing access to critical research.

PARATUBERCULOSIS IN SAIGA ANTELOPE (*SAIGA TATARICA*) AND EXPERIMENTAL TRANSMISSION TO DOMESTIC SHEEP

Thomas W. Dukes,¹ Gordon J. Glover,² Brian W. Brooks,¹ J. Robert Duncan,¹ and Mark Swendrowski³

¹ Agriculture Canada, Animal Diseases Research Institute, P.O. Box 11300, Station H, Nepean, Ontario, Canada K2H 8P9

² Veterinarian, Assiniboine Park Zoo, 2355 Corydon Ave., Winnipeg, Manitoba, Canada R3P 0R5

³ Veterinary Services Laboratory, Manitoba Dept. Agriculture, Agricultural Services Complex, 545 University Crescent, Winnipeg, Manitoba, Canada R3T 2N2

ABSTRACT: *Mycobacterium paratuberculosis* was isolated in low numbers from the small intestine and associated mesenteric lymph nodes of a saiga antelope (*Saiga tatarica*) using routine culture techniques in spite of histologic evidence of high numbers of acid-fast bacteria in these tissues. Two newborn domestic sheep were fed the ground intestinal tissue containing acid-fast bacteria and the progression of the experimental disease was followed by fecal culture, immunodiffusion (AGID) and lymphocyte stimulation (LST) tests. One experimentally infected sheep developed progressive clinical illness 1 yr postinoculation. Few *M. paratuberculosis* were isolated from feces or tissues although an extensive granulomatous mycobacterial enteritis, lymphadenitis and lymphangitis were observed containing large numbers of typical acid-fast organisms. No clinical illness was observed in the second inoculated sheep after 18 mo of observation, although infection was demonstrated at necropsy. Both sheep developed AGID and LST reactions indicative of paratuberculosis. This study demonstrated that a difficult to culture isolate of *M. paratuberculosis* was responsible for paratuberculosis in captive wild ruminants and was transmissible to domestic sheep. Diagnosis of paratuberculosis in four of eight of the imported saiga antelope and in eleven of their 18 offspring indicates the importance of this disease in management of captive wild ruminants and the ease with which this organism can be transmitted.

Key words: Paratuberculosis, saiga antelope, transmission, sheep, *Saiga tatarica*, natural infection.

INTRODUCTION

While paratuberculosis (Johne's disease) is primarily a disease of domestic ruminants (Katic, 1969) of the family Bovidae, it has also been observed in free-ranging and captive wild ruminants (Baradel et al., 1988; Commichau, 1982; Chiodini and van Kruiningen, 1983; Weber, 1980, 1982; Williams et al., 1979, 1983a, b) of the families Cervidae, Camelidae, and Bovidae (Katic, 1961). This paper reports paratuberculosis in saiga antelope (*Saiga tatarica*: Bovidae) imported to a zoo in Canada. In comparison to the disease in cattle, there was difficulty in isolation of the causative agent and clinical disease was frequently expressed in relatively young animals. To investigate the poor cultural recovery of the organism and possible strain variation in virulence for different animal species, material from one antelope was inoculated into newborn domestic sheep.

MATERIALS AND METHODS

Paratuberculosis in imported saiga antelope

Sixteen saiga antelope were imported into Canada in 1985 from a zoo in Germany. These animals had been negative on previous export testing for paratuberculosis in the country of origin. Serum was collected during quarantine for paratuberculosis testing in addition to other federal import test requirements. Two animals died in quarantine, two male and six female antelope were sent to the Assiniboine Park Zoo (Winnipeg, Manitoba, Canada R3P 0R5) where they were housed in a newly constructed exhibit area and six animals were sent to another facility in Canada for which no further information is available. Necropsies were performed at the Manitoba Veterinary Services Laboratory, Winnipeg, on all saiga antelope which were euthanized or died at the Assiniboine Park Zoo beginning 6 mo after the animals arrived. The lower small intestine and associated lymph nodes were examined. Histologic sections were stained by hematoxylin and eosin and by Kinyoun's acid-fast method. Paratuberculosis lesions were classified microscopically on the basis of morphology and the number of acid-fast bacteria present



as described (Brooks et al., 1988). A diagnosis of paratuberculosis required demonstration of typical acid-fast bacilli in association with a granulomatous lesion in the lower small or large intestine or associated mesenteric lymph nodes. Demonstration of typical acid-fast bacilli in a direct smear was not by itself considered to be sufficient criteria for a diagnosis (Merkal, 1973). Fresh, frozen or fixed tissues and blood from antelope with mycobacterial enteritis and lymphadenitis consistent with paratuberculosis were sent to the Animal Diseases Research Institute (ADRI) (Nepean, Ontario, Canada K2H 8P9) for immunological testing, culture and histology.

Information was requested from five North American zoos to determine if paratuberculosis had been observed in their saiga antelope.

Experimental animals

Ewes were selected as potential dams to deliver lambs for oral challenge experiments or to serve as negative controls from a caesarian derived "minimal disease" sheep flock. The ewes were moved to isolation cubicles prior to parturition. Lambs were held with their dams until weaning at approximately 75 days of age at which time the ewes were sent for necropsy. Negative controls were housed in separate cubicles in an adjacent building. The cubicles were washed daily to remove fecal material. Necropsies were conducted with emphasis on examination of intestine and associated lymph nodes.

Inoculation and microbiological procedures

Intestinal scrapings (3 g) from the mucosal surface from a histologically diagnosed case of paratuberculosis (antelope 12, Table 1) was homogenized with a tissue grinder and suspended in 22 ml of 0.85% saline to form the inoculum. An air dried smear of the inoculum was stained using the Kinyoun acid-fast method and examined microscopically. Large numbers of acid-fast bacilli were seen per oil immersion field. The inoculum was stored at -70°C . It was thawed at room temperature (RT) prior to administration to the lambs and kept at 4°C during the period between inoculations.

Two of three triplet lambs (981 and 982) in the experimental group received 2.7 ml of inoculum orally on day 1 (day of birth) and day 3 of the study. The total inoculation dose for each lamb was approximately 0.65 g of mucosa. The third lamb (983) in this group served as an in-contact control.

Feces and blood were collected from the lambs weekly from weeks three to eight and monthly thereafter to the time of euthanasia or to the end of the study at 18 mo postinoculation. Ewes

were sampled prior to selection for the experiment and weekly until weaning and euthanasia. Clotted blood samples were allowed to stand overnight at room temperature before processing. Heparinized samples of blood were used for the lymphocyte stimulation test (LST) within 6 hr of collection. Direct smears were made from tissues collected at necropsy and from some fecal samples. Smears were stained by Kinyoun's acid-fast method and examined for the presence of typical acid-fast bacilli. Antelope fecal samples were shipped fresh, chilled but not frozen, and processed on the day of arrival at the laboratory. Fecal samples from the lambs were processed within 6 hr of collection. In general the culture procedure described by Merkal (1973) was followed, modified by using cetylpyridinium chloride (CPC) as the decontaminant and centrifugation prior to inoculation. Briefly, 1 g of fecal material was transferred to a 50 ml sterile, conical centrifuge tube and 40 ml of sterile distilled water added. The tube and contents were shaken for 30 min, and then placed in an upright position and left to stand undisturbed for 30 min. The top 5 ml of the fecal suspension was transferred to another 50 ml sterile centrifuge tube containing 35 ml of sterile CPC. The final concentration of CPC was 1%. Following standing at RT for 18 to 24 hr, samples were centrifuged at $2,250 \times g$ (15°C) for 0.5 hr. The supernatant was discarded and the pellet resuspended in 1 ml sterile saline and distributed equally amongst five tubes of Herold's egg yolk medium (HEYM) containing 2 mg/1 mycobactin J (Allied Laboratories, Glenwood Springs, Colorado 81601, USA). The inoculated media was incubated for at least 24 wk at 37°C . Isolates were subcultured onto 1 tube of HEYM with and 1 tube HEYM without mycobactin to confirm mycobactin dependency.

Samples of intestine and mesenteric lymph nodes were collected from lambs 981, 982, and 983 at sites immediately anterior to and approximately 60 cm anterior to the ICV. Intestinal samples were also collected at two additional sites from 983. Tissues from the lambs were held at 4°C overnight and processed the day after collection. Culture of tissue samples was performed as described (Brooks et al., 1988) with decontamination in 0.5% CPC for 18 to 24 hr including centrifugation at $2,250 \times g$ (15°C) for the final 30 min. Resuspension of the pellet, inoculation of media and incubation were the same as for fecal samples. Identification of an isolate as *M. paratuberculosis* was on the basis of survival of the decontamination procedure described above, slow growth on HEYM with mycobactin, no growth on HEYM without mycobactin, typical colonial and cellular morphology and acid fastness.

Immunological procedures

Agar gel immunodiffusion (AGID) tests using antigen "D" and complement fixation (CF) tests using a crude carbohydrate antigen were conducted as previously described (Brooks et al., 1988; de Lisle et al., 1980a, b). Enzyme linked immunosorbent assay (ELISA) tests utilized an exclusion peak from S200 gel filtration of the crude polysaccharide as antigen to coat wells (NUNC Maxisorb Immuno modules, GIBCO, Burlington, Ontario, Canada L7P 1A1). The antigen was dissolved at 10 µg/ml in 0.01 M carbonate buffer, pH 9.6, sonicated and then 100 µl placed in each well. The plates were sealed and placed at -20 C shortly after coating and stored frozen for an indefinite period. Plates were thawed at room temperature before use followed by washing four times in a 96 well plate washer (Flow Laboratories Inc., Mississauga, Ontario, Canada L5S 1R2) using a 0.01 M Tris, 0.15 M NaCl, 0.05% Tween 20 buffer (TT), pH 8.0. Test sera were diluted 1:200 in TT buffer containing 0.02% NaN₃ and 100 µl placed in the microwell modules in duplicate. Controls consisted of (a) a prediluted and frozen aliquot of a positive bovine serum that served as a target, (b) a positive and (c) a negative serum from sheep diluted in the same manner as the test samples, and (d) TT buffer. These were placed on each plate as paired duplicates in columns 1 and 7 for a total of 16 wells for the four controls. Following an overnight serum incubation at room temperature, plates were washed and 100 µl of an alkaline phosphatase conjugated rabbit anti-sheep F(ab')₂ (Jackson ImmunoResearch Laboratories, Inc., West Grove, Pennsylvania 19390, USA) was added for a 3 hr incubation at room temperature. Plates were washed again and 200 µl of p-nitrophenyl phosphate (1 mg/ml) substrate in diethanolamine buffer, pH 9.8, 0.5 mM MgCl₂ was added and the plates shaken continuously between three successive readings of optical density (405 nm) at approximately 2 min intervals on a microplate reader (Flow Laboratories Inc., Mississauga, Ontario, Canada L5S 1R2). The three optical density readings were used to determine the slope value for each paired sample using the regression function of Lotus 123 (Lotus Development Corp., Boston, Massachusetts 02142, USA). The mean slope value of the four control samples was used to calculate a corrected optical density for each sample thus standardizing test results for between plate variation.

A microwell modification of the whole blood stimulation test (de Lisle and Duncan, 1981) was conducted in flat bottomed wells (Flow Laboratories Inc., Mississauga, Ontario, Canada L5S 1R2) using three drops of media (approximately

150 µl) and one drop of whole blood. Twelve wells were used for each sample consisting of four wells of the control media and two wells each of PHA (Phytohemagglutinin), J-PPD (john-in purified protein derivative), B-PPD (bovine) and A-PPD (avian). Plates were incubated for 72 hr at 39 C followed by the addition of 0.5 µCi of tritiated thymidine per well for 18 hr and then frozen at -20 C until thawing for harvesting on a Titertek Cell Harvester (Flow Laboratories Inc., Mississauga, Ontario, Canada L5S 1R2). The level of incorporation of the radiolabel was determined by the addition of 3 ml of scintillation fluid to minivials and counted on a liquid scintillation counter (Beckman Instruments, Toronto, Ontario, Canada L5T 1W5) using a wide tritium window. Results are expressed as net counts per min (NCPM = mean of stimulated cultures minus mean of control cultures).

RESULTS

Paratuberculosis in saiga antelope

Two imported animals died in quarantine (transport stress and trauma) without their paratuberculosis status being determined. The remaining eight animals sent to the Assiniboine Park Zoo were necropsied over a 6 year period. Paratuberculosis was diagnosed histologically in four antelope and two others were not examined specifically for paratuberculosis as only limited histopathologic study of the intestine and lymph node was done (Table 1). Paratuberculosis was also confirmed in five of the seven first generation offspring born at the zoo in 1987 (Table 2) and in six of 11 second generation offspring born in 1989. An estimation of the extent or severity of granulomatous inflammation and mycobacterial load for each animal examined post mortem is given in Table 3. Lesions in the 15 animals with a mycobacterial enteritis consisted of varying degrees of ileal mucosal thickening with fibrous tags on the serosa and dilated lymphatics with white nodules. Mesenteric lymph nodes were enlarged in several animals. Histologically, there was granulomatous enteritis with numerous acid-fast bacteria in macrophages and a granulomatous lymphangitis and lymphadenitis.

TABLE 1. Summary of paratuberculosis serological results and necropsy findings from imported adult saiga antelope.

Animal number	AGID ¹					Date of death ²	Reason for necropsy	Paratuberculosis status
	Date sampled							
	10/85	07/86	09/88	07/89	04/90			
100 ³	ND					10/85	death	unknown
155 ³	S					10/85	trauma	unknown
11 ⁴	R					07/86	trauma	positive
12 ⁵	—	—				03/87	trauma	positive
13	—	—	—	—	—	07/91	killed	negative
14	—	—	—	—	—	07/91	killed	negative
15	—	—	—	—	—	05/91	death	positive
16	—	—				02/88	hemolytic crisis	unknown
17	—	—				06/87	clinical paratuberculosis	positive
18	—					05/86	trauma	unknown

¹ Agar gel immunodiffusion results: R, reactor; S, suspicious; "—," negative; ND, not done. The complement fixation test was also conducted but was negative for each animal at each date sampled.

² Date of natural death or euthanasia.

³ Died during quarantine.

⁴ Fecal samples collected during quarantine revealed a few acid-fast bacteria on smears but culture for *Mycobacterium paratuberculosis* was negative.

⁵ Intestinal tissue from this animal was inoculated orally into sheep.

Granulomas were observed in the liver of some animals.

While only one of four imported animals with confirmed paratuberculosis was a reactor to the AGID test prior to necropsy (Table 1), all confirmed cases in the 1987

offspring were detected by AGID (Table 2, animals numbered 25 or less) within 1 to 5 mo prior to necropsy. When tested in May 1990, two (animals 33 and 34) of the remaining six 1989 offspring had serological reactors on the AGID test. These an-

TABLE 2. Summary of paratuberculosis serological results and necropsy findings from the saiga offspring born spring 1987 and 1989.¹

Animal number	Dam	AGID/CF ²			Date of death	Reason for necropsy	Paratuberculosis status
		Date sampled					
		09/88	07/89	04/90			
19	14 (16) ³	—/—	S/S	R/R	07/90	thin	positive
20	17	R/S			12/88	died	positive
21	13	—/—	R/R		07/89	died	positive
22	16 (14) ⁴	—/—	R/S		11/89	thin	positive
23	16 (14) ⁴	—/—	R/S		08/89	died	positive
24	15	—/—	—/—		11/89	thin	negative
25	15				07/87	trauma	negative
29	19			—/—	07/91	killed	positive
30	21			—/—	03/91	died	positive
31	21			—/—	09/90	pneumonia	positive
33	14			R/—	07/90	died	positive
34	22			S/ND	04/90	died	positive
35	22			—/—	07/91	killed	positive

¹ Animals 19 to 25 were born in 1987. No evidence of paratuberculosis was seen at necropsy of animals (26, 27, 28, 32, 36) which died within 7 wk of birth. Animals 26 or higher were born in 1989.

² Agar gel immunodiffusion/complement fixation: R, reactor; S, suspicious; "—," negative.

³ Dam was probably animal 14 but may have been animal 16.

⁴ Dam was probably animal 16 but may have been animal 14.

imals died within 2 mo of the serological test date and paratuberculosis was diagnosed histologically in both. The remaining four 1989 offspring were confirmed to have paratuberculosis when they died or were killed over the next year (Table 3).

Culture of a fecal sample collected during quarantine from one of the imports (animal 11) was negative for *M. paratuberculosis*, although typical acid-fast bacilli were observed in direct smears (Table 3). *Mycobacterium paratuberculosis* was not isolated from fecal samples collected from five of the imported animals following the death and the confirmed diagnosis of paratuberculosis in animal 11. Subsequent cultural studies were limited to tissues collected at post mortem from animals 12 and 17. Only small numbers of *M. paratuberculosis* were recovered after incubation for 24 wk although high acid-fast bacterial loads were demonstrated in direct smear and by histology. Attempts to culture other enteric pathogens, including *Salmonella* spp. and *Campylobacter jejuni*, from animal 11 were not successful.

Two of three zoos responding to the survey had diagnosed paratuberculosis in saiga antelope in their collections. Both zoos in which paratuberculosis was observed had received their Saiga antelope from Europe. The zoo in which paratuberculosis was not observed acquired their saiga from collections within North America.

Recovery of *M. paratuberculosis* in experimental animals

A few colonies of *M. paratuberculosis* were isolated from fecal samples of lamb 981 (inoculated), collected at 47, 51, 54, and 55 wk after inoculation. Small numbers of acid-fast organisms were seen on direct smears of feces collected at week 55. This animal was necropsied at week 56 and only small numbers of an organism consistent with *M. paratuberculosis* were isolated from the two samples of intestine and from one mesenteric lymph node, while masses of acid-fast bacilli were seen on the direct smears of intestinal scrapings

TABLE 3. Summary of results of pathological and microbiological examinations for paratuberculosis in saiga antelope presented for necropsy.¹

Animal number	Gross lesions ³	Histopathology		Direct smear ² AF ⁴
		lesions ³	AF ⁴	
11	+++	+++	+++	+++
12	+++	+++	+++	+++
13	—	—	ND	ND
14	—	—	ND	ND
15	++	++	++	++
16	—	—	—	ND
17	+++	+++	+++	+++
18	—	—	—	ND
19	+++	+++	+++	+++
20	++	++	+++	+++
21	+++	+++	++	++
22	++	++	++	++
23	++	++	+++	ND
24	—	—	ND	+
25	—	—	ND	ND
29	+++	+++	+++	+++
30	+++	+++	+++	+++
31	+++	+++	+++	+++
33	++	+++	+++	ND
34	+++	++	+++	++
35	+++	+++	+++	+++

¹ No evidence of paratuberculosis observed on necropsy of five other animals (26, 27, 28, 32, 36) which died within 7 wk of birth.

² A positive direct smear was not considered sufficient evidence for classification of an animal as positive for paratuberculosis.

³ Paratuberculosis lesions classified as +, mild; ++, moderate; or +++, severe.

⁴ AF, acid-fast bacilli; ND, not done. Quantitation of acid-fast organisms associated with lesions was graded as +, rare and hard to find; ++, small numbers; or +++, large numbers.

and small numbers were seen in direct smears of the lymph node.

Mycobacterium paratuberculosis was isolated in low numbers from a sample of intestine from lamb 982 (inoculated), but not from fecal samples of 982 or from fecal and tissue samples from lamb 983 (in-contact control). Acid-fast organisms were not seen on direct smears of tissues from either animal.

Clinical and pathological findings in experimental animals

There was no clinical evidence of illness and no gross or microscopic lesions of paratuberculosis in the dams of experimental lambs.

Clinically, lamb 981 (inoculated) was thin but appeared healthy until week 53 when it was anorexic and had soft feces. The feces became watery and then improved again to a soft pelleted form by week 54. No *Salmonella* spp., *Campylobacter* spp. or parasites were recovered from the feces but fecal smears contained low numbers of acid-fast bacteria. By week 56 the severe diarrhea had returned and the animal was euthanized. This animal was thin and had extensive thickening of the distal small intestine with evidence of submucosal edema and increased mucosal thickness. There were small 2 mm white foci along the tortuous serosal lymphatics. The ileocecal and mesenteric lymph nodes were enlarged and had a thick cortex.

Histologically, focal granulomas containing acid-fast bacteria were evident in liver and lung. Similar granulomas were evident in the dilated serosal lymphatics. More diffuse aggregates of macrophages containing numerous acid-fast bacteria were seen primarily in the paracortical area and medulla of the mesenteric lymph nodes. Numerous macrophages, containing many acid-fast bacteria, formed sheets of cells in the intestinal and cecal mucosa. Submucosal, partly mineralized areas of necrosis were present in the Peyer's patch area of the bowel. Some mucosal crypts were full of necrotic debris and lymphatic spaces in the submucosa were markedly dilated.

Lamb 982 (inoculated) was clinically normal but at necropsy the wall of the ileum was thickened and the mesenteric lymph nodes were enlarged with extensive thickening of the cortex. Histologically tiny granulomas were seen in the interstitium of the lung and liver but no acid-fast bacteria could be demonstrated. There were foci of macrophages in the mucosa and submucosa of the ileocecal valve but no acid-fast bacteria were seen. In several other histologic sections of ileum only one focus of macrophages was seen. This mucosal lesion was associated with the Peyer's patches of the ileum. Lymphangiectasia

and granulomatous lymphangitis were evident on the serosa of terminal ileum and acid-fast bacteria were only rarely found. A mesenteric lymph node contained foci of macrophages in the paracortex and only one giant cell was seen. Acid-fast bacteria were difficult to find.

No clinical signs were seen in the in-contact control lamb (983) but at necropsy two white foci (2 mm) were seen on the intestinal serosa about 60 cm anterior to the ICV associated with the terminal ileal mass of gut associated lymphoid tissue. Histologically, an occasional focal granulomatous lesion associated with Peyer's patches and one submucosal granuloma were seen but rarely were acid-fast bacteria observed.

No lesions of paratuberculosis were seen on pathological examinations of the non-contact control lambs.

Immunological test results in experimental animals

Immunological test (ELISA, AGID, LST) results of dams of experimental lambs were within normal limits on samples collected prior to selection and from lambing to slaughter. Sequential ELISA and AGID test results from the two challenged lambs (981, 982) and the one in-contact control lamb (983) are shown in Figure 1. The ELISA test results indicate that the three lambs had a low level of passive antibody followed by a rise in titer at 4 to 6 months of age. The titers in the two orally inoculated lambs rose more rapidly and to a higher level than the in contact control. Both orally challenged lambs developed precipitating antibodies to the "D" antigen but the lamb that developed clinical disease (981) responded approximately 200 days later.

The four non-contact control lambs were negative by AGID and classified as negative by ELISA with the exception of a single lamb with a non-persistent response. The LST responses to PHA and J-PPD of the two orally challenged lambs and the in-contact control are shown in Figure 2.

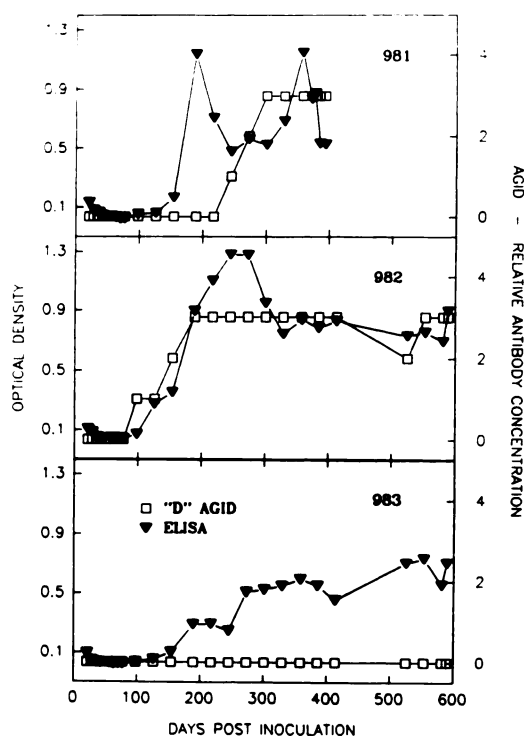


FIGURE 1. Sequential serological tests (AGID and ELISA) results from the two orally challenged (981, 982) and the in-contact control (983) lambs. Lamb 981 died of paratuberculosis. ELISA units are on the left vertical axis and AGID units on the right vertical axis.

The NCPM to PHA was generally $>10,000$ and exceeded the response to J-PPD initially. In the two orally inoculated lambs the response to J-PPD increased (NCPM $>20,000$) to exceed PHA just prior to day 100 post inoculation and thus clearly indicative of sensitization to mycobacterial antigens at this time. Similar responses were demonstrated to J-PPD and A-PPD (not shown) and both exceeded those to B-PPD. The antigen (J-PPD) and mitogen (PHA) stimulated responses demonstrated by lamb 981 were more variable than those of 982 and fell dramatically in conjunction with the development of clinical signs. The J-PPD responses of the in-contact control lamb took considerably longer (>300 days) to reach responses that approximated or exceeded those induced by PHA. There

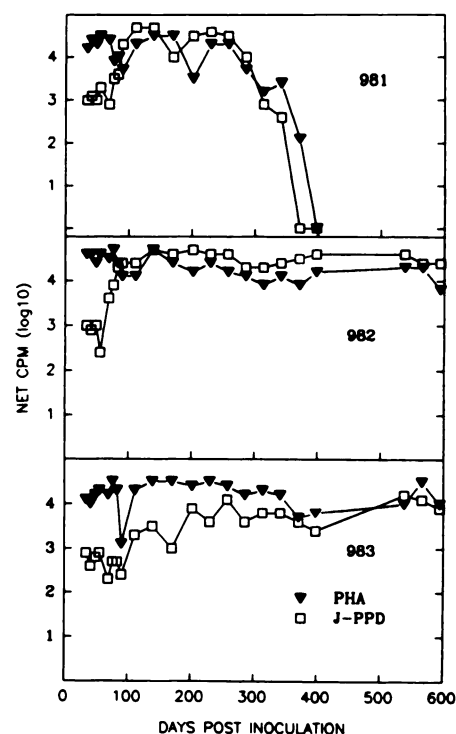


FIGURE 2. Sequential lymphocyte stimulation test results from the two inoculated (981, 982) and the one in-contact control (983) lambs. Lamb 981 died of paratuberculosis.

was no evidence of mycobacterial sensitization in the non-contact control lambs.

DISCUSSION

Paratuberculosis has been reported in various species of antelope since 1922 (Jarnai, 1922; Dorofev and Kalechev, 1949) but this is the first report of natural paratuberculosis in saiga antelope. In the present study paratuberculosis was confirmed in three of eight (38%) of the saiga antelope imported into the zoo and in seven of 18 (39%) of their offspring. The prevalence of paratuberculosis in the offspring may have been higher since another six of the 18 offspring died at less than six months of age when one may not readily demonstrate histologic evidence of paratuberculosis because the disease would be in the early stages of development. If we accept the negative serological status of the two

adult female saigas numbered 13 and 14, as absence of paratuberculosis, then infection of their offspring (19, 21, 33) indicates that horizontal transmission from animals other than infected dams was important. This is supported by the experimental study where transmission of the antelope isolate of *M. paratuberculosis* to the in-contact control lamb was observed in a daily sanitized environment and emphasizes the potential for interspecies spread of the disease in a zoo. A survey indicating that paratuberculosis was a problem in other zoological collections of saiga antelope emphasizes the need for strict control and testing in the trade of this species and other susceptible species.

Mycobacterium paratuberculosis is generally inactive on traditional biochemical tests (Chiodini, 1986) and considered to be a homogeneous species from a metabolic or biochemical perspective. Molecular characterization by restriction endonuclease analysis demonstrated that 54 *M. paratuberculosis* isolates (50 of bovine origin) were very similar to each other and to the species reference strain (Collins and de Lisle, 1986; Whipple et al., 1989). However, in other studies, distinct differences between isolates have been observed in pigmentation (Taylor, 1951; Watt, 1954; Stuart, 1965), pathogenicity (Saxegaard, 1989), and cultural properties including poor recovery with conventional culture techniques from specimens where large numbers of acid-fast organisms were demonstrated (Dunkin and Balfour-Jones, 1935; Taylor, 1951; Gummarsson, 1979; de Lisle, 1987; Brooks et al., 1988; Juste et al., 1991; Carrigan and Seaman, 1990). Collins et al., 1990 demonstrated on the basis of restriction endonuclease and DNA hybridization patterns of genomic DNA that difficult to culture sheep isolates are distinct from all bovine isolates tested. In addition, other slow growing, mycobactin dependent *Mycobacterium* spp., such as the wood-pigeon bacillus (Matthews and McDiarmid, 1979) and isolates from humans with Crohn's disease (Chiodini et al., 1984) have also been

reported and complicate the identification of an isolate as *M. paratuberculosis*. In the present study *M. paratuberculosis* was isolated only in low numbers from the antelopes and lambs although large numbers of organisms were frequently demonstrated in smears. While freezing may have been a factor in the poor recovery of *M. paratuberculosis* in samples submitted from the zoo, samples from the lambs were cultivated without freezing and similar difficulties were encountered. These observations are consistent with this antelope isolate of *M. paratuberculosis* having characteristics different from those of classical bovine isolates.

There are several limitations to extrapolating the results of experimental paratuberculosis to transmission of the natural disease. These limitations include the potential for other unrecognized agents being present in the inoculum prepared from the intestinal mucosa, and no reliable measure of the number of viable organisms inoculated. However, the experiment confirms the potential for interspecies transmission of infection and disease. Infection of sheep by oral inoculation of this strain led to seroconversion to the standard diagnostic tests for paratuberculosis (AGID, ELISA) with the level of antibody reflecting the bacterial load or the severity of the lesions as previously observed in the natural disease in domestic sheep (Brooks et al., 1988). The later development of precipitating antibodies to antigen "D" by comparison to the ELISA response to carbohydrate antigen in the lamb that developed clinical disease may be of some significance from the perspective of the development of resistance and diagnosis. This strain may be particularly pathogenic for sheep as exemplified by the apparent bacteremia and the development of clinical disease following a short, 11 mo, incubation period. Caseation of lesions similar to that seen in other tubercular mycobacterial diseases (*M. avium*, *M. bovis*) and paratuberculosis of domestic small ruminants was observed in the experimen-

tal sheep although the non-caseous lesion of classical bovine paratuberculosis was also in evidence. Thus the results of the experimental disease in sheep have paralleled our observations in the saiga antelope to date.

The relative ease of transfer of *M. paratuberculosis* from antelope to sheep in these experiments suggests that interspecies transfer of this disease could occur in the native habitat of the saiga antelope where these species are observed to share watering places (Alton, 1990).

The control or eradication of mycobacterial disease in non-domestic species may require different approaches than have been applied in domestic animals. Culture, for example, has been seen as a reliable index (including quantitation) of infection in cattle but in these saiga antelope culture was very difficult in spite of histologic evidence of heavy infection. Frequent serum sampling in captive wild species as part of a test and cull program presents a problem of increasing capture stresses and may be of questionable value. Therefore vaccination in conjunction with good sanitation should be considered as a method of paratuberculosis control in captive wild ruminants (MacDiarmid, 1989).

Finally as wild ruminants are transported around the world for zoos and meat production there may be increased risk of spread of strains of *M. paratuberculosis* that are pathogenic for other ruminants in zoological collections and agricultural enterprises.

ACKNOWLEDGMENTS

The authors want to acknowledge the valuable contributions to this study of Dr. Pierre Vivier of Agriculture Canada, Mirabel International Airport, Mirabel, Quebec. His initial interest and co-operation were the initial stimulus for this work. We thank B. Rapheal of the Dallas Zoo, M. T. Berrie of the Oklahoma City Zoological Park and S. Abildgaard of the San Diego Zoo for providing information regarding saiga antelope in their collections. J. L. Neufeld, R. J. Austin, J. M. Bystrom and G. Spearman are thanked for the use of the data from the antelope examined by them at necropsy. Stan

van Zyll de Jong made helpful comments on ungulate taxonomy. The technical staff of ADRI, especially Henry Barleben, Barbara Dupree, Jim Hodgson, Hilary Kelly, Nancy Lopes, Vita Radzius, Jeanette Jeffreys and Barbara Stewart are very much appreciated for their efforts on our behalf. We thank the serology section for providing the results for standard serological tests for paratuberculosis. G. M. Ruckerbauer is thanked for her assistance with some of the German references. Claude Turcotte assisted with the cultural work. P. Atherton and G. Eldridge assisted us with some interlibrary loans. The Manitoba Public Health Laboratory's help in mycobacterial culture of two cases is acknowledged. We thank Joan Graham for word processing assistance and David Gall for his computer graphics expertise.

LITERATURE CITED

- ALTON, G. G. 1990. *Brucella melitensis*. In Animal brucellosis, J. R. Duncan and K. Nielsen (eds.). CRC Press, Inc., Boca Raton, Florida, pp. 383–409.
- BARADEL, J. M., J. BARRAT, J. BLANCOU, J. M. BOUTIN, C. CHASTEL, G. DANNACHER, D. DELORME, Y. GERARD, J. M. GOURREAU, U. KIHM, B. LARENAUDIE, C. LE GOFF, P-P. PASTORET, P. PERREAU, A. SCHWERS, E. THIRY, D. TRAP, G. UILENBERT, AND P. VANNIER. 1988. Results of a serological survey of wild animals in France. *Revue scientifique et technique Office International Epizootie* 7: 873–883.
- BROOKS, B. W., R. H. ROBERTSON, A. H. CORNER, B. S. SAMAGH, M. M. GARCIA, C. TURCOTTE, AND J. R. DUNCAN. 1988. Evaluation of the serological response of sheep in one flock to *Mycobacterium paratuberculosis* by crossed immunoelectrophoresis. *Canadian Journal of Veterinary Research* 52: 199–204.
- CARRIGAN, M. J., AND J. T. SEAMAN. 1990. The pathology of Johne's Disease in sheep. *Australian Veterinary Journal* 67: 47–50.
- CHIODINI, R. J., AND H. J. VAN KRUININGEN. 1983. Eastern white-tailed deer as a reservoir of ruminant paratuberculosis. *Journal of the American Veterinary Medical Association* 182: 168–169.
- , ———, AND R. S. MERKAL. 1984. Ruminant paratuberculosis (Johne's Disease): The current status and future prospects. *Cornell Veterinarian* 74: 218–262.
- . 1986. Biochemical characteristics of various strains of *Mycobacterium paratuberculosis*. *American Journal of Veterinary Research* 47: 1442–1445.
- COLLINS, D. M., AND G. W. DE LISLE. 1986. Restriction endonuclease analysis of various strains of *Mycobacterium paratuberculosis* isolated from

- cattle. *American Journal of Veterinary Research* 47: 2226-2229.
- , D. M. GABRIC, AND G. W. DE LISLE. 1990. Identification of two groups of *Mycobacterium paratuberculosis* strains by restriction endonuclease analysis and DNA hybridization. *Journal of Clinical Microbiology* 28: 1591-1596.
- COMMICHAU, C. 1982. Nachweis von Paratuberkulose beim Damwild (*Dama dama*). *Berliner und Münchener Tierärztliche Wochenschrift* 95: 248-250.
- DE LISLE, G. W. 1987. Johne's Disease in goats. *Surveillance* 14: 17-19.
- , AND J. R. DUNCAN. 1981. Bovine paratuberculosis III: An evaluation of a whole blood lymphocyte transformation test. *Canadian Journal of Comparative Medicine* 45: 304-309.
- , P. SEGUIN, B. S. SAMAGH, A. H. CORNER, AND J. R. DUNCAN. 1980a. Bovine paratuberculosis I: A herd study using complement fixation and intradermal tests. *Canadian Journal of Comparative Medicine* 44: 177-182.
- , B. S. SAMAGH, AND J. R. DUNCAN. 1980b. Bovine paratuberculosis II: A comparison of fecal culture and antibody response. *Canadian Journal of Comparative Medicine* 44: 183-191.
- DOROFEV, K. A., AND L. A. KALECHEV. 1949. Johne's Disease in sheep and wild animals (in Russian). *Veterinarija, Moscow* 26: 21-24.
- DUNKIN, G. W., AND S. E. B. BALFOUR-JONES. 1935. Preliminary investigation of a disease of sheep possessing certain characteristics simulating Johne's Disease. *Journal of Comparative Pathology and Therapeutics* 48: 236-240.
- GUMMARSSON, E. 1979. Isolation of *Mycobacterium paratuberculosis* from sheep and cattle in Iceland. *Acta Veterinaria Scandinavica* 20: 191-199.
- JARNAI, K. 1922. Gekröslymphknoten und Lebernekrose bei Enteritis Paratuberculosis. *Deutsche Tierärztliche Wochenschrift* 30: 257-259.
- JUSTE, R. A., J. C. MARCO, C. SAEZ DE OCARIZ, AND J. J. ADURIZ. 1991. Comparison of different media for the isolation of small ruminant strains of *Mycobacterium paratuberculosis*. *Veterinary Microbiology* 28: 385-390.
- KATIC, I. 1961. Paratuberculosis (Johne's Disease) with special reference to captive wild animals. *Nordisk Veterinarmedicin* 13: 205-214.
- . 1969. Bibliography of literature on Johne's Disease (paratuberculosis) 1895-1964. Royal Veterinary and Agricultural University, Copenhagen.
- MACDIARMID, S. C. 1989. The control of Johne's disease by vaccination. *Surveillance* 16: 7-10.
- MATTHEWS, P. R. J., AND A. MC DIARMID. 1979. The production in bovine calves of a disease resembling paratuberculosis with a *Mycobacterium* sp. isolated from a wood pigeon (*Columba palumbus*). *The Veterinary Record* 104: 286.
- MERKAL, R. S. 1973. Laboratory diagnosis of bovine paratuberculosis. *Journal of the American Veterinary Medical Association* 163: 1100-1102.
- SAXEGAARD, F. 1989. Experimental infection of calves with an apparently specific goat pathogenic strain of *Mycobacterium paratuberculosis*. *Proceedings of the World Association of Veterinary Laboratory Diagnosticians, Guelph, Ontario, Canada*, 1 pp.
- STUART, P. 1965. A pigmented *M. johnei* strain of bovine origin. *British Veterinary Journal* 121: 332-334.
- TAYLOR, A. W. 1951. Varieties of *Mycobacterium johnei* isolated from sheep. *Journal of Comparative Pathology* 63: 333-335.
- WATT, J. A. A. 1954. Johne's disease in a bovine associated with the pigmented strain of *Mycobacterium johnei*. *The Veterinary Record* 66: 387.
- WEBER, A. 1980. Nachweis von Antikörpern gegen Paratuberkulose (Johnesche Krankheit) bei Schalenwild. *Zeitschrift für Jagdwissenschaft* 26: 194-197.
- . 1982. Nachweis von "atypischen" Mykobakterien in Kotproben von Jagdtieren. *Berliner und Münchener Tierärztliche Wochenschrift* 95: 30-32.
- WHIPPLE, D. L., P. A. KAPKE, AND R. F. ANDREWS, JR. 1989. Analysis of restriction endonuclease fragment patterns of DNA from *Mycobacterium paratuberculosis*. *Veterinary Microbiology* 19: 189-194.
- WILLIAMS, E., T. R. SPRAKER, AND G. G. SCHOONVELD. 1979. Paratuberculosis (Johne's Disease) in Bighorn Sheep and Rocky Mountain Goat in Colorado. *Journal of Wildlife Diseases* 15: 221-227.
- , S. P. SNYDER, AND K. L. MARTIN. 1983a. Experimental infection of some North American wild ruminants and domestic sheep with *Mycobacterium paratuberculosis*: Clinical and bacteriological findings. *Journal of Wildlife Diseases* 19: 185-191.
- , ———, AND ———. 1983b. Pathology of spontaneous and experimental infection of North American wild ruminants with *Mycobacterium paratuberculosis*. *Veterinary Pathology* 20: 274-290.

Received for publication 5 December 1990.