

Capripoxvirus Disease in an Arabian Oryx (*Oryx leucoryx*) from Saudi Arabia

Authors: Greta, Arnaud, Gourreau, Jean Marie, and Vassart, Marc

Source: Journal of Wildlife Diseases, 28(2) : 295-300

Published By: Wildlife Disease Association

URL: <https://doi.org/10.7589/0090-3558-28.2.295>

BioOne Complete (complete.BioOne.org) is a full-text database of 200 subscribed and open-access titles in the biological, ecological, and environmental sciences published by nonprofit societies, associations, museums, institutions, and presses.

Your use of this PDF, the BioOne Complete website, and all posted and associated content indicates your acceptance of BioOne's Terms of Use, available at www.bioone.org/terms-of-use.

Usage of BioOne Complete content is strictly limited to personal, educational, and non - commercial use. Commercial inquiries or rights and permissions requests should be directed to the individual publisher as copyright holder.

BioOne sees sustainable scholarly publishing as an inherently collaborative enterprise connecting authors, nonprofit publishers, academic institutions, research libraries, and research funders in the common goal of maximizing access to critical research.

Capripoxvirus Disease in an Arabian Oryx (*Oryx leucoryx*) from Saudi Arabia

Arnaud Greth,¹ Jean Marie Gourreau,² Marc Vassart,¹ Nguyen-Ba-Vy,³ Monique Wyers,⁴ and Pierre Charles Lefevre,³ ¹ National Wildlife Research Center (National Commission for Wildlife Conservation and Development), P.O. Box 1086, Taif, Saudi Arabia; ² Laboratoire Central de Recherches Veterinaires, 22, rue Pierre Curie, 94703 Maisons-Alfort Cedex, France; ³ Institut d'Elevage et de Medecine Veterinaire des Pays Tropicaux, 10, rue Pierre Curie, 94704 Maisons-Alfort Cedex, France; ⁴ Ecole Nationale Veterinaire de Nantes, Route de Gachet, C.P. 3013, 44087 Nantes Cedex 03, France

ABSTRACT: Lumpy skin disease caused by a capripoxvirus was observed in a captive-bred female Arabian oryx (*Oryx leucoryx*) at the National Wildlife Research Center, Taif, Saudi Arabia. Clinical signs included severe general depression with fever, anorexia, >1,000 nodular cutaneous lesions and gradual recovery over 2 mo. The virus was found by electron microscopy and paired sera showed an increasing virus neutralization antibody titer against capripoxvirus. A serologic survey of the herd of 90 oryx showed a low prevalence (2%) of this infection. This report describes the first case of lumpy skin disease in an Arabian oryx.

Key words: Lumpy skin disease, Capripoxviridae, capripoxvirus, oryx, *Oryx leucoryx*, case report.

Lumpy skin disease is a highly infectious cutaneous disease caused by a capripoxvirus in the family Poxviridae (Matthews, 1982), and thus belongs to the same virus sub-group as the viruses of sheep pox and goat pox. Lumpy skin disease is well known in most African countries, especially in cattle, but it also occurs in sheep and goats. Susceptibility of wildlife was demonstrated by discovery of neutralizing antibodies (Davies, 1981; Hedger and Hamblin, 1983) and by experimental infection (Young et al., 1970). Serologic surveys revealed antibodies in buffalo (*Syncerus caffer*), greater kudu (*Tragelaphus strepsiceros*), waterbuck (*Kobus ellipsiprymnus*, *K. defassa*), reedbuck (*Redunca arundinum*), impala (*Aepyceros melampus*), springbok (*Antidorcas marsupialis*) and giraffe (*Giraffa camelopardalis*). These surveys raised the question whether wildlife may act as a reservoir of the virus. Davies (1981) found antibodies in wild buffalo in areas where the disease occurred sporadically in Kenya, or 1 yr after an

epizootic in Uganda, and thus suspected the buffalo to be reservoirs for the disease. But Hedger and Hamblin (1983), in a large serologic survey, including 3,445 sera of 44 free-living wild species collected during 19 yr, showed evidence of lumpy skin disease virus infection in only six species (kudu, waterbuck, reedbuck, impala, springbok and giraffe). Prevalence of seropositive animals was low and the study did not suggest that wildlife in Africa played an important role in the epidemiology of the disease.

This report is the first case of a lumpy skin disease infection described in the Arabian oryx (*Oryx leucoryx*) and is also the first case of lumpy skin disease reported from Saudi Arabia (Office International des Epizooties, 1990a). Lumpy skin disease appeared in southern Africa in the late 1920's, then spread to eastern Africa and reached most of the western African countries in the late 1970's (Office International des Epizooties, 1988). In 1989, the disease was present in almost all African countries, with a high incidence in Egypt (Office International des Epizooties, 1990b; Ali et al., 1990). It was not reported outside of Africa until recently. In the Middle East, the first focus occurred in 1986 in Kuwait, where 642 cases were reported in cattle (Ordner and Lefevre, 1987). Since then, cases have been confirmed or suspected in United Arab Emirates, Arab Republic of Yemen, Democratic People's Republic of Yemen (Office International des Epizooties, 1990b) and Israel (Office International des Epizooties, 1989).

The Arabian oryx herd of the National Wildlife Research Center (N.W.R.C.), Taif




FIGURE 1. Arabian oryx female with the whole body covered with lumps.

(21°17'N, 40°40'E), Saudi Arabia, was created in 1986, as part of the national oryx conservation action plan, with 56 animals coming from the late King Khaled farm near Riyadh. Because of a tuberculosis outbreak that occurred in 1986 and 1987, the founder group had been kept isolated in 1 area of the N.W.R.C., without any possible contact with the F1 and F2 generations. No other oryx had been introduced in the herd since its creation. The animals had no direct contact with other ungulate species. The animals were housed in 240 m² individual pens or in 0.5 to 25 ha enclosures in groups of one to five individuals.

In mid-August 1989, the 2-yr-old female Arabian oryx 52 from the founder group showed lethargy in the early morning, partial anorexia and soft feces. A more complete examination revealed generalized urticaria with a few skin lumps and slight pruritus. On the next day no improvement had occurred and the animal remained depressed, recumbent. Four days later, lumps were present in skin over whole

body (Fig. 1) but were mainly concentrated on the neck, head, and legs. One week after the appearance of the lesions, the animal was still depressed and anorexic and had lost weight. The body temperature was 42 C immediately after immobilization with etorphine hydrochloride and xylazine and decreased to 40.5 C, when the animal was placed in the shade and showered with water. The clinical examination showed a slight dehydration. Coprological examination revealed no parasite eggs. The animal did not improve after treatment with promethazine (Phe-nergan, Rhône Mérieux, Lyon, France), administered the second day with a dart, or with methylprednisolone succinate (Solu Medrol, Upjohn, Paris, France), administered the fourth day, as well as with methylprednisolone acetate (Depo Medrol, Upjohn, Paris, France) and penicillin G (Extencilline, Rhône Mérieux, Lyon, France) administered during the immobilization the seventh day. Fluids were administered intravenously daily the following 3 days. The animal was so weak that

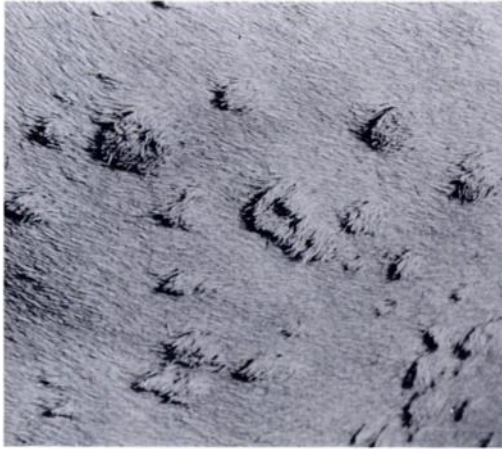

FIGURE 2. Macroscopic view of the nodules.

it remained recumbent and trembled and no sedative or anesthetic for restraint was required. The animal developed a left side torticollis, 9 days after the first clinical signs. From day 11, the general condition gradually improved and the animal began to stand and eat again. The body temperature became normal, taken when the animal was recumbent and restrained manually. On day 13, it aborted possibly due to the disease or in response to the corticosteroid treatment. No lesion was noticed in the aborted calf. Serology for evidence of brucellosis by seroagglutination test, Rose Bengale plate test, complement fixation test, and of Q fever and chlamydiosis by the complement fixation test was proved negative.

On the seventh day, the cutaneous lesions were 1,300 to 1,400 firm, round, raised non-sensitive nodules, with all the hairs raised in the same direction (Fig. 2). Nodules varied between 0.5 and 4 cm in diameter and involved the whole thickness of the skin but without adhering to subcutaneous tissues. A few round, <1 cm diameter, ulcers were present on the gums (Fig. 3), the vulva and the skin surrounding the anus. Healing of the cutaneous nodules was slow. By the end of September most of them remained. Some nodules dropped off leaving an open wound with a pink dry scab. Most of the nodules did

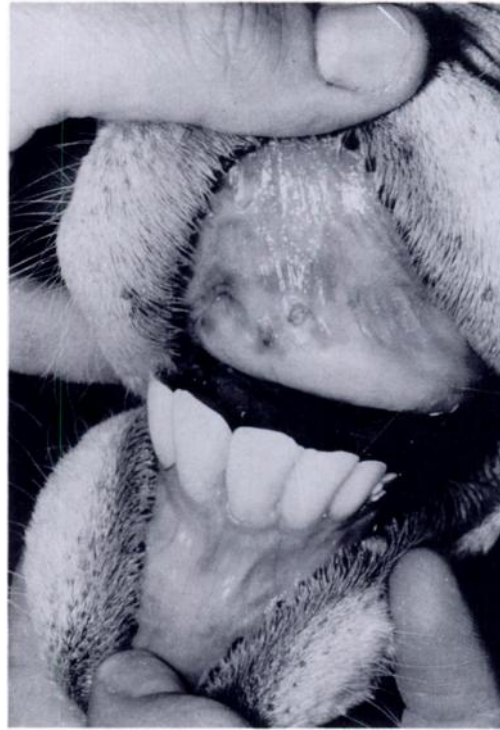

FIGURE 3. Two ulcers on the gum.

not drop off but dried up in situ and were easily removed manually. The hairs came out in tufts from some of the lesions. Most of the lesions had disappeared by the end of October but black scars remained on the neck at the sites of the largest nodules. One year after the onset of the disease, the scars of the skin lesions were still visible as dark round patches. The hairs had not grown back 2 yr later.

Histologic examination of one skin lesion collected 7 days after the appearance of the lesions showed hyperplastic epidermis with hydropic degeneration and necrosis of the epidermal cells (Fig. 4). The dermis was extensively infiltrated by lymphoid and macrophagic inflammatory cells. Intracytoplasmic inclusion bodies were not seen.

Ultra thin sections (Reynolds, 1963) were made on one non-ulcerated nodule which had appeared 13 days before biopsy. Electron microscopic examination revealed numerous intracytoplasmic mature and

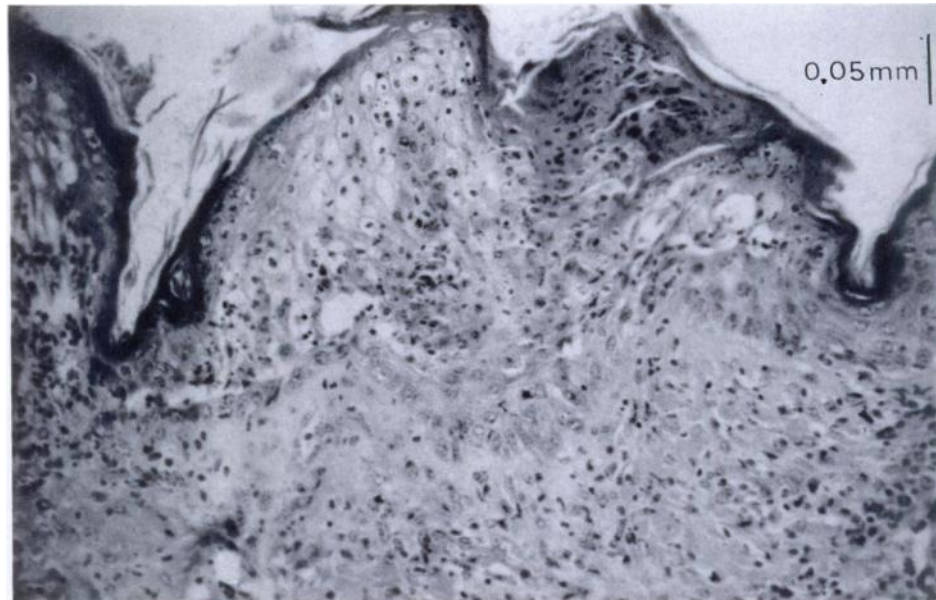


FIGURE 4. The epidermis is hyperplastic and exhibits hydropic degeneration of the stratum granulosum and necrosis of the superficial cells. Hematoxylin-Erythrosine and Saffron.

non mature viral particles (300×350 nm) in the dermis fibroblasts and in the cells of the stratum spinosum of the epidermis (Fig. 5), suggestive of a poxvirus. The attempt to isolate the virus from the skin lesions failed.

Seroneutralization test using constant virus (titer of $\times 10^3$ TCID₅₀/ml) and variable serum method demonstrated virus neutralization at greater than 1:640 dilution on 14 October 1989. Serum collected 15 May 1990 gave a titer of 1:128. Serum collected 25 June 1989, before the appearance of the clinical signs, displayed no antibodies, using the same technique.

Seroneutralization test was performed in foetal lamb skin cell-culture plates using constant serum and variable virus method: serial 10-fold dilutions of sheep pox virus (Strain "Arabie/224," isolated from a clinical case in a sheep from Saudi Arabia in 1981) were mixed with a constant $\frac{1}{5}$ dilution of serum and incubated for 1 hour at 37 C followed by 12 hr at 4 C before inoculation into cell plates. The titers were recorded after 8 days at 37 C and calcu-

lated according to the method of Reed and Muench (1938). The neutralization index of each serum was taken as the difference in titers of sheep pox virus in negative and positive sera. The results showed that the seroneutralization indices of the oryx sera sampled 1 and 2 mo after the appearance of the disease were both high (5.19).

The female oryx 52 was the only animal in the herd of 90 individuals to develop lesions. To examine the prevalence of Capripoxviridae infection in the herd, a serologic survey was performed on 196 sera collected from 1987 to 1990 from 90 different animals. All sera had been stored at -30 C before being analyzed by virus neutralization. This test was performed with the "Ethiopie I" strain, isolated from an outbreak of lumpy skin disease in Ethiopian calves in 1984. This strain has been adapted after multiple passages to grow in Vero cells cultures. The constant virus (titer of $\times 10^3$ TCID₅₀/ml) and variable serum technique was carried out in Vero cells plates. No antibodies to lumpy skin disease were found, except in 1990 in the

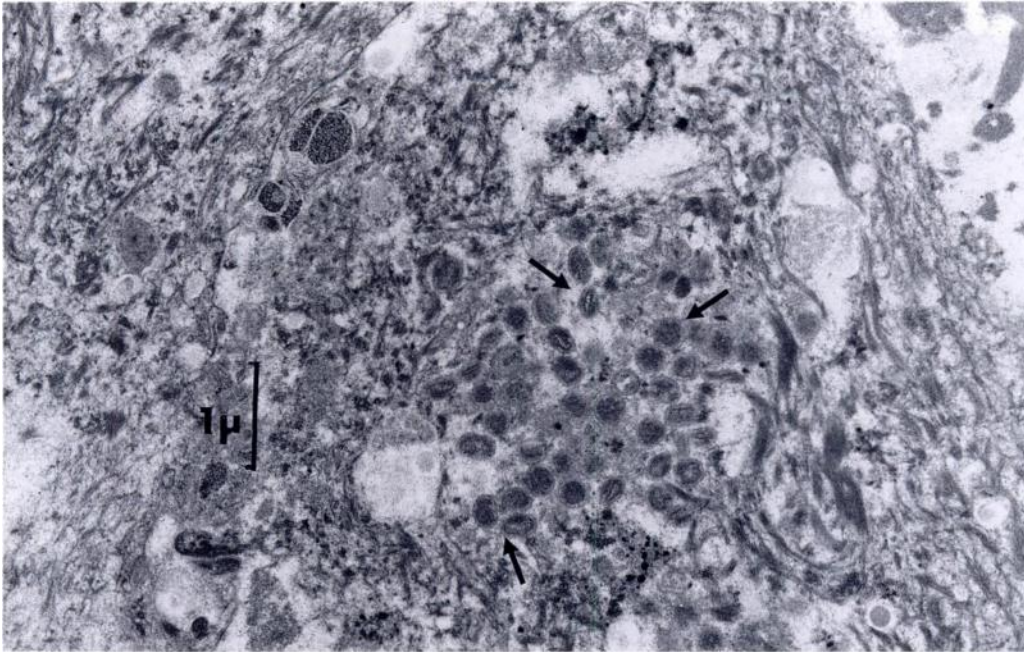


FIGURE 5. Numerous intracytoplasmic particles (arrows) or poxvirus at different stages of development.

female oryx 52 and in another female, also from the founder group and kept in the same area. This female had an antibody titer of 1:64 in 1987, 1988, 1989 and 1990. Clinical signs had not been noticed. Prevalence in the herd was 2% (2 of 90). The Arabian oryx appears to be fairly resistant to Capripoxviridae infection.

The clinical signs observed in the oryx female were similar to those seen in cattle although this oryx case was rather a benign one (no digestive symptoms due to lesions in the rumen), in spite of the many cutaneous nodules.

The N.W.R.C. is situated in an extensive sheep, goat and camel rearing area with some animals often grazing along its perimeter fence. Transmission of lumpy skin disease to cattle by sheep is well known and was documented in Kenya in 1957 (Burdin and Prydie, 1959). Moreover, sheep seem to be sensitive to a lumpy skin-like disease due to the same virus (Chamoiseau, 1985) and could be carriers of the virus. The Kingdom of Saudi Arabia

imports many live sheep, some coming from countries with lumpy skin disease such as Sudan or Somalia (Ordner and Lefevre, 1987). The transmission of lumpy skin disease by a biting insect has never been proven, but is strongly supported by circumstantial evidence (Davies, 1981). Capripoxvirus was transmitted between sheep using *Stomoxys calcitrans* as a vector, as shown experimentally by Kitching and Mellor, (1986). Insect transmission from domestic sheep could explain the infection of the female oryx we studied.

This study was carried out under the patronage of HRH Prince Saud Al Faisal, Abdulaziz Abuzinada, Secretary General of National Commission for Wildlife Conservation and Development, Jacques Renaud, General Manager of the N.W.R.C. and Abdul Rahman Khoja, Administrative Manager of the N.W.R.C. The authors wish to thank B. Armstrong, A. Verdier and B. Chardonnet for their assistance; J. Flamand for his review of the manuscript; D. Calvez and B. Qarin for the laboratory

work; S. Anagaryah for information provided; A. Delhomme for his help during the field work; B. Pambour for the slides; and three anonymous reviewers for their contributions to the manuscript.

LITERATURE CITED

- ALI, A. A., M. ESMAT, H. ATTIA, A. SELIM, AND Y. M. ABDEL-HAMID. 1990. Clinical and pathological studies on lumpy skin disease in Egypt. *Veterinary Record* 127: 549-550.
- BURDIN, M. L., AND J. PRYDIE. 1959. Observations on the first outbreak of lumpy skin disease in Kenya. *Bulletin of Epizootic Diseases of Africa* 7: 21-26.
- CHAMOISEAU, G. 1985. Poxvirose chez le mouton Mauritanien: Clavelee ou maladie nodulaire atypiques? *Revue d'Elevage et de Medecine Veterinaire des Pays Tropicaux* 38: 119-121.
- DAVIES, F. G. 1981. The possible role of wildlife as maintenance hosts for some African insect-borne virus diseases. *In Proceedings of a workshop "Wildlife disease research and economic development,"* L. Karstad, B. Nestel and M. Graham (eds.). Kabete, Kenya, pp. 24-27.
- HEDGER, R. S., AND C. HAMBLIN. 1983. Neutralising antibodies to lumpy skin disease virus in African wildlife. *Comparative Immunology and Microbiology of Infectious Diseases* 6: 209-213.
- KITCHING, R. P., AND P. S. MELLOR. 1986. Insect transmission of capripoxvirus. *Research in Veterinary Science* 40: 255-258.
- MATTHEWS, R. E. F. 1982. Classification and nomenclature of viruses. Fourth report of the International Committee on Taxonomy of Viruses. *In Intervirology*. Karger, Basel, Switzerland, pp. 42-46.
- OFFICE INTERNATIONAL DES EPIZOOTIES. 1990a. Animal health in the eighties. Office International des Epizooties, Paris, France, 84 pp.
- . 1990b. World animal health 5. Office International des Epizooties, Paris, France, 703 pp.
- . 1989. Lumpy skin disease in Israel. *Disease Information* 2: 122.
- . 1988. Lumpy skin disease. *Disease Information* 1: 1.
- ORDNER, G., AND P. C. LEFEVRE. 1987. La dermatose nodulaire contagieuse des bovins. Etudes et synthèses de l'Institut d'Elevage et de Medecine Veterinaire Tropicale, Maisons-Alfort, Paris, France, 92 pp.
- REED, L. J., AND H. MUENCH. 1938. A simple method for estimating fifty percent end points. *American Journal of Hygiene* 27: 493.
- REYNOLDS, E. S. 1963. The use of lead citrate at high pH as an electron opaque stain in electron microscopy. *Journal of Cell Biology* 17: 208.
- YOUNG, E., P. A. BASSON, AND K. E. WEISS. 1970. Experimental infection of game animals with lumpy skin disease virus (Prototype Strain Neethling). *The Onderstepoort Journal of Veterinary Research* 37: 79-88.

Received for publication 21 January 1991.