

## **Testicular Myxosporidiasis in the Flat-Backed Toad, *Bufo maculatus* (Amphibia: Bufonidae), from Cameroon, Africa**

Authors: Upton, Steve J., Freed, Paul S., Freed, Deborah A., McAllister, Chris T., and Goldberg, Stephen R.

Source: Journal of Wildlife Diseases, 28(2) : 326-329

Published By: Wildlife Disease Association

URL: <https://doi.org/10.7589/0090-3558-28.2.326>

---

BioOne Complete ([complete.BioOne.org](https://complete.BioOne.org)) is a full-text database of 200 subscribed and open-access titles in the biological, ecological, and environmental sciences published by nonprofit societies, associations, museums, institutions, and presses.

Your use of this PDF, the BioOne Complete website, and all posted and associated content indicates your acceptance of BioOne's Terms of Use, available at [www.bioone.org/terms-of-use](https://www.bioone.org/terms-of-use).

Usage of BioOne Complete content is strictly limited to personal, educational, and non - commercial use. Commercial inquiries or rights and permissions requests should be directed to the individual publisher as copyright holder.

---

BioOne sees sustainable scholarly publishing as an inherently collaborative enterprise connecting authors, nonprofit publishers, academic institutions, research libraries, and research funders in the common goal of maximizing access to critical research.

## Testicular Myxosporidiasis in the Flat-Backed Toad, *Bufo maculatus* (Amphibia: Bufonidae), from Cameroon, Africa

Steve J. Upton,<sup>1</sup> Paul S. Freed,<sup>2</sup> Deborah A. Freed,<sup>3</sup> Chris T. McAllister,<sup>4</sup> and Stephen R. Goldberg,<sup>5</sup> <sup>1</sup> Division of Biology, Ackert Hall, Kansas State University, Manhattan, Kansas 66506, USA; <sup>2</sup> Section of Herpetology, Houston Zoological Gardens, 1513 North MacGregor Avenue, Houston, Texas 77030, USA; <sup>3</sup> Section of Veterinary Services, Houston Zoological Gardens, 1513 North MacGregor Avenue, Houston, Texas 77030, USA; <sup>4</sup> Renal Metabolic Laboratory (151-G), Department of Veterans Affairs Medical Center, 4500 South Lancaster Road, Dallas, Texas 75216, USA; and <sup>5</sup> Department of Biology, Whittier College, Whittier, California 90608, USA

**ABSTRACT:** Macroscopic cysts measuring  $\leq 860 \times 500 \mu\text{m}$  were found in the testes of a flat-backed toad, *Bufo maculatus*, collected in Cameroon, West Africa. On histologic examination, the cysts contained numerous spores of a *Myxobolus* sp. (Myxozoa: Myxobolidae). Spores in fixed tissues measured  $9.2 \mu\text{m}$  long,  $8.9 \mu\text{m}$  wide, and  $4.0 \mu\text{m}$  thick; the range of values for length, width, and thickness were  $8.8$  to  $9.6 \mu\text{m}$ ,  $8.6$  to  $9.4 \mu\text{m}$ ,  $3.6$  to  $4.4 \mu\text{m}$ , respectively ( $n = 20$ ). The shape index (length/width) was  $1.03$ , and ranged from  $1.00$  to  $1.09$ . Pathology was limited to a slight constriction of adjacent seminiferous tubules by the cysts. No host inflammatory response was noted. This myxozoan is distinct from all other members of the genus infecting anurans and is assigned the name *Myxobolus bufonis* sp. n.

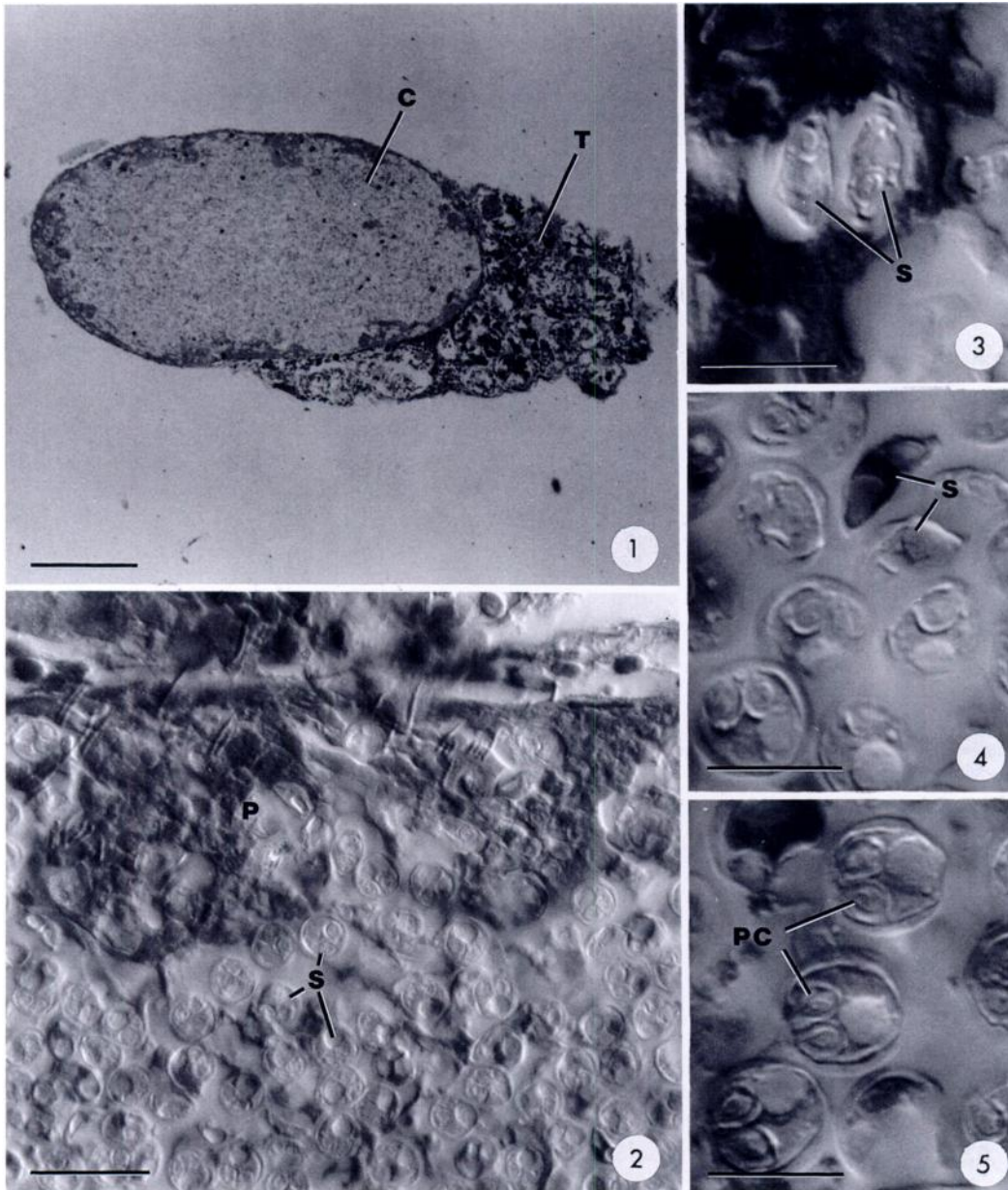
**Key words:** *Myxobolus bufonis* sp. n., testes, *Bufo maculatus*, Cameroon, Africa.

Reports of *Myxobolus* spp. infections in anurans are rare. Fletcher (1888) found a *Myxobolus* sp. in the golden swamp frog, *Hyla auraria* (syn. *H. aurea*), in Sydney, Australia. The parasite was common and subsequently described in more detail (Haswell, 1890; Johnston, 1909; Cleland and Johnston, 1910; Johnston and Bancroft, 1918). It infects testicular, vas efferens, oviduct, and urinary bladder tissues. Johnston and Bancroft (1918) assigned it the name *M. hylae*. Ewers (1973) described *M. chimbuensis* from the testes of the hylid frog, *Litoria darlingtoni*, from New Guinea; Theodorides et al. (1981a, b) reported testicular *Myxobolus* spp. from *Bufo regularis* and the ranid, *Ptychadena maccarthysensis*, in Togo, Africa. The only other *Myxobolus* sp. reported in anurans is *M. ranae*, which forms tumors in the skin of the common grass frog, *Rana tem-*

*poraria*, in Europe (Pfeiffer, 1895; Guyenot and Naville, 1922).

Recently, we observed a case of testicular *Myxobolus* sp. in *Bufo maculatus* ("flat-backed toad"; "striped toad"; "lesser square-backed toad"). The toad was captured by hand in the town of Douala, Cameroon, West Africa ( $4^{\circ}03'N$ ,  $9^{\circ}42'E$ ), in April 1991. The animal was killed and examined both internally and externally for macroscopic parasites. White, oval, macroscopic cysts were seen in the testes. Both testes were stored in 10% formalin. Later, tissues were dehydrated, embedded in paraffin, sectioned at  $7 \mu\text{m}$ , and stained with hematoxylin and eosin. Parasites were examined, photographed, and measured using a photomicroscope equipped with Nomarski and brightfield optics and a calibrated ocular micrometer.

The cysts contained plasmodia and spores of a *Myxobolus* sp. Each cyst (Fig. 1) was filled with thousands of mature spores. The largest cyst in sectioned material measured  $860 \times 500 \mu\text{m}$ . Each cyst was walled off from surrounding seminiferous tubules by a thin connective tissue capsule; fibroblasts were present. Spore development was disporoblastic, the disporoblasts being flattened against the cyst wall (Figs. 2, 3). Spores were disc-shaped, spherical to subspherical in one plane and more flattened when viewed end-on (Figs. 2, 3, 4, 5, 6). Mature spores in histologic sections measured  $9.2 \mu\text{m}$  long,  $8.9 \mu\text{m}$  wide, and  $4.0 \mu\text{m}$  thick. The ranges for length, width, and thickness were  $8.8$  to  $9.6 \mu\text{m}$ ,  $8.6$  to  $9.4 \mu\text{m}$ ,  $3.6$  to  $4.4 \mu\text{m}$ , respectively ( $n = 20$ ). The shape index



FIGURES 1–5. Brightfield (FIG. 1) and Nomarski-interference contrast (FIGS. 2–5) photomicrographs of *Myxobolus bufonis* sp. n. from the testes of *Bufo maculatus* from Cameroon, West Africa. FIG. 1. Cyst (C) in testicular tissue (T). Bar = 200  $\mu\text{m}$ . FIG. 2. Plasmodium (P) adhering to wall of cyst and giving rise to spores (S). Bar = 20  $\mu\text{m}$ . FIG. 3. End-on-views of spores (S) maturing as pairs in plasmodium. Bar = 10  $\mu\text{m}$ . FIG. 4. Cross section of mature spores (S) in cyst showing disc-like shape. Bar = 10  $\mu\text{m}$ . FIG. 5. Top view of mature spores in cyst showing nearly spherical shape and piriform polar capsules (PC). Bar = 10  $\mu\text{m}$ .

(length/width) was 1.03, with a range of 1.00 to 1.09. The sutural ridge was thickened, measuring about 1.0  $\mu\text{m}$  thick; striations on valves were absent. Polar capsules were piriform, 4.1  $\mu\text{m}$  long  $\times$  3.2  $\mu\text{m}$  wide. The range for length and width was 3.4 to 4.6  $\mu\text{m}$  and 3.0 to 3.4  $\mu\text{m}$ , respectively ( $n = 20$ ); there were three to four

coils of polar filament. Sporoplasms were binucleate; few possessed a vacuole. The parasite did not invoke any host inflammatory response, although there was a slight constriction of the seminiferous tubules immediately surrounding the cysts. These seminiferous tubules were still undergoing spermatogenesis. No spores were observed free outside of cysts contained in the testes.

Johnston and Bancroft (1918) reported fixed spores of *M. hylae* to measure 8 to 10  $\mu\text{m}$  wide and 6  $\mu\text{m}$  thick. No length measurements were given, but they did note that some of the spores were spherical, 7 to 8  $\mu\text{m}$  in diameter. Although the measurements reported by Johnston and Bancroft (1918) are similar to those we observed, mature spores of *M. hylae* in their study were both depicted and shown in a photomicrograph as being clearly more elongate than the form we report here. *Myxobolus hylae* also appears to be species specific since it did not occur in sympatric anurans (Cleland and Johnston, 1910; Johnston and Bancroft, 1918). Fixed spores of *M. chimbuensis* measured 10 to 13  $\mu\text{m}$  long  $\times$  8 to 9  $\mu\text{m}$  wide and polar capsules 4 to 6  $\mu\text{m}$  long  $\times$  2 to 3  $\mu\text{m}$  wide. *Myxobolus chimbuensis* also appears to be more elongate than the form described herein. Fixed spores of *M. ranae* measured 11 to 12  $\mu\text{m}$  long and 8 to 10  $\mu\text{m}$  wide, with polar capsules 4 to 5  $\mu\text{m}$  by 2.5 to 3.5  $\mu\text{m}$  (Guyenot and Naville, 1922). *Myxobolus ranae* is larger and more elongate than the form we report here, and does not appear to infect reproductive structures.

Theodorides et al. (1981b) reported fixed spores of *Myxobolus* sp. from *Bufo regularis* in Togo, Africa, to measure about 10  $\mu\text{m}$  long, and 9 to 10  $\mu\text{m}$  wide. These are similar in size to the spores we report. Although no specific measurements were given to the form found in *Ptychadena maccarthiensis*, the authors did report in another portion of the paper that spores from *P. maccarthiensis* (and *B. regularis*) were about 10  $\mu\text{m}$  by 8  $\mu\text{m}$  and had polar capsules about 4  $\mu\text{m}$  by 2.5  $\mu\text{m}$  (Theodori-

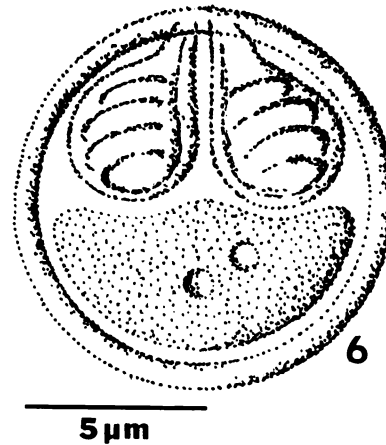


FIGURE 6. Composite line drawing of mature spore of *Myxobolus bufonis* sp. n.

des et al., 1981b). The *Myxobolus* spp. from these two hosts are depicted as having slightly different internal details, which suggests that two distinct species may be involved.

The *Myxobolus* sp. in the present study most closely resembles that reported by Theodorides et al. (1981a, b) from *Bufo regularis* in Togo, although it currently is not possible to determine whether the two represent the same species. However, no named *Myxobolus* sp. from amphibians matches the measurements reported in the present study and we assign the name *Myxobolus bufonis* sp. n. to the parasite of *Bufo maculatus* from Cameroon, West Africa. A histologic section of testes containing a cyst with spores has been deposited in the U.S. National Museum in Beltsville, Maryland, as USNM No. 82035. One author (PSF) thanks the Cameroonian authorities for issuance of collecting and export permits. Thanks also go to Denis Achu, Joe Furman, and Mike Sharp for assistance in collecting the specimen.

#### LITERATURE CITED

- CLELAND, J. B., AND T. H. JOHNSTON. 1910. The haematozoa of Australian batrachians. *Journal of the Royal Society of New South Wales* 44: 252-261.
- EWERS, W. H. 1973. *Myxobolus chimbuensis* n. sp. (Family Myxobolidae, Cnidosporidia, Protozoa)

- from the testes of the hylid frog *Litoria darlingtoni* from New Guinea. *Science in New Guinea* 1: 16–20.
- FLETCHER, A. W. 1888. On a myxosporidian infesting Australian frogs. *Australian Association for the Advancement of Science* 1: 337.
- GUYENOT, E., AND A. NAVILLE. 1922. Sur une myxosporidie (*Myxobolus ranae* n. sp.) et une microsporidie parasites de *Rana temporaria*. *Revue Suisse de Zoologie* 29: 413–425.
- HASWELL, W. A. 1890. A remarkable flat worm in the golden frog. *Proceedings of the Linnean Society of New South Wales* 5: 661–666.
- JOHNSTON, T. H. 1909. Exhibit: *Myxobolus* sp., a sporozoan parasite infesting and destroying the genital organs of the frog *Hyla aurea*. *Journal of the Royal Society of New South Wales* 43(Proceedings and Abstracts): 28–29.
- , AND M. J. BANCROFT. 1918. A parasite, *Myxobolus hylae* sp. nov., of the reproductive organs of the golden swamp frog, *Hyla aurea*. *Australian Zoologist* 1: 171–175.
- PFEIFFER, L. 1895. *Die Protozoan als Krankheitserreger*. Verlag von Gustav Fischer, Jena, Germany, 122 pp.
- THEODORIDES, J., P. PUJOL, F. NEYRAND-DE-LEFFEMBER, AND M. DELSOL. 1981a. New cases of testicular parasitism of amphibians by myxosporidians of the genus *Myxobolus*. *Proceedings of the Zoological Society of France on the Effect of External Factors on Reproductive Cycles: Reproductive Strategies*. 7 to 9 July 1981, Caen, France. *Bulletin de la Societe Zoologique de France* 106: 386.
- , ———, ———, AND ———. 1981b. Nouveaux cas de parasitisme testiculaire d'Amphibiens (*Bufo*, *Ptychadena*) par des Myxosporidies du genre *Myxobolus*. *Annales des Sciences Naturelles, Zoologie, Paris* 3: 63–68.

Received for publication 26 August 1991.