

SUSCEPTIBILITY OF HARES AND RABBITS TO A BELGIAN ISOLATE OF EUROPEAN BROWN HARE SYNDROME VIRUS

Authors: Nauwynck, Hans, Callebaut, Paul, Peeters, Johan, Ducatelle, Rik, and Uyttebroek, Erik

Source: Journal of Wildlife Diseases, 29(2) : 203-208

Published By: Wildlife Disease Association

URL: <https://doi.org/10.7589/0090-3558-29.2.203>

BioOne Complete (complete.BioOne.org) is a full-text database of 200 subscribed and open-access titles in the biological, ecological, and environmental sciences published by nonprofit societies, associations, museums, institutions, and presses.

Your use of this PDF, the BioOne Complete website, and all posted and associated content indicates your acceptance of BioOne's Terms of Use, available at www.bioone.org/terms-of-use.

Usage of BioOne Complete content is strictly limited to personal, educational, and non - commercial use. Commercial inquiries or rights and permissions requests should be directed to the individual publisher as copyright holder.

BioOne sees sustainable scholarly publishing as an inherently collaborative enterprise connecting authors, nonprofit publishers, academic institutions, research libraries, and research funders in the common goal of maximizing access to critical research.

SUSCEPTIBILITY OF HARES AND RABBITS TO A BELGIAN ISOLATE OF EUROPEAN BROWN HARE SYNDROME VIRUS

Hans Nauwynck,¹ Paul Callebaut,¹ Johan Peeters,² Rik Ducatelle,³ and Erik Uyttebroek³

¹ Department of Veterinary Virology, Faculty of Veterinary Medicine, University of Gent, Casinoplein 24, 9000 Gent, Belgium

² National Veterinary Institute, Groeselenberg 99, 1180 Brussel, Belgium

³ Department of Avian Pathology, Faculty of Veterinary Medicine, University of Gent, Casinoplein 24, 9000 Gent, Belgium

ABSTRACT: Signs and pathologic changes of European brown hare syndrome (EBHS) were reproduced in four hares (*Lepus europaeus*) after experimental inoculation of a liver suspension from hares from Belgium, which naturally died of EBHS. Virus particles were demonstrated by electron microscopy in the liver of an experimentally infected hare. They were spherical with a diameter of 28 to 30 nm. After density gradient centrifugation, virus particles were detected in the density zone of 1.34 g/ml. Based on immunoelectron microscopy with a convalescent serum, we identified the virus as the cause of EBHS. Clinical signs were not produced in three seronegative domestic rabbits after subcutaneous inoculation of the EBHS virus. Although low levels of antibodies against EBHS virus were found in the serum of these three rabbits 4 weeks after the inoculation of EBHS virus, the rabbits were not protected when challenged with viral hemorrhagic disease (VHD) virus. The different pathogenicity of the Belgian EBHS and VHD virus isolates in rabbits and the lack of protection in rabbits with circulating EBHS virus antibodies against a challenge with VHD virus indicates that both Belgian virus isolates form two different virus populations.

Key words: *Lepus europaeus*, European brown hare, domestic rabbit, European brown hare syndrome virus, viral hemorrhagic disease virus, experimental inoculations.

INTRODUCTION

High mortality was reported in wild and captive hares in Belgium during the autumn of 1988 and 1989 (Okerman et al., 1989). Affected hares had altered behavior consisting of suppressed flight reaction and disorientation. On necropsy there was icterus and pronounced lobular marking on the surface of the liver. Microscopic lesions were confined primarily to the liver and consisted of periportal or diffuse necrosis of hepatocytes, periportal infiltration of mononuclear cells and hyperplasia of the bile ducts (Uyttebroek et al., 1990). Mortality among hares diminished in Belgium in 1990 and was not observed in 1991.

A similar disease syndrome has been observed in several other European countries including Sweden since 1980 (Gavier and Mörner, 1989), Germany since 1986 (Es-kens et al., 1987), Denmark, Italy and France since 1988 (Henriksen et al., 1989; Lavazza and Vecchi, 1989; Morisse et al., 1990) and Great Britain since 1989 (Chasey and Duff, 1990).

The disease syndrome observed in hares in the different European countries was designated European brown hare syndrome (EBHS). The viral etiology has been described in most of these countries (Es-kens and Volmer, 1989; Henriksen et al., 1989; Lavazza and Vecchi, 1989; Chasey and Duff, 1990; Morisse et al., 1990). The non-enveloped, spherically shaped virus, 28 nm in size, is called the EBHS virus.

In Italy and the south of France, a similar disease was observed in wild and domestic rabbits in the areas where hares were affected by EBHS (Lavazza and Vecchi, 1989). In rabbitries, mortality often reached 80 to 100% and the disease was called viral hemorrhagic disease (VHD). Viral hemorrhagic disease is caused by a non-enveloped and spherically shaped virus, characterized as a member of the *Caliciviridae* (Ohlinger et al., 1989). Morphologic differences were not found between VHD virus and EBHS virus. Such a coincidence of a similar disease affecting both rabbits and hares was not found in

Belgium during the epizootic of EBHS in 1988 and 1989. On the contrary, the first outbreaks of VHD in Belgian rabbits were reported in 1990, when the occurrence of EBHS in hares decreased (Peeters et al., 1990).

The aim of the present study was to reproduce EBHS in hares with a liver suspension from Belgian hares that were naturally infected with EBHS virus and to determine if this Belgian EBHS virus isolate causes disease in rabbits. Moreover, we determined whether rabbits with immunity to EBHS virus were protected against challenge with VHD virus.

MATERIALS AND METHODS

Five captive hares (*Lepus europaeus*), designated H1, H2, H3, H4 and H5, were obtained from a farm with no past history of EBHS. They were males, 6- to 8-mo-old and housed individually in isolation. Hare H1 was inoculated subcutaneously with 2 ml of a centrifuged (10,000 × g) suspension of pooled conjunctivae, lungs and livers, obtained from wild hares with liver lesions of EBHS. Hares H2, H3, H4 and H5 were inoculated with a centrifuged (10,000 × g) suspension of pooled livers, collected from hare H1 and from two captive hares which died of natural EBHS. Diagnosis of EBHS in the latter two hares was based on typical histopathologic liver lesions, namely periportal necrosis of hepatocytes, periportal infiltration of mononuclear cells and hyperplasia of the bile ducts. The liver suspension for inoculation was kept at -70 C. Hares H2 and H3 received 2 ml of the liver suspension subcutaneously. Hare H4 was inoculated subcutaneously with 2 ml of filtered (0.45 μm) liver suspension. Two ml of filtered material was inoculated orally (0.5 ml), intranasally (two times 0.25 ml) and onto the conjunctivae (two times 0.5 ml) in hare H5. All animals were observed daily. Blood was taken from all hares at the time of inoculation and, when they survived, either at the time of euthanasia (hare H1) or 1 and 3 wk after the inoculation (hare H5). Euthanasia was with an intracardiac injection of T 61 (Hoechst Veterinär, Munich, Germany) at a dose of 2 ml/kg.

Ten domestic rabbits, designated R1 to R10, were used either for the inoculation of VHD virus containing material or material collected from hares affected with EBHS. With a hemagglutination inhibition test (Peeters et al., 1990), no serum antibodies against VHD virus were found in these rabbits. Rabbits R1, R2 and R3

were injected subcutaneously with 2 ml of the same liver suspension that was used for the inoculation of hares H2 and H3. Four wk later, these rabbits were challenged subcutaneously with 10³ LD₅₀ VHD virus. This VHD virus was isolated during a Belgian VHD outbreak in 1990. Rabbits R4 to R10 were injected subcutaneously with 10³ LD₅₀ VHD virus containing liver suspension. Rectal body temperatures were taken from all rabbits daily for 5 days after inoculation. Body temperatures >40.5 C were considered as fever. Blood was taken from all rabbits at the time of inoculation and 4 wk later, if they survived. At death, liver samples were subjected to the hemagglutination test, in order to show the presence of VHD virus.

All hares which died or were euthanatized were necropsied. Samples of conjunctiva, trachea, lungs, liver and kidneys were fixed in phosphate-buffered formalin, embedded in paraffin, sectioned at 5 μm and stained with hematoxylin and eosin.

The liver of hare H4 was examined using electron microscopy (EM). A 5% liver suspension in phosphate-buffered saline (PBS) was clarified at 5,000 × g for 30 minutes. The homogenate was layered on a cushion of 30% (w/w) sucrose and formed into a pellet at 200,000 × g for 1.5 hr. The pellet was resuspended in PBS by ultrasonic treatment during 2 × 10 sec (MSE 150 Watt Ultrasonic disintegrator; Crawley, Sussex, England). After clarification, the sample was centrifuged for 17 hr at 200,000 × g in a 30 to 55% linear glycerol potassium tartrate density gradient (Obijeski et al., 1974). Bands visible by light scattering were collected, dialyzed against PBS and used directly for EM and immunoelectron microscopy. Specimens were prepared using 200 mesh formvar coated grids and stained with 2% potassium phosphotungstate, pH 6.1 (Madeley, 1972). They were examined in a Zeiss EM 95-2 microscope (Zeiss, Oberkochen, Germany) at 28,000 power.

Immunoelectron microscopy (IEM) was performed using preinoculation and convalescent sera, obtained from hare H5. Thirty microliters of undiluted serum and 150 μl of purified virus preparation were mixed and incubated at 37 C for 2 hr and 4 C overnight. After centrifugation at 10,000 × g for 30 min, the pellet was resuspended in PBS and prepared for EM as described above.

An agar gel precipitation test was used for detection of EBHS viral antigens. A 20% liver suspension was prepared in PBS. The suspension was centrifuged at 10,000 × g for 10 min. Two parts of the supernatant were mixed with one part of 1,1,2-trichlorotrifluoroethane (Fluka, Buchs, Switzerland). This mixture was shaken vigorously for 1 min and centrifuged at 2,000

$\times g$. The aqueous phase was collected and centrifuged at $14,000 \times g$ for 10 min and the supernatant was used as antigen. Convalescent serum, obtained from a hare that was experimentally infected with EBHS virus, was used as antiserum.

The hemagglutination test (Peeters et al., 1990), using human type O red blood cells, was used for the demonstration of VHD virus in liver suspensions.

Serum antibodies against VHD virus and EBHS virus in hare H5 and rabbits R1, R2 and R3 were determined by a blocking enzyme-linked immunosorbent assay (ELISA) which was performed in the Istituto Zooprofilattico Sperimentale della Lombardia e dell'Emilia-Brescia (Italy) (Capucci et al., 1991). A titer $>1:10$ was considered positive.

Biochemical and enzymatic determinations of total bilirubin, alanine aminotransferase (ALT), aspartate aminotransferase (AST) and γ -glutamyltranspeptidase (γ -GT) were performed on the sera of the experimentally infected hares H1 and H5. The concentration of bilirubin was determined with the bilirubin kit Serapak (Ames-Bayer Diagnostica, Wemmel, Belgium). The concentrations of the enzymes were determined with ALT, AST and γ -GT detection kits of Boehringer Mannheim (Mannheim, Germany).

RESULTS

No clinical signs were observed in hare H1 until 6 days after inoculation when a mucopurulent discharge was seen from the nostrils and the conjunctivae became yellow. At that time the animal was euthanized. Hares H2 and H3 died 2 and 3 days after inoculation, respectively. Suppressed flight reaction and unstable gait were noticed 8 to 12 hr prior to death. Hare H4 died 5 days after inoculation. Suppressed flight reaction was the only clinical sign, observed during 2 days prior to death. Hare H5 had a fluid discharge from the nostrils on the second and third day after inoculation and on the third day, some fibrinous material was present in one eye. This hare survived the infection.

Rabbits R1, R2 and R3 survived the inoculation of EBHS virus containing liver suspension. No changes in rectal body temperature were measured. However, these three rabbits died 2, 4 and 7 days, respec-

tively, after challenge with VHD virus containing material. No fever was measured in rabbit R1, rabbit R2 had fever at 2 and 3 days after inoculation (41 C), and rabbit R3 had a fever at 3 and 4 days after inoculation (41.9 C and 40.6 C, respectively). Rabbits R4 to R10 all died 2 to 5 days after inoculation of VHD virus containing liver suspension. Rabbits R4, R5, R8 and R9 showed no fever. Fever was present the second day after inoculation in rabbit R6 (40.8 C), the second and third day after inoculation in rabbit R7 (41.6 C and 41.4 C, respectively) and the third day after inoculation in rabbit R10 (41.3 C).

The concentrations of ALT, AST, γ -GT and total bilirubin of hare H1 were increased 20-fold at the time of euthanasia, compared to the values obtained prior to inoculation. The concentration of ALT increased from 37 to 737 IU/liter, the concentration of AST from 62 to 1225 IU/liter, the concentration of γ -GT from 10 to 170 IU/liter and the concentration of bilirubin from 6 to 112 μ mole/liter. In hare H5, the concentration of ALT increased from 34 to 125 IU/liter, the concentration of AST from 68 to 183 IU/liter, and no changes were found for the concentrations of γ -GT and total bilirubin.

At necropsy, hare H1 had a yellow discoloration of the subcutis and the aortic intima. Faint petechial hemorrhages and hemorrhagic streaks were seen medially on the thigh and in the dorsal subcutis. There was mucopurulent exudate present in the bronchi. The gross lesions in the liver were minimal, except for an increased marking of interlobular septa. On histopathologic examination, the liver had an infiltration of lymphocytes in portal areas, extensive vacuolation of periportal hepatocytes and proliferation of bile ducts. In the apical lung lobes, a purulent bronchopneumonia was present. Desquamation of bronchiolar epithelial cells was seen in diaphragmatic lung lobes. Hares H2, H3, and H4 had similar pathologic changes. Moderate yellow discoloration was found in the subcutis and the aorta intima. The

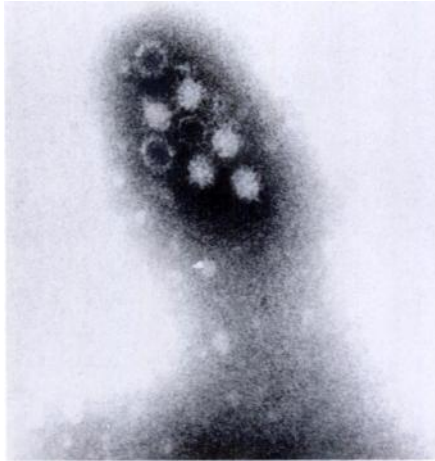


FIGURE 1. Electron micrograph of viral particles, purified from the liver of the EBHS affected hare H4.

liver was congested and friable on palpation. The lobular marking was pronounced. Histologic alterations of the hepatic parenchyma were severe, diffuse and consisted of vacuolar degeneration and individual cell necrosis of hepatocytes and congestion of sinusoids. Liver cells were most severely affected in periportal areas. There was a pinching-off of cytoplasmic droplets from bronchiolar epithelial cells (H2 and H4) and a desquamation of bronchiolar epithelium (H3 and H4).

Following density gradient centrifugation of clarified liver homogenate from hare H4, two closely spaced bands were visible. They were located in the zone of the gradient with density 1.34 g/ml. Under electron microscopy, both bands contained morphologically identical virus particles. The particles appeared roughly spherical and measured 28 to 30 nm in diameter (Fig. 1). They had an indistinct outline and some were penetrated by stain to reveal an electron-dense center. Immune complexes consisting of large ag-

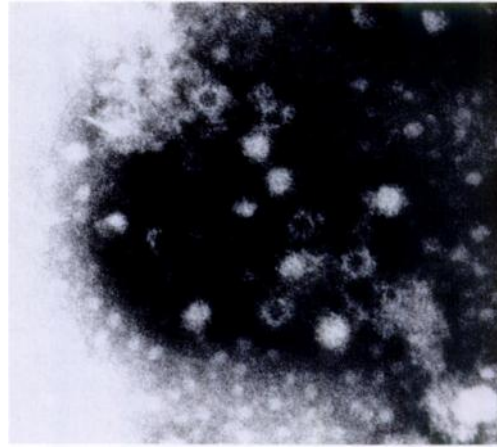


FIGURE 2. Immunoelectron microscopy. Purified viral particles treated with convalescent serum from the EBHS affected hare H5.

gregates of widely spaced particles were observed by IEM (Fig. 2). The virions were surrounded by a fuzzy rim of antibodies. No immune complexes were observed when a preinoculation serum was used to perform IEM.

European brown hare viral antigens were detected in the livers of hares H1, H2, H3 and H4 with the agar gel precipitation test. Precipitation lines were formed with anti-EBHS virus convalescent serum and not with serum from uninoculated hares with the agar gel precipitation assay.

Viral hemorrhagic disease viral antigens were demonstrated with the hemagglutination test in the livers of all the rabbits that died after inoculation of VHD virus containing liver suspension. The hemagglutination was inhibited with a convalescent rabbit serum.

No antibodies against either EBHS virus or VHD virus were detected in hare H5 and rabbits R1, R2 and R3 at the time of the first inoculation. In hare H5, blocking ELISA antibody titers of 1:640 were found to EBHS virus and 1:20 to VHD virus, 3 wk after inoculation of EBHS virus containing liver suspension. Antibody titers of 1:40 were found with the EBHS virus blocking ELISA in rabbits R1, R2, R3, 4 wk after inoculation of EBHS virus con-

taining liver suspension, just before the challenge with VHD virus. Antibodies against VHD virus were not detected in the latter sera.

DISCUSSION

We were able to reproduce EBHS in hares but not in rabbits with a Belgian EBHS virus isolate. Clinical findings in experimentally infected hares were similar to those described in Belgian wild hares (Uyttebroek et al., 1990) and in wild and captive hares from other European countries, after natural or experimental infection (Eskens et al., 1987; Henriksen et al., 1989; Chasey and Duff, 1990). Suppressed flight reaction was the most frequently observed clinical sign prior to death.

Pathologic changes following experimental inoculation were found predominantly in the liver, and were comparable to lesions described by Eskens et al. (1987), Eskens and Volmer (1989), Gavier and Mörner (1989), Okerman et al. (1989) and Uyttebroek et al. (1990). The lesions were characterized by a degeneration of hepatocytes, especially in periportal areas, a hyperplasia of the bile ducts and an infiltration of mononuclear cells. Evidence of hepatocellular disease was given by the increase of the levels of ALT, AST, γ -GT and total bilirubin in serum. The accumulation of bilirubin in the tissues induced a yellow discoloration (icterus).

The virus isolated from Belgian EBHS virus infected hares has a diameter of 28 to 30 nm and a density of 1.34 g/ml. The virus particles were spherical and had regularly distributed cup-shaped depressions at the periphery. The morphology and density of this isolate were similar to those of EBHS virus isolated in Great Britain (Chasey and Duff, 1990) and of VHD virus (Granzow et al., 1989; Ohlinger et al., 1989; Smid et al., 1989; Nowotny et al., 1990; Peeters et al., 1990).

Although the Belgian EBHS virus isolate and VHD virus isolate are morphologically similar, they are quite different viruses based on their pathogenicity for rabbits.

The VHD virus isolate killed rabbits while EBHS virus isolate did not induce any clinical sign.

In the European countries, some discrepancies exist about the susceptibility of rabbits to the virus that is isolated from EBHS-affected hares. In Italy and southern France, affected wild rabbits were found in nature at the same time and in the same regions where EBHS-affected hares were observed. Virus isolated from livers of EBHS-affected hares killed rabbits after experimental inoculation (Morrisse et al., 1990). These observations are in contrast with those made in Belgium, Sweden, Germany, Denmark and Great Britain where disease in hares was not observed concurrently with a similar disease in wild rabbits. In our study and the study of Eskens and Volmer (1989), experimental inoculations of Belgian and German EBHS virus isolates in rabbits did not result in any clinical signs. Based on the difference in pathogenicity of the European EBHS virus isolates for rabbits, variants of EBHS virus must exist. Further examinations are necessary to determine the antigenic relationship among the EBHS virus isolates from the different European countries.

Based on the low titer of VHD virus antibodies found in one hare that received EBHS virus containing liver suspension, we propose that there are common antigenic determinants on the EBHS virus and the VHD virus. Such antigenic relationship between both viruses has been demonstrated by means of monoclonal antibodies (Capucci et al., 1991). Six of eight monoclonal antibodies that are directed against epitopes of VHD virus also reacted with epitopes of EBHS virus.

Low titers of EBHS virus antibodies were found in rabbits after subcutaneous inoculation of EBHS virus. It was impossible to determine whether the antigenic stimulation of the immune system was a result of the inoculum itself without virus replication or was induced by a limited degree of virus replication. This low level of EBHS

virus antibodies did not protect rabbits after the challenge with VHD virus. Based on the lack of protection, the Belgian EBHS virus isolate differed from the VHD virus isolate. This may be explained by the absence of common neutralizing epitopes. Capucci et al. (1991) demonstrated that of the eight neutralizing monoclonal antibodies produced against VHD virus, the two neutralizing monoclonal antibodies did not react with EBHS virus.

ACKNOWLEDGMENTS

This study was supported by grant LI/GWB/1990-007 of the Flemish Executive Government (Ministerie van Leefmilieu, Natuurbehoud en Landinrichting van de Vlaamse Executieve) and gifts of the hunters associations: Fédération des associations de chasseurs de la CEE (FACE), Koninklijke Sint-Hubertus Club België (KSHCB) and West-Vlaamse Jagersvereniging (WVJV). The performance of the serologic examinations by L. Capucci and A. Lavazza (Istituto Zooprofilattico Sperimentale della Lombardia e dell'Emilia-Brescia) is gratefully acknowledged.

LITERATURE CITED

- CAPUCCI, L., M. T. SCICLUNA, AND A. LAVAZZA. 1991. Diagnosis of viral haemorrhagic disease of rabbits and the European brown hare syndrome. In *Maladie hémorragique virale du lapin et syndrome du lièvre brun européen*. Revue Scientifique et Technique—Office International des Epizooties 10: 347–370.
- CHASEY, D., AND P. DUFF. 1990. European brown hare syndrome and associated virus particles in the UK. *The Veterinary Record* 126: 623–624.
- ESKENS, U., AND K. VOLMER. 1989. Untersuchungen zur Ätiologie der Leberdystrophie des Feldhasen (*Lepus europaeus pallas*). *Deutsche Tierärztliche Wochenschrift* 96: 433–472.
- , H. KLIMA, J. NILZ, AND D. WIEGAND. 1987. Leberdystrophie bei Hasen. Pathologie und epidemiologische Untersuchungen eines Feldhasensterbens in Mittelhessen. *Tierärztliche Praxis* 15: 229–235.
- GAVIER, D., AND T. MÖRNER. 1989. The European brown hare syndrome in Sweden. Verhandlungsbericht des 31. Internationalen Symposiums über die Erkrankungen der Zoo- und Wildtiere (Dortmund); Akademie-verlag, Berlin, West Germany, pp. 261–264.
- GRANZOW, H., H. SCHIRMEIER, AND G. TEWS. 1989. Hämorrhagische Septikämie der Kaninchen—Erregernachweis und erste elektronenmikroskopische Charakterisierung. *Monatshefte für Veterinärmedizin* 44: 379–380.
- HENRIKSEN, P., D. GAVIER, AND F. ELLING. 1989. Acute necrotising hepatitis in Danish farmed hares. *The Veterinary Record* 125: 486–487.
- LAVAZZA, A., AND G. VECCHI. 1989. Osservazioni su alcuni episodi di mortalità nella lepre evidenziazione al microscopio elettronico di una particella virale. *Estratto da Selezione Veterinaria* 3: 461–468.
- MADELEY, C. R. 1972. *Virus morphology*. Churchill Livingstone, Teviot Place, Edinburgh, United Kingdom, 179 pp.
- MORISSE, J. P., J. P. PICAULT, E. BOILLETOT, AND M. MORIN. 1990. Relations étiologiques entre le syndrome du lièvre brun européen (EBHS) et la maladie hémorragique virale du lapin (VHD). *Cuniculture* 95: 215–220.
- NOWOTNY, N., A. FUCHS, F. SCHILCHER, AND G. LOUPAL. 1990. Zum Auftreten der Rabbit Haemorrhagic Disease (RHD) in Österreich: I. Pathomorphologische und virologische Untersuchungen. *Wiener Tierärztliche Monatschrift* 77: 19–23.
- OBJESKY, J. F., A. T. MARCHENKO, D. H. L. BISHOP, B. W. CANN, AND F. A. MURPHY. 1974. Comparative electrophoretic analysis of the virus proteins of four rhabdoviruses. *Journal of General Virology* 22: 21–33.
- OHLINGER, V. F., B. HAAS, R. AHL, AND F. WEILAND. 1989. Die infektiöse hämorrhagische Krankheit der Kaninchen—Eine durch ein Calicivirus verursachte Tierseuche. *Tierärztliche Umschau* 5: 284–294.
- OKERMAN, L., P. VAN DE KERCKHOVE, S. OSAER, L. DEVRIEZE, AND E. UYTTEBROEK. 1989. European brown hare syndrome bij in gevangenschap levende hazen (*Lepus capensis*) in België. *Vlaams Diergeneeskundig Tijdschrift* 58: 44–46.
- PEETERS, J. E., A. BROES, AND G. CHARLIER. 1990. Premières observations de la maladie hémorragique virale du lapin (RHD) en Belgique. *Annales de Médecine Vétérinaire* 134: 567–571.
- SMID, B., L. VALICEK, J. STEPANEK, E. JURAK, AND L. RODAK. 1989. Experimental transmission and electron microscopic demonstration of the virus of haemorrhagic disease of rabbits in Czechoslovakia. *Journal of Veterinary Medicine B* 36: 237–240.
- UYTTEBROEK, E., H. NAUWYNCK, R. DUCATELLE, P. CALLEBAUT, AND G. CHARLIER. 1990. Pathology and etiology of natural and experimental European Brown Hare Syndrome. *Schweizer Archiv für Tierheilkunde* 132: 478–479.

Received for publication 9 March 1992.