

Naturally Occurring *Brucella suis* Biovar 4 Infection in a Moose (*Alces alces*)

Authors: Honour, Sandra, and Hickling, Keith M. H.

Source: Journal of Wildlife Diseases, 29(4) : 596-598

Published By: Wildlife Disease Association

URL: <https://doi.org/10.7589/0090-3558-29.4.596>

BioOne Complete (complete.BioOne.org) is a full-text database of 200 subscribed and open-access titles in the biological, ecological, and environmental sciences published by nonprofit societies, associations, museums, institutions, and presses.

Your use of this PDF, the BioOne Complete website, and all posted and associated content indicates your acceptance of BioOne's Terms of Use, available at www.bioone.org/terms-of-use.

Usage of BioOne Complete content is strictly limited to personal, educational, and non - commercial use. Commercial inquiries or rights and permissions requests should be directed to the individual publisher as copyright holder.

BioOne sees sustainable scholarly publishing as an inherently collaborative enterprise connecting authors, nonprofit publishers, academic institutions, research libraries, and research funders in the common goal of maximizing access to critical research.

Naturally Occurring *Brucella suis* Biovar 4 Infection in a Moose (*Alces alces*)

Sandra Honour¹ and Keith M. H. Hickling,² ¹ Department of Pathology, Western College of Veterinary Medicine, University of Saskatchewan, Saskatoon, SK, Canada; ² Department of Renewable Resources, Government of the Northwest Territories, Inuvik, NWT, Canada

ABSTRACT: A debilitated adult female moose (*Alces alces*) shot east of the MacKenzie River, Northwest Territories, Canada, had large fluctuant masses over both carpi. Only the forelimbs were available for examination. Carpal pathology included bilateral bursitis and osteomyelitis of subjacent bone. In addition severe osteomyelitis with fractures was observed in the left lateral and right medial digits. *Brucella suis* biovar 4 was isolated from the right medial first phalanx. This is believed to be the first reported case of infection with this organism in a wild moose. The bacterium is common in caribou (*Rangifer tarandus*) in the region.

Key words: Moose, *Alces alces*, brucellosis, *Brucella suis* biovar 4, case report.

Brucellosis in moose (*Alces alces*) rarely has been reported. Based on serological studies, some workers suggest a low prevalence of exposure to *Brucella* spp. among moose (Hudson et al., 1980; Zarnke, 1983; Bourque and Higgins, 1984; Kocan et al., 1986). *Brucella abortus* has been isolated from naturally occurring infections in moose, and pericarditis, pleuritis, peritonitis, lymphadenitis, arteritis, and septicemia were the suggested causes of death in these cases (Jellison et al., 1953). Moose experimentally infected with *B. abortus* developed fibrinous pleuritis and peritonitis, multifocal necrotic hepatitis suggestive of endotoxemia, and granulomatous lymphadenitis (S. Tessaro, pers. comm.). *Brucella suis* biovar 4, common in caribou (*Rangifer tarandus*) in northern Canada, causes bursitis, abortion, arthritis, osteomyelitis, hygroma, orchitis, mastitis, tenosynovitis, subcutaneous abscessation and mineralized granulomas in various organs (Tessaro and Forbes, 1986). Transmission of *B. suis* biovar 4 among caribou may occur by ingestion of post-parturient or aborted infective tissues or fluids. The significance of venereal transmission and in-

gestion of infected milk is unknown. Moose experimentally infected with *Brucella suis* biovar 4 developed severe, fatal septicemia with focal splenic necrosis and edematous lymph nodes observed at necropsy (Dieterich et al., 1991). Moose and caribou are sympatric in northern Canada, but calving grounds of caribou are not high density moose habitat (Banfield, 1977). Although exposure of moose to *B. suis* biovar 4 is possible, no natural infections have been reported in moose.

In February 1992, a trapper found a debilitated adult female moose 55 km upriver from the community of Arctic Red River on the east bank of the MacKenzie River in the Northwest Territories (NWT) of Canada (67°18'N, 132°39'W). The emaciated cow was kneeling in the snow when found and appeared to have been at that site for some time. The trapper shot the moose, which did not move away or run when approached. When examining the carcass, he noticed that the carpal regions of both forelimbs were swollen and reported this incident to the Department of Renewable Resources, Inuvik, NWT. Several days later, he removed the affected front limbs and sent them to Inuvik.

The frozen forelimbs were sent to the Diagnostic Pathology Laboratory, Western College of Veterinary Medicine, Saskatoon, Saskatchewan, Canada, for examination. Body condition was assessed using a dry-weight method on femur marrow fat (Neiland, 1970). A weighed portion of the metacarpal marrow was air-dried at 21 C until there was no further reduction in weight. The residue weighed less than 5% of the original weight; thus, little or no fat was present (Hunt, 1979). There were swellings near both left and

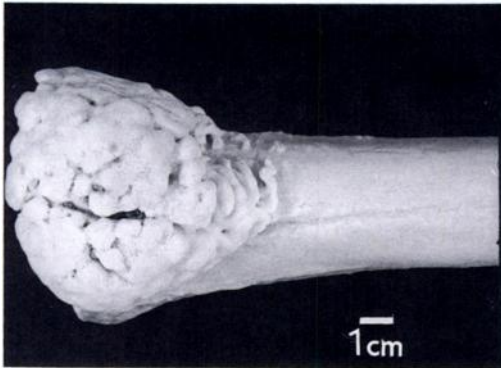


FIGURE 1. Portion of proximal left metacarpal (tissue removed by boiling) with extensive osteophyte proliferation. H&E.

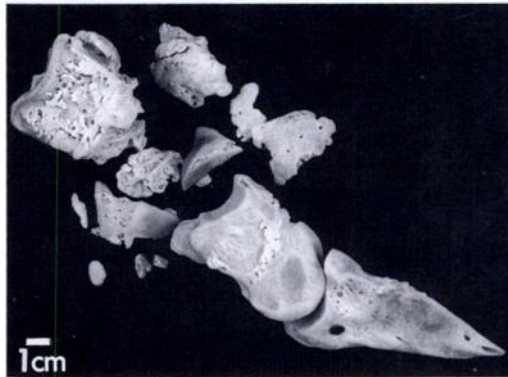


FIGURE 2. Medial aspect of right medial phalanges with osteophytes apparent on all three phalanges and severe comminuted fractures of the first phalanx. H&E.

right carpi and the right medial digit. The right carpal bursa was dilated to 10 cm by 7 cm by 3 cm, thick walled and flaccid. The left carpal bursa was enlarged to 10 cm by 6 cm by 3 cm and contained approximately 150 ml of tenacious, translucent fluid with fibrin clots. This bursa overlaid a 6 cm by 5 cm bony mass that was continuous with the metacarpal bone (Fig. 1). Bony masses contiguous with the dorsal surfaces of both metacarpi were formed from clusters of firm, white, roughened, 0.2 to 0.5 cm diameter nodules. The left second and third fused carpal and ulnar carpal bones had osteophytes on their outer edges. Osteophytes were found on the right medial digit phalanges and the left lateral digit second and third phalanges. Several pieces of bone were free within the interphalangeal (P1-P2) joint of the right medial digit and there were severe comminuted fractures of the first phalanx (Fig. 2). The left lateral second phalanx had severe erosions of the articular surfaces and the distal portion was fractured.

Tissues for histological evaluation were fixed in 10% phosphate buffered formalin for several days. Bone was decalcified in 20% formic acid for 48 hr after fixation and prior to paraffin embedding, sectioning, and staining with hematoxylin and eosin.

Histologically, the internal wall of the carpal bursa had villous projections and

was thickened with fibrous tissue and macrophages. The plantar surface of the metacarpals had periosteal proliferation forming spongy bone. A layer of highly vascularized fibrous tissue containing fragments of osteoid and yellow brown pigment overlay the reactive periosteum. Osteoclasts surrounded small foci of necrotic, acellular osteoid, while the medullary cavity of the metacarpus contained multiple mineralized foci.

Fluid and tissue from right and left carpal bursa walls, right metacarpal marrow, an osteophyte of the right medial first phalanx, and a swab of the fracture site of the right medial first phalanx were used for bacteriologic examination. Direct smears of these tissues stained with Koster's stain (Carter, 1990) were negative. Samples were inoculated on 50% sheep blood agar plates and incubated at 37 C for 5 days in a 5% carbon dioxide enriched atmosphere. Bacteria were isolated from the swab and fractured bone. Koster's staining of isolates was positive for *Brucella* spp. Cultures and samples were then sent to the Agriculture Canada Health of Animals Laboratory, Saskatoon, Saskatchewan, for further testing. Using methods of Forbes and Panteoek (1988) the isolates from the moose were identified as *B. suis* biovar 4.

We believe that the severe lesions on the forelimbs impeded the moose's movement

and contributed to her emaciated condition. It is not known whether *B. suis* caused lesions in other tissues nor whether concurrent disease of other etiology was present. The articular lesions in this moose were similar to those caused by *B. suis* biovar 4 in caribou.

Others have postulated that the low prevalence of moose seroreactors to *Brucella* spp. may be due to acute severe and fatal disease, inherent resistance to the disease, or to a low rate of exposure to the bacteria (Jellison et al., 1953; Zarnke, 1983). There is experimental evidence that brucellosis is fatal in moose (Dieterich et al., 1991; S. Tessaro, pers. comm.). Based on the lesions in this natural case of *B. suis* biovar 4 infection in a moose, the disease can occur in a more chronic form. Further research is needed to improve the understanding of brucellosis in moose.

We thank Mr. Gabe Andre, the trapper who supplied the specimens, Dr. Lorry Forbes of Agriculture Canada Health of Animals Laboratory (ACHA), Saskatoon for biotyping the isolates and Dr. Stacy Tessaro of ACHA for his information and editing.

LITERATURE CITED

- BANFIELD, A. W. F. 1977. Order Pinnipedia. In *The mammals of Canada*, A. W. F. Banfield (ed.). University of Toronto Press, Toronto, Canada, pp. 383 and 397.
- BOURQUE, M., AND R. HIGGINS. 1984. Serological studies on brucellosis, leptospirosis, and tularemia in moose (*Alces alces*) in Quebec. *Journal of Wildlife Diseases* 20: 95-99.
- CARTER, G. R. 1990. Staining procedures. In *Diagnostic procedures in veterinary bacteriology and mycology*, 5th ed., G. R. Carter and J. R. Cole, Jr. (eds.). Academic Press Inc., San Diego, California, p. 525.
- DIETERICH, R. A., J. K. MORTON, AND R. L. ZARNKE. 1991. Experimental *Brucella suis* biovar 4 infection in a moose. *Journal of Wildlife Diseases* 27: 470-472.
- FORBES, L. B., AND J. F. PANTEKOEK. 1988. *Brucella canis* isolates from Canadian dogs. *Canadian Veterinary Journal* 29: 149-152.
- HUDSON, M., K. N. CHILD, D. F. HATLER, K. K. FUJINO, AND K. A. HUDSON. 1980. A serological survey in an open range cattle area of north central British Columbia recently infected with bovine brucellosis. *Canadian Veterinary Journal* 21: 47-49.
- HUNT, H. M. 1979. Comparison of dry-weight methods for estimating elk femur marrow fat. *The Journal of Wildlife Management* 43: 560-563.
- JELLISON, W. L., C. W. FISHEL, AND E. L. CHEATUM. 1953. Brucellosis in a moose, *Alces americanus*. *The Journal of Wildlife Management* 17: 217-218.
- KOCAN, A. A., A. W. FRANZMANN, K. A. WALDRUP, AND G. J. KUBAT. 1986. Serological studies of selected infectious diseases of moose (*Alces alces*) from Alaska. *Journal of Wildlife Diseases* 22: 418-420.
- NEILAND, K. A. 1970. Weight of dried marrow as indicator of fat in caribou femurs. *The Journal of Wildlife Management* 34: 904-907.
- TESSARO, S., AND L. B. FORBES. 1986. *Brucella suis* biotype 4: A case of granulomatous nephritis in a barren ground caribou (*Rangifer tarandus groenlandicus* L.) with a review of the distribution of rangiferine brucellosis in Canada. *Journal of Wildlife Diseases* 22: 479-483.
- ZARNKE, R. L. 1983. Serological survey for selected microbial pathogens in Alaskan wildlife. *Journal of Wildlife Diseases* 19: 324-329.

Received for publication 24 November 1992.