



Squamous Cell Carcinoma of the Skin in a Père David's Deer (*Elaphurus davidianus*)

Authors: Agrimi, U., Morelli, L., and Di Guardo, G.

Source: Journal of Wildlife Diseases, 29(4) : 616-617

Published By: Wildlife Disease Association

URL: <https://doi.org/10.7589/0090-3558-29.4.616>

BioOne Complete (complete.BioOne.org) is a full-text database of 200 subscribed and open-access titles in the biological, ecological, and environmental sciences published by nonprofit societies, associations, museums, institutions, and presses.

Your use of this PDF, the BioOne Complete website, and all posted and associated content indicates your acceptance of BioOne's Terms of Use, available at www.bioone.org/terms-of-use.

Usage of BioOne Complete content is strictly limited to personal, educational, and non - commercial use. Commercial inquiries or rights and permissions requests should be directed to the individual publisher as copyright holder.

BioOne sees sustainable scholarly publishing as an inherently collaborative enterprise connecting authors, nonprofit publishers, academic institutions, research libraries, and research funders in the common goal of maximizing access to critical research.

Squamous Cell Carcinoma of the Skin in a Père David's Deer (*Elaphurus davidianus*)

U. Agrimi,¹ L. Morelli,¹ and G. Di Guardo,^{2,3} ¹ Istituto Superiore di Sanità, Laboratorio di Medicina Veterinaria, Viale Regina Elena, 299, 00161, Rome, Italy; ² Istituto Zooprofilattico Sperimentale delle Regioni Lazio e Toscana, Via Appia Nuova, 1411, 00178, Rome, Italy; ³ Author to whom reprint requests should be sent

ABSTRACT: A solitary mass overlying the right carpal joint region's skin in an 18-year-old female Père David's deer (*Elaphurus davidianus*) was surgically excised and histologically diagnosed as a squamous cell carcinoma (SCC). The tumor was locally infiltrative, showing rather few "horn pearls" and many mitotic figures. This is the first report of a cutaneous SCC in the Père David's deer.

Key words: Squamous cell carcinoma, tumor, skin, deer, Père David's deer, *Elaphurus davidianus*.

A captive 18-year-old female subject belonging to Père David's deer species (*Elaphurus davidianus*) from the Zoological City Park of Rome, Italy showed a prominent and slowly growing cutaneous mass overlying the right carpal region. The animal was cachectic and exhibited severe lameness involving the forelimb affected by the mass, which was surgically removed. However, several weeks after surgery the deer was euthanatized due to persistent emaciation and weakness; it was given an intravenous injection of 5 ml Tanax (Holchst Italia S.p.A, Milan, Italy). A necropsy could not be performed. During surgery, representative tissue samples were collected from the mass and immediately fixed in 10% neutral buffered formalin. These were subsequently embedded in paraffin, sectioned at 5 μ m and stained with hematoxylin and eosin (H&E). The case was deposited in an official tumor registry (Animal Tumor Registry case accession number RT796, Istituto Superiore di Sanità, Laboratorio di Medicina Veterinaria, Rome, Italy).

Macroscopically, the mass had a fibrous appearance and an irregular corrugated surface, with variably sized erosions, ul-

cerations, and hemorrhages. On cut section, necrotic and hemorrhagic foci were observed.

Histologically, the neoplasm consisted of multiple clusters and cords of proliferating squamous cells diffusely invading the dermis and subcutis (Fig. 1). The overlying epidermis was markedly hyperkeratotic and dyskeratotic. Inflammatory aggregates were all throughout the tumor, neoplastic squamous cells being within a dense fibrous connective tissue network. "Horn pearls" were generally uncommon (Fig. 2). Tumor elements were pleomorphic, showing poorly distinct borders, abundant eosinophilic cytoplasm, and round to oval, vesicular nuclei with one or two prominent nucleoli. Many mitotic figures could be observed. Individual cells with abundant, strongly eosinophilic cytoplasm and pyknotic nuclei were occasionally seen undergoing keratinization. Neoplastic cells could not be documented in the lumen of any lymphatic or blood vessel.

On the basis of the above findings, a diagnosis of a locally invasive squamous cell carcinoma (SCC) was made.

A SCC is a malignant cutaneous and extra-cutaneous neoplasm, especially common in adult and aged animals. It affects all domestic species, but most frequently dogs, cats, horses, and cows (Pulley and Stannard, 1990). The SCC is a locally invasive and slowly metastasizing tumor, although widespread metastasis can be occasionally observed in dogs (Pulley and Stannard, 1990).

Spontaneous neoplasms are uncommon in deer. Among these, cutaneous fibromas, fibropapillomas, neurofibromas, warts, and

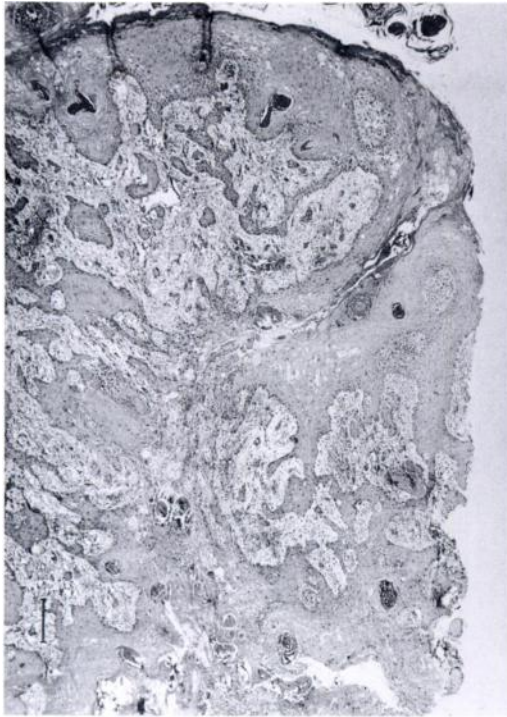


FIGURE 1. Père David's deer (*Elaphurus davidianus*). Skin. Squamous cell carcinoma. Clusters and cords of neoplastic epithelial cells are seen infiltrating the dermis and subcutis. H&E. Bar = 180 μ m.

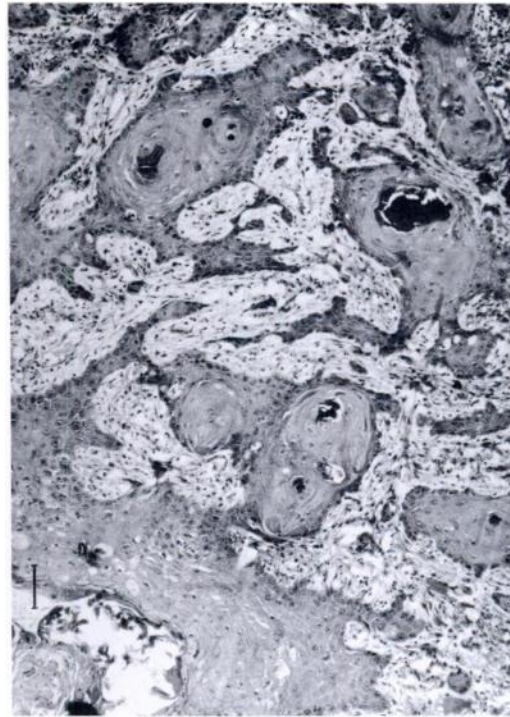


FIGURE 2. Père David's deer (*Elaphurus davidianus*). Skin. Squamous cell carcinoma. Neoplastic cells showing "horn pearl" formation. H&E. Bar = 72 μ m.

fibrosarcomas, all grouped under the common denomination of "fibropapillomas," have been reported and successfully transmitted to deer by means of cell-free filtrate (Clark, 1973).

To our knowledge, this is the first description of a cutaneous SCC in the Père David's deer (*Elaphurus davidianus*); only a subcutaneous fibrosarcoma previously has been reported in this species (Hubbard et al., 1983).

We thank Drs. A. Croce and C. Melis for referring us to the case (Animal Tumor Registry case accession number RT796, Is-

tituto Superiore di Sanità, Laboratorio di Medicina Veterinaria, Rome, Italy).

LITERATURE CITED

- CLARK, K. A. 1973. Neoplasms of wild animals. *Southwestern Veterinarian* 26: 185-188.
- HUBBARD, G. B., K. C. FLETCHER, AND R. E. SCHMIDT. 1983. Fibrosarcoma in a Père David's deer. *Veterinary Pathology* 20: 779-781.
- PULLEY, L. T., AND A. A. STANNARD. 1990. Tumors of the skin and soft tissues. In *Tumors in domestic animals*, 3rd ed., J. E. Moulton (ed.). University of California Press, Berkeley, California, pp. 23-87.

Received for publication 9 March 1993.