

## Parasites of Wild Felidae in Thailand: A Coprological Survey

Sharon Patton<sup>1</sup> and Alan R. Rabinowitz,<sup>2</sup> <sup>1</sup> Department of Environmental Practice, College of Veterinary Medicine, P.O. Box 1071, University of Tennessee, Knoxville, Tennessee 37901-1071; <sup>2</sup> Wildlife Conservation International, New York Zoological Society, Bronx Zoo, New York, New York 10460

**ABSTRACT:** Ninety-two fecal samples were collected from leopards (*Panthera pardus*,  $n = 54$ ), tigers (*P. tigris*,  $n = 19$ ), and leopard cats (*Felis bengalensis*,  $n = 3$ ) in Huai Kha Wildlife Sanctuary, Thailand; four samples that may have come from clouded leopards (*Neofelis nebulosa*) or Asian golden cats (*Felis temminicki*) were identified as from small to medium cats. Twelve samples were identified as from large cats. Samples preserved in 10% formalin were examined for parasite eggs, larvae, cysts, and oocysts by centrifugal sugar flotation and sedimentation techniques. Ninety-six percent of all samples were positive, including 94% of the leopard, all of the tiger, clouded leopard, golden cat, and leopard cat samples. Diagnostic stages were identified from *Paragonimus* sp., Echinostomatidae, Dicrocoeliidae, Pseudophyllidae, Taeniidae, *Mesocostoides* sp., Hymenolepididae, Acanthocephala, Spiruroidea, *Gnathostoma* sp., *Molineus* sp., Ancylostomoidea, *Mammomonogamus* sp., *Toxocara* sp., *Toxascaris* sp., Metastrongyloidea, *Capillaria* spp., *Isospora* sp., *Toxoplasma*-like, *Sarcocystis* spp., and *Giardia* sp.

**Key words:** Endoparasites, tropical felidae, tiger, leopard cat, leopard, clouded leopard, Asian golden cat, Thailand.

Our objective was to identify the parasites in a community of wild felidae in Huai Kha Wildlife Sanctuary, Thailand (15°00' to 15°45'N, 99°30'E). The study area was a dry tropical forest of 100 km<sup>2</sup> around Khao Nang Rum Research Station. From 1987 to 1989 feces were collected along roads, trails, waterways, and salt licks, and from cats captured in traps. When defecation was not observed, feces were differentiated by size, tracks in the area, and the presence of scrapes associated with them (Rabinowitz and Walker, 1991). Feces mixed with an equal volume of 10% formalin were examined for parasite eggs, larvae, cysts, and oocysts by sugar flotation (specific gravity 1.275) (Georgi and Geor-

gi, 1990) and sedimentation with formalin-ethyl acetate (Young et al., 1979). Parasite products were measured with a microscope equipped with a calibrated eyepiece micrometer (Micro Imaging Inc., Nashville, Tennessee, USA) and identified based on size and morphology. References used for identification were Agrawal et al., 1981; Soulsby, 1982; Beaver et al., 1984; Patton et al., 1986; Dubey et al., 1989; and Georgi and Georgi, 1990.

Ninety-two fecal samples were collected from leopards (*Panthera pardus*,  $n = 54$ ), tigers (*P. tigris*,  $n = 19$ ), and leopard cats (*Felis bengalensis*,  $n = 3$ ); four samples that may have come from clouded leopards (*Neofelis nebulosa*) or Asian golden cats (*Felis temminicki*) were identified as from small to medium cats. Twelve samples were identified as from large cats (Table 1).

Eighty-eight (96%) of the 92 samples were positive, including 94% of the leopard, all of the tiger, clouded leopard, golden cat, and leopard cat samples (Table 1). The number of species per sample ranged from one to nine, with five to seven different species in small to medium and leopard cats, and one to nine different species in leopards and tigers.

Three types of trematode eggs were identified: *Paragonimus* spp. (Fig. 1), the lung fluke (Table 1); Echinostomatid intestinal flukes (Fig. 1), perhaps *Echinostoma ilocanum* or *Echinochasmus perfoliatus*; and reddish-brown, embryonated, Dicrocoeliid eggs, 40 to 50  $\mu\text{m} \times 20$  to 32  $\mu\text{m}$ , possibly *Platynosum*, a parasite of the liver and bile ducts of felidae in Malaysia and other countries (Soulsby, 1982). *Paragonimus* spp. and the intestinal

TABLE 1. Prevalence of parasite eggs, larvae, cysts, and oocysts in 92 fecal samples from leopards, tigers, clouded leopards, golden cats, and leopard cats in Huai Kha Wildlife Sanctuary, Thailand. Some feces were identified only as from large cats (tiger or leopard) or small or medium cats (clouded leopard, golden cats).

	Leopards (n = 54)	Tigers (n = 19)	Leopard cats (n = 3)	Unidentified cats	
				Large (n = 12)	Small to medium (n = 4)
<i>Paragonimus</i> sp.	28*	12	0	4	1
Echinostomatidae	4	0	2	1	1
Dicrocoeliidae	7	1	0	2	0
Pseudophyllidea	19	11	0	2	1
Taeniidae	3	1	0	0	0
<i>Mesocestoides</i> sp.	0	0	0	0	1
Hymenolepididae	2	1	1	0	0
Acanthocephala	4	0	0	2	0
Spiruroidea	15	4	3	3	2
<i>Gnathostoma</i> sp.	1	0	0	0	0
<i>Molineus</i> sp.	3	2	0	0	0
Ancylostomoidea	27	7	1	7	2
<i>Mammomonogamus</i> sp.	9	2	3	0	1
<i>Toxocara</i> -like	18	3	0	0	1
<i>Toxascaris</i> sp.	4	2	0	0	1
<i>Aelurostrongylus</i> sp.	30	14	3	9	3
<i>Capillaria</i> spp.	26	13	3	16	3
<i>Isospora</i> -like					
32 × 40 μm	2	0	1	1	0
20 × 20 μm	4	0	0	2	0
<i>Toxoplasma</i> -like	1	0	0	1	0
<i>Sarcocystis</i> spp.	11	7	0	2	1
<i>Giardia</i> sp.	1	0	0	0	0

\* Number of samples containing this type of parasite egg, larva, cyst, or oocyst.

flukes are endemic in people and animals in Thailand (Beaver et al., 1984). Crabs, the second intermediate hosts for *Paragonimus* spp, previously were identified from the feces of these cats (Rabinowitz and Walker, 1991).

Most of the Pseudophyllidean tapeworm eggs, 50 to 60 μm × 30 to 40 μm, were *Spirometra* sp.; four samples contained broader, rounder eggs that possibly were *Diphyllobothrium* sp. (Yamaguti, 1963a). Both are zoonotic and reported from carnivorous mammals in Asia and the South Pacific (Beaver et al., 1984; Yasuda et al., 1993). Animals ingest the infective stage (pleurocercoids) in fish (*Diphyllobothrium* spp.) or rodents and reptiles (*Spirometra* spp.). Three types of Cyclophyllidean cestode eggs were identified: Taeniid-type (40 × 35 μm), probably *Tae-*

*nia taeniaformis* or another *Taenia* spp. reported from felids in Asia and Africa (Schmidt, 1986) which are acquired by eating infected mammals; *Mesocestoides* sp. whose infective stage is found in mammals, birds, and reptiles (Schmidt, 1986); and Hymenolepid-type, 50 × 50 μm, previously reported from dogs and cats but usually in birds and rodents (Georgi and Georgi, 1990).

Acanthocephalan eggs (Fig. 1) probably were from *Oncicola* spp., *Pseudoporrorchis* spp., *Echinopardalis* spp., or *Neonnicola* known to infect carnivores in this area (Yamaguti, 1963c; Schmidt and Dunn, 1974).

Thick-shelled, larvated spirurid eggs (40 to 65 μm × 15 to 35 μm) (Fig. 1) probably were from *Physaloptera* sp., *Pterygondermaties* sp., *Cylicospirura* sp., *Cyathospirura* sp., or *Spirocerca* sp. (Yamaguti,

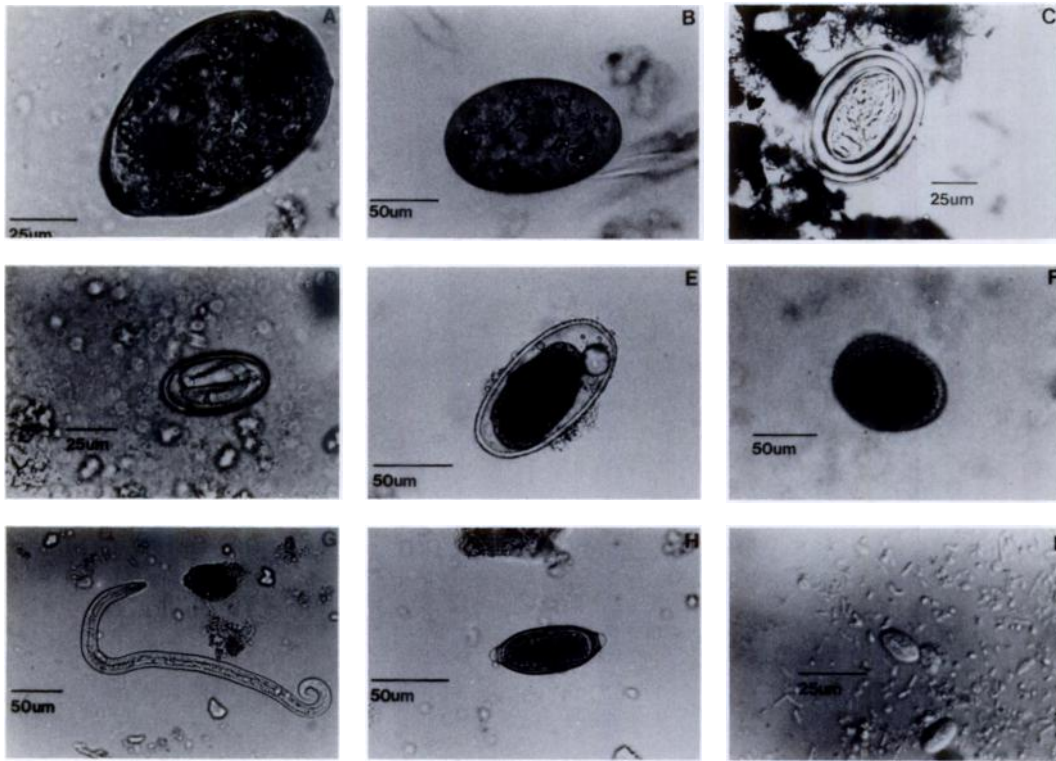


FIGURE 1. Eggs, cysts and larvae recovered from feces of wild felidae in Thailand. *Paragonimus* sp. (A), Echinostomatidae (B), and acanthocephalan eggs (C) from leopards. Spirurid egg (D) from tiger. *Mammomonogamus* egg (E) from leopard cat. Ascarid egg (F) and metastrongylate larva (G) from leopards. *Capillaria* spp. egg (H) from tiger. *Giardia* cyst (I) from leopard (interference contrast image).

1963b). Intermediate (arthropods) or paratenic hosts (mammals, birds, reptiles) contain infective larvae. *Gnathostoma* spp. (eggs  $60 \times 35 \mu\text{m}$ ) previously were reported from wild and domestic cats in Thailand where human gnathostomiasis is endemic (Beaver et al., 1984).

Strongylid eggs were placed in three groups: small, ellipsoidal eggs ( $50$  to  $52 \mu\text{m} \times 20$  to  $40 \mu\text{m}$ ) with many small blastomeres, probably *Molineus* sp. previously reported from wild felidae (Yamaguti, 1963b); oval eggs ( $55 \times 35 \mu\text{m}$  to  $75 \times 45 \mu\text{m}$ ) with fewer blastomeres, identified as hookworm eggs possibly *Ancylostoma tubaeforme*, *A. ceylanicum* or other hookworms that parasitize Asian carnivores (Yamaguti, 1963b); or large *Mammomonogamus* sp. (syn. *Syngamus*) eggs ( $80$  to  $100 \mu\text{m} \times 40$  to  $65 \mu\text{m}$ ) with slightly thick-

er, striated shells, containing a few large blastomeres (Fig. 1), and previously reported from the respiratory tract of tropical felids (Cameron, 1931). The ascarids, *Toxocara cati* and *Toxascaris leonina*, probably were acquired by eating larvated eggs or mammals that contained the infective larvae (Soulsby, 1982).

*Capillaria* spp. eggs ( $50$  to  $75 \mu\text{m} \times 20$  to  $30 \mu\text{m}$ ) occurred in 51% of the samples (Fig. 1) and represented a variety of species (Yamaguti, 1963b). Lungworm larvae (*Aelurostrongylus* sp. and *Troglostrongylus* sp.) also were found (Fig. 1). Cats ingest infective larvae in intermediate (snails or slugs) or transport (rodents and reptiles) hosts (Soulsby, 1982).

The largest protozoan oocysts ( $32$  to  $50 \mu\text{m} \times 32$  to  $40 \mu\text{m}$ ) were possibly *Isospora felis*, common in domestic cats; *Hammon-*

*dia pardalis*, reported from large cats in Central America (Patton et al., 1986); or *I. leopardi*, reported from leopards in zoological collections (Agrawal et al., 1981). A smaller sporulated isosporan oocyst (15 to 25  $\mu\text{m}$   $\times$  15 to 20  $\mu\text{m}$ ) resembled the common felid parasite *I. rivolta*. Cats eat the sporozoites in mammalian paratenic host or in sporulated oocysts. Smaller oocysts (10  $\times$  12  $\mu\text{m}$ ) resembling *Toxoplasma gondii*, *Hammondia* spp., or *Besnoitia* spp. could not be differentiated. *Sarcocystis* spp. sporocysts were in 23% of the samples. Although *Sarcocystis* was not reported from these cats previously, its presence was not surprising because *Sarcocystis* spp. has a prey-predator life cycle (Dubey et al., 1989). *Giardia* sp. cysts were found in one leopard sample (Fig. 1). *Giardia* sp. has a cosmopolitan distribution and is acquired when animals ingest the cyst.

In summary, a variety of parasite eggs, larvae, cysts, and oocysts were in the feces of the cats from the study area. Helminth eggs were more common than protozoan cysts or oocysts; however, many of the samples collected on the trails were several hours old at the time of preservation. The paucity of protozoans may be an artifact of preservation. Many of the parasite species identified were acquired when the cats consumed prey. The remains of these prey species were a frequent component of the feces (Rabinowitz and Walker, 1991). Also some of the eggs probably were from the prey consumed and did not represent an infection. Information about parasites in a feline community where there has been little previous investigation contributes to an understanding of the health of the cats as well as the range, distribution, and zoonotic potential of parasite species.

We thank Sandra Strawbridge Johnson for technical assistance, and Charles T. Faulkner for photomicrography. The work was supported by a grant from Wildlife Conservation International.

#### LITERATURE CITED

- AGRAWAL, R. D., S. S. AHLUWALIA, B. B. BHATIA, AND P. P. S. CHAUHAN. 1981. Note on mammalian coccidia at Lucknow Zoo. *Indian Journal of Animal Science* 51: 125-128.
- BEAVER, P. C., R. C. JUNG, AND E. W. CUPP. 1984. *Clinical parasitology*. Lea and Febiger, Philadelphia, Pennsylvania, 825 pp.
- CAMERON, T. W. M. 1931. On some lungworms of the Malay tiger. *Journal of Helminthology* 9: 147-152.
- DUBEY, J. P., C. A. SPEER, AND R. FAYER. 1989. *Sarcocystosis of animals and man*. CRC Press Inc., Boca Raton, Florida, 213 pp.
- GEORGI, J. R., AND M. E. GEORGI. 1990. *Parasitology for veterinarians*, 5th ed. W. B. Saunders Company, Philadelphia, Pennsylvania, 412 pp.
- PATTON, S., A. RABINOWITZ, S. RANDOLPH, AND S. S. JOHNSON. 1986. A coprological survey of parasites of wild neotropical felidae. *The Journal of Parasitology* 72: 517-520.
- RABINOWITZ, A., AND S. R. WALKER. 1991. The carnivore community in a dry tropical forest mosaic in Huai Kha Khaeng Wildlife Sanctuary, Thailand. *Journal of Tropical Ecology* 7: 37-47.
- SCHMIDT, G. D. 1986. *Handbook of tapeworm identification*. CRC Press Inc., Boca Raton, Florida, 675 pp.
- , AND A. M. DUNN. 1974. *Neonicicola sinensis* sp. n. (Acanthocephala: Oligacanthorhynchidae) from China. *The Journal of Parasitology* 60: 626-627.
- SOULSBY, E. J. L. 1982. *Helminths, arthropods and protozoa of domesticated animals*. Lea and Febiger, Philadelphia, Pennsylvania, 808 pp.
- YAMAGUTI, S. 1963a. *Systema Helminthum*. Vol II. Cestodes. Interscience Publishers, John Wiley and Sons, New York, New York, 858 pp.
- . 1963b. *Systema Helminthum*. Vol III. Nematodes. Interscience Publishers, John Wiley and Sons, New York, New York, 679 pp.
- . 1963c. *Systema Helminthum*. Vol IV. Acanthocephala. Interscience Publishers, John Wiley and Sons, New York, New York, 423 pp.
- YASUDA, N. R., M. AKUZAWA, H. MARUYAMA, M. IZAWA, AND T. DOI. 1993. Helminths of the Tsushima leopard cat (*Felis bengalensis euphilura*). *Journal of Wildlife Diseases* 29: 153-155.
- YOUNG, K. H., S. L. BULLOCK, D. M. MELVIN, AND C. L. SPRUILL. 1979. Ethyl acetate as a substitute for diethyl ether in the formalin-ether sedimentation technique. *Journal of Clinical Microbiology* 10: 852-853.

*Received for publication 26 January 1993.*