



## **Prevalence of *Babesia cynicti* Infection in Three Populations of Yellow Mongooses (*Cynictis penicillata*) in the Transvaal, South Africa**

Authors: Penzhom, B. L., and Chaparro, F.

Source: Journal of Wildlife Diseases, 30(4) : 557-559

Published By: Wildlife Disease Association

URL: <https://doi.org/10.7589/0090-3558-30.4.557>

---

BioOne Complete ([complete.BioOne.org](https://complete.BioOne.org)) is a full-text database of 200 subscribed and open-access titles in the biological, ecological, and environmental sciences published by nonprofit societies, associations, museums, institutions, and presses.

Your use of this PDF, the BioOne Complete website, and all posted and associated content indicates your acceptance of BioOne's Terms of Use, available at [www.bioone.org/terms-of-use](https://www.bioone.org/terms-of-use).

Usage of BioOne Complete content is strictly limited to personal, educational, and non - commercial use. Commercial inquiries or rights and permissions requests should be directed to the individual publisher as copyright holder.

---

BioOne sees sustainable scholarly publishing as an inherently collaborative enterprise connecting authors, nonprofit publishers, academic institutions, research libraries, and research funders in the common goal of maximizing access to critical research.

## Prevalence of *Babesia cynicti* Infection in Three Populations of Yellow Mongooses (*Cynictis penicillata*) in the Transvaal, South Africa

B. L. Penzhorn<sup>1</sup> and F. Chaparro,<sup>2</sup> <sup>1</sup> Department of Veterinary Tropical Diseases, Faculty of Veterinary Science, University of Pretoria, Private Bag X04, Onderstepoort, 0110, Republic of South Africa; <sup>2</sup> Virology Section, Onderstepoort Veterinary Institute, Private Bag X05, Onderstepoort, 0110, Republic of South Africa

**ABSTRACT:** *Babesia cynicti* originally was described from spleen smears of two yellow mongooses (*Cynictis penicillata*), the main vectors of rabies on the central plateau of South Africa. During a detailed study of the epizootiology of rabies in that area between October 1991 and February 1993, sets of blood smears from three yellow mongoose populations were available for examination. *Babesia cynicti* was found in 50 of 56 specimens from Rooiwal, north of Pretoria, in 13 of 18 specimens from near Ermelo in the southeastern Transvaal, and in 22 of 23 specimens from Potchefstroom in the western Transvaal.

**Key words:** Yellow mongoose, *Cynictis penicillata*, *Babesia cynicti*, *Babesia* species, Viverridae.

Yellow mongooses (*Cynictis penicillata*) are regarded as the most important rabies vectors on the central plateau of South Africa (Gummow and Turner, 1986). This study was occasioned by a detailed investigation by one of us (FC) into the role of yellow mongooses in the epizootiology of rabies in this region. At the same time we determined prevalence of hemoprotozoa in these animals.

*Babesia cynicti* was described by Neitz (1938) from spleen smears of two yellow mongooses collected at Fauresmith in the Orange Free State, South Africa; type specimen 1397 is in the collection of the Protozoology Section, Onderstepoort Veterinary Institute (PS-OVI), Onderstepoort, South Africa. Neitz (1938) described round forms (1.8 to 2.2  $\mu\text{m}$ ), ovoid forms (2.0  $\times$  1.5  $\mu\text{m}$ ) and large round forms (3.0 to 6.0  $\mu\text{m}$ ). Subsequent specimens were obtained from Kroonstad, also in the Orange Free State (PS-OVI 1754 and 1755). Originally placed in the genus *Nuttalia* on the basis of the cruciform quadruple division observed, and also referred to the genus *Nicollia*, the species is now included in the

genus *Babesia* (Levine, 1988). Our objective was to determine the prevalence of *Babesia cynicti* in three populations of yellow mongooses in the Transvaal.

Yellow mongooses were collected in the Rooiwal area (25°32'S, 28°14'E) north of Pretoria, on the farm Leliefontein (26°30'S, 30°05'E) east of Ermelo in the southeastern Transvaal, and at the South African Defence Force Equestrian Centre (26°35'S, 27°00'E), 15 km northwest of Potchefstroom in the western Transvaal between October 1991 and February 1993. Baited, wire box traps were placed near burrows inhabited by yellow mongooses and checked twice daily (mid-morning and late afternoon), as these mongooses are primarily diurnal (Earlé, 1981). Trapped mongooses were restrained by pulling them to the side of the trap by means of a dog capture loop and injecting 10 to 15 mg ketamine (Ketalar, Parke-Davis, Tokai, South Africa) and 0.6 to 1 mg xylazine (Rompun, Bayer Animal Health, Isando, South Africa) intramuscularly. Once the mongoose was anesthetized, a thin blood smear was made from a small puncture wound in the pinna. Blood smears were fixed in methanol, stained with Giemsa's stain and examined under oil. Measurements ( $n = 25$ ) were made with an ocular micrometer. The composite diagram was drawn with the aid of a drawing tube attached to the microscope. Representative smears were deposited in the Protozoology Section, Onderstepoort Veterinary Institute, Onderstepoort, South Africa (PS-OVI 6158 and 6159).

Small round (1.25 to 2.0  $\mu\text{m}$ ) and ovoid (1.5 to 2.25  $\times$  1.0 to 1.5  $\mu\text{m}$ ) parasites resembling *Babesia cynicti* were found in 50 of 56 Rooiwal specimens, in 13 of 18

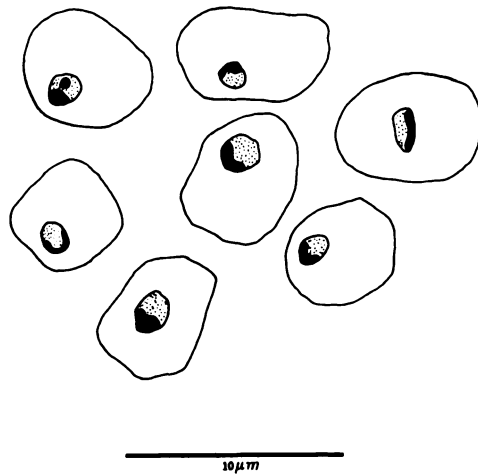


FIGURE 1. Drawings of intra-erythrocytic forms of *Babesia cynicti* seen in thin blood smears of yellow mongooses (*Cynictis penicillata*) from the Transvaal, South Africa (Bar = 10  $\mu$ m).

Ermelo specimens and in 22 of 23 Potchefstroom specimens. With the exception of the hosts for the two deposited specimens, from Rooiwal (PS-OVI 6158) and Potchefstroom (PS-OVI 6159), the parasitemias were <0.1%, as would be expected in a carrier state. Virtually all parasites seen were small circular bodies with crescent-shaped, peripheral nuclei (Fig. 1). Large ring forms described by Neitz (1938) were not seen in our specimens. In the Rooiwal specimen (PS-OVI 6158) occasional forms exhibiting a round nucleus, as described by Neitz (1938), were seen. Deleterious effects of the parasites on the mongooses are unknown, but Neitz (1938) found signs of anemia, with anisocytosis, polychromasia and erythrophagocytosis of the parasitized cells, on one of the smears which he examined.

Although the vectors of *B. cynicti* are unknown, we believe that they are ixodid ticks. *Haemaphysalis zumpti* is a possible vector. All instars have been collected from yellow mongooses, and the tick seems to be specially adapted to life in burrow systems inhabited by yellow mongooses and other small carnivores (Hoogstraal and El Kammah, 1974). *Haemaphysalis zumpti* is closely related to *H. leachi*, a known

*Babesia* vector in dogs (Lounsbury, 1901). *Rhipicephalus theileri* also has been collected from yellow mongooses (Lynch, 1980). The tendency of yellow mongooses to live in small clans (Earlé, 1981) and their habit of frequenting burrows could facilitate the transmission of *B. cynicti* by ticks. The high prevalence of infection therefore was not surprising.

Although other *Babesia* species have been described from various African members of the family Viverridae, this is the first known report of infection prevalence in this family. *Babesia vanhoofi* was described from *Helogale varia* (de Smet and Lips, 1955) and *Babesia heischi* and *Babesia hoarei* from *Helogale undulata rufula* (Grewal, 1957); both host names now are regarded as synonyms of *Helogale parvula*, the dwarf mongoose (Wilson and Reeder, 1993). *Babesia hoarei* may be synonymous with *B. vanhoofi*, as their descriptions are very similar. *Babesia roubaudi* was described from the striped polecat (*Ictonyx striatus*) (Leger and Bédier, 1923), and *Babesia legeri* from "*Herpestes calera*" by Bédier (1924). We were unable to trace the latter host species and regard it as a typographical error for *Herpestes galera*, as the water mongoose (*Atilax paludinosus*) commonly was named previously (Allen, 1924). Blood and spleen smears of an adult female water mongoose collected near Pretoria, South Africa (PS-OVI 1459 and 1460) contain a small *Babesia* sp., probably *B. legeri* (B. L. Penzhorn, unpubl.). *Babesia herpestidis* was described from the large grey mongoose (*Herpestes ichneumon*) (França, 1908, quoted in Levine, 1988; original paper not seen), and *Babesia civettae* from the African civet (*Civettictis civetta*) by Leger and Leger (1920). Heisch (1952) described *Babesia garnhami* and *Babesia genettae* from the small-spotted genet (*Genetta genetta*). Small *Babesia*-like organisms were found in thin blood smears of a slender mongoose (*Galerella sanguinea*) (PS-OVI 6156) from Pretoria North and large and small *Babesia*-like organisms in a thin blood

smear of a banded mongoose (*Mungos mungo*) (PS-OVI 6155) from the Kruger National Park, South Africa (B. L. Penzhorn, unpubl.).

This paper is part of the Wildlife Research Programme of the Faculty of Veterinary Science, University of Pretoria. The diagram was drawn by Ms. Jenny Smith. We thank Ms. Lynne Booth for fixing and staining the blood smears, and Drs. D. T. de Waal and L. M. López Rebollar for access to the collection of the Protozoology Section, Onderstepoort Veterinary Institute.

#### LITERATURE CITED

- ALLEN, J. A. 1924. Carnivora collected by the American Museum Congo Expedition. Bulletin of the American Museum of Natural History 47: 73–281.
- BÉDIER, E. 1924. Piroplasma de la mangouste d'Afrique *Herpestes calera* Erxleben. Comptes Rendus Hebdomadaires des Séances et Mémoires de la Société de Biologie 90: 415–417.
- DE SMET, R. M., AND M. LIPS. 1955. Un nouveau babesia du Katanga, Congo Belge. Annales de la Société Belge de Médecine Tropicale 35: 5–9.
- EARLÉ, R. A. 1981. Aspects of the social and feeding behaviour of the yellow mongoose *Cynictis penicillata* (G. Cuvier). Mammalia 45: 143–152.
- GREWAL, M. S. 1957. Two new piroplasms, *Babesia (Babesiella) heischii* and *Babesia (Babesia) hoareii* from Peter's pigmy mongoose, *Helogale undulata rufula* (demonstrated by Professor Garnham). Transactions of the Royal Society of Tropical Medicine and Hygiene 51: 290–291.
- GUMMOW, B., AND G. V. TURNER. 1986. Rabies in South Africa: Epidemiological trends for the period 1980–1984. Journal of the South African Veterinary Association 57: 231–237.
- HEISCH, R. B. 1952. New piroplasms of a genet cat and a ground-squirrel from Kenya. Annals of Tropical Medicine and Parasitology 46: 150–154.
- HOOGSTRAAL, H., AND EL KAMMAH, M. 1974. Notes on African *Haemaphysalis* ticks. XII. *H. (Rhipistoma) zumpti* sp. n., a parasite of small carnivores and squirrels in southern Africa (Ixodoidea: Ixodidae). The Journal of Parasitology 60: 188–197.
- LEGER, A., AND M. LEGER. 1920. Piroplasma de la civette au Sénégal. Bulletins de la Société de Pathologie Exotique 13: 649–652.
- LEGER, M., AND E. BÉDIER. 1923. *Plasmodium* d'un mustélidé, *Ictonyx zorrilla*, du Sénégal. Comptes Rendus Hebdomadaires des Séances et Mémoires de la Société de Biologie 88: 422–424.
- LEVINE, N. D. 1988. The protozoan phylum Apicomplexa, Vol. II. CRC Press, Boca Raton, Florida, 154 pp.
- LOUNSBURY, C. P. 1901. Transmission of malignant jaundice of the dog by a species of tick. Agricultural Journal of the Cape of Good Hope 19: 714–724.
- LYNCH, C. D. 1980. Ecology of the suricate, *Suricata suricatta* and yellow mongoose, *Cynictis penicillata* with special reference to their reproduction. Memoirs van die Nasionale Museum, Bloemfontein 14: 1–145.
- NEITZ, W. O. 1938. The occurrence of *Nuttalia cynicti* sp. nov. in the yellow mongoose (*sic.*) *Cynictus (sic.) penicillata* in South Africa. Onderstepoort Journal of Veterinary Science and Animal Industry 10: 37–40.
- WILSON, D. E., AND REEDER, D. M. 1993. Mammal species of the world: A taxonomic and geographic reference, 2nd ed. Smithsonian Institution, Washington, D.C., 1206 pp.

Received for publication 7 January 1994.