



Hypertrophic Pulmonary Osteoarthropathy in a Raccoon Dog (*Nyctereutes procyonoides*) with Chronic Pulmonary Inflammatory Lesions

Authors: Masegi, Toshiaki, Yanai, Tokuma, Sakai, Tomoaki, Matsumoto, Chigusa, Yamazoe, Kazuaki, et. al.

Source: Journal of Wildlife Diseases, 30(4) : 612-615

Published By: Wildlife Disease Association

URL: <https://doi.org/10.7589/0090-3558-30.4.612>

BioOne Complete (complete.BioOne.org) is a full-text database of 200 subscribed and open-access titles in the biological, ecological, and environmental sciences published by nonprofit societies, associations, museums, institutions, and presses.

Your use of this PDF, the BioOne Complete website, and all posted and associated content indicates your acceptance of BioOne's Terms of Use, available at www.bioone.org/terms-of-use.

Usage of BioOne Complete content is strictly limited to personal, educational, and non - commercial use. Commercial inquiries or rights and permissions requests should be directed to the individual publisher as copyright holder.

BioOne sees sustainable scholarly publishing as an inherently collaborative enterprise connecting authors, nonprofit publishers, academic institutions, research libraries, and research funders in the common goal of maximizing access to critical research.

Hypertrophic Pulmonary Osteoarthropathy in a Raccoon Dog (*Nyctereutes procyonoides*) with Chronic Pulmonary Inflammatory Lesions

Toshiaki Masegi,^{1,4} Tokuma Yanai,¹ Tomoaki Sakai,¹ Chigusa Matsumoto,¹ Kazuaki Yamazoe,² Aya Nukaya,³ Yoshio Kunimune,³ and Katsumoto Ueda,¹ ¹ Department of Veterinary Pathology, Gifu University, Yanagido 1-1, Gifu 501-11, Japan; ² Veterinary Surgery, Gifu University, Yanagido 1-1, Gifu 501-11, Japan; ³ O uji Animal Hospital, O uji 4-44-7, Kita-kasturagi, Nara 636, Japan; ⁴ Author for reprint requests

ABSTRACT: A female raccoon dog (*Nyctereutes procyonoides*) captured September 1992 in Nara prefecture, Japan, suffering from swollen joints of all four limbs was necropsied. Radiographically, there was a shadow in the right pulmonary caudal lobe and periosteal bone formation around several joints. Microscopically, there was extensive edema, along with one large and many small pyogranulomatous nodules and purulent bronchitis in the right lobe and left caudal lobe of the lungs. There were intermingled branching filamentous bacteria in the lesion, which stained positively with Warthin-Starry, Grocott, and Gram stains, and partially with periodic acid Schiff and Ziehl-Neelsen stains. Extensive exostosis with coralloid trabeculation had developed bilaterally at the carpal, stifle and hock joints in the surrounding well vascularized loose connective tissue. Degeneration of articular cartilage and villous proliferation of synovial membranes were apparent. This is the first report of hypertrophic pulmonary osteoarthropathy in the raccoon dog.

Key words: Hypertrophic pulmonary osteoarthropathy, raccoon dog, *Nyctereutes procyonoides*.

Hypertrophic pulmonary osteoarthropathy (HPOA) is an uncommon reactive condition characterized by exostosis at extremity joints, and usually is preceded by chronic pulmonary inflammatory or neoplastic lesions. This condition has been reported in many animal species, including humans (Shneerson, 1981). Among humans, inflammation and connective tissue proliferation in the synovial membranes occur, but similar articular lesions apparently have not been seen in other species (Palmer, 1993). We describe HPOA in a wild-caught raccoon dog (*Nyctereutes procyonoides*), a native carnivore belonging to the Family Canidae.

A female adult raccoon dog of unknown

age was captured because of difficulty in movement in Nara prefecture, Japan (35°33'N, 135°42'E) on 7 September 1992, and hospitalized in a veterinary clinic. The carpal, stifle and hock joints on both sides were swollen, hard, and stiffened. A decubitus ulcer was noticed at the outer side of the right hock joint. Based on palpation, there was heat and pain. Radiographically there were bilateral coralloid osseous projections at the epiphyseal and metaphyseal areas of the proximal end of the metacarpus, the distal end of the femur, and the proximal end of the tibia and metatarsus (Fig. 1). Based on a chest roentgenogram, we observed one large mass and many tiny shadows in the right caudal lobe of the lung. Rough respiratory sounds were auscultated. The animal was depressed and anemic; it had a low (33 mg/dl) blood glucose concentration (Drychem 5500; Fuji Medical Co., Ginza, Tokyo) and anemia (376×10^4 RBC/ml) (Cell tac: Nihon-koden Co., Shinjuku, Tokyo). Since no improvement was observed after 1 wk of treatment, the animal was euthanized by exsanguination under anesthesia with 10 mg/kg ketamine hydrochloride (Veterinary Ketalar 50: Sankyo Co., Ginza, Tokyo) given by intra-muscular injection; it then was necropsied at the University Laboratory.

Major gross changes included edema of the right caudal lung lobe with a nodule 2 cm in diameter, and scattered small nodules about 3 mm in diameter distributed in the right lobes and left caudal lobe, as well as bilateral osseous enlargement about 4 cm in diameter of the metacarpal, metatarsal, and femorotibial joints (Fig. 1). The

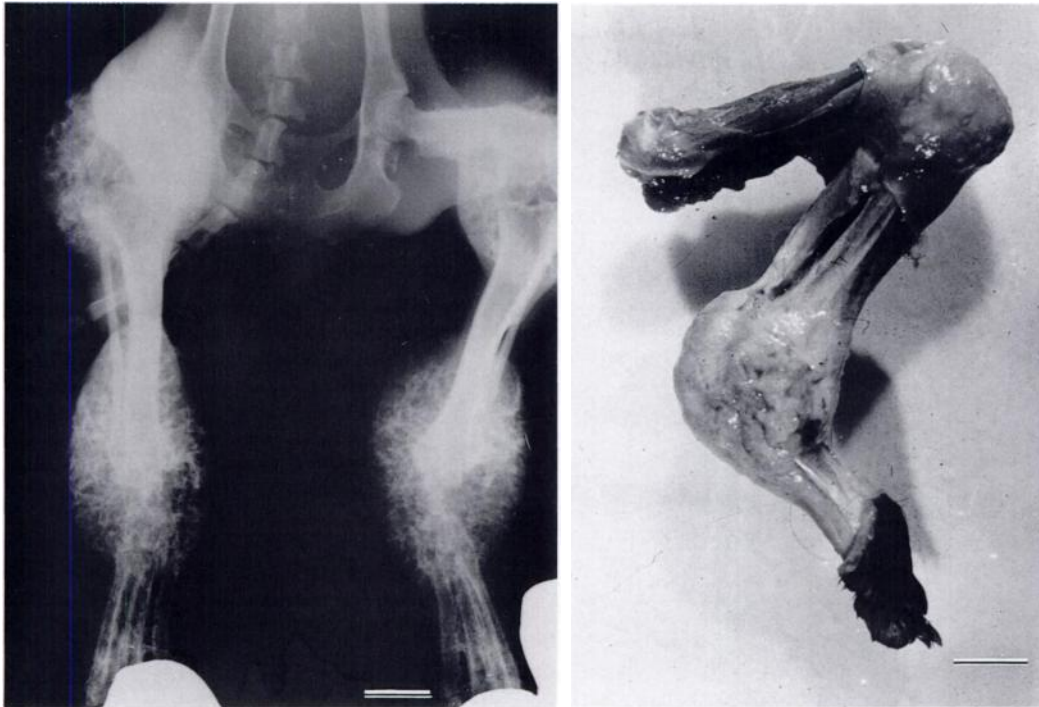


FIGURE 1. Left. A roentgenogram of hind legs taken prior to necropsy. Right. Skinned left hind leg. Exostotic coralloid trabecular formation at the swollen hock joint is visible. Bar = 20 mm in both figures.

lung, affected joints and other main organs were fixed with 10% neutral buffered formalin. Bone samples were decalcified after fixation. Tissues were embedded in paraffin, sections at 5 μm , and stained with hematoxylin and eosin (H&E). Selected sections from the lung were stained with Warthin-Starry, Grocott, Gram, Ziehl-Neelsen and periodic acid Schiff (PAS) stains (Luna, 1968).

Histologically, the pulmonary large nodule was a large pyogranulomatous lesion (Fig. 2) involving the bronchus. In the necrotic center of the suppurative area, we observed intermingled branching filamentous bacteria that appeared similar to *Nocardia* sp. based on their morphology. The bacteria stained positively with Warthin-Starry, Grocott, and Gram stains, and partially with PAS and Ziehl-Neelsen stains. Surrounding the pyogranuloma was a severe pulmonary edema. The entire lungs had a chronic suppurative bronchitis with peribronchial lymphocyte cuffing, scat-

tered small granulomas with central neutrophil infiltration, and moderate interstitial pneumonia. The exostotic lesion, limited to the epiphysis and metaphysis of the affected bones, was composed of trabecular bone formed among thickened periosteal loose connective tissue rich in blood vessels (Fig. 3). At the metaphysis, pre-existing bone was preserved but

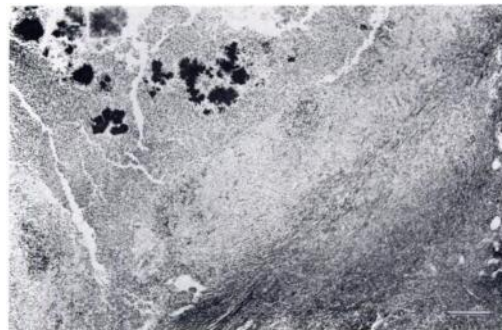


FIGURE 2. A pyogranulomatous nodule in the right caudal lobe of the lung. H&E stain. Bar = 300 μm .

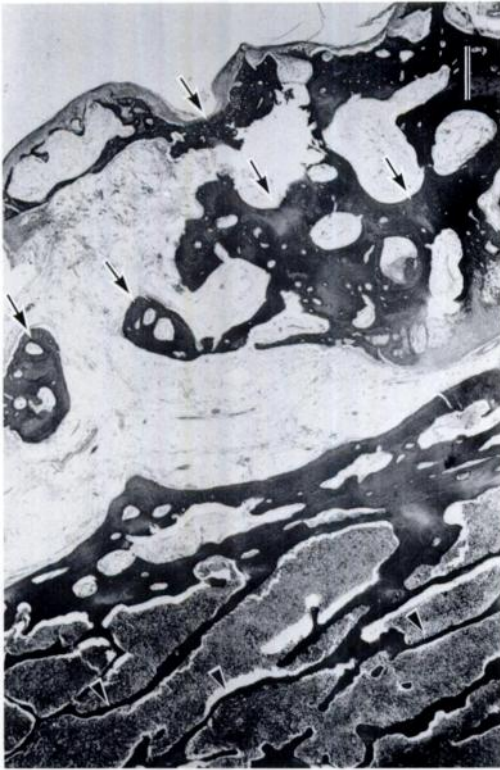

FIGURE 3. The exostotic lesion (arrows) composed of trabecular bone in the periosteal loose connective tissue. Pre-existing bone (arrow heads) is thin. H&E stain. Bar = 500 μm .

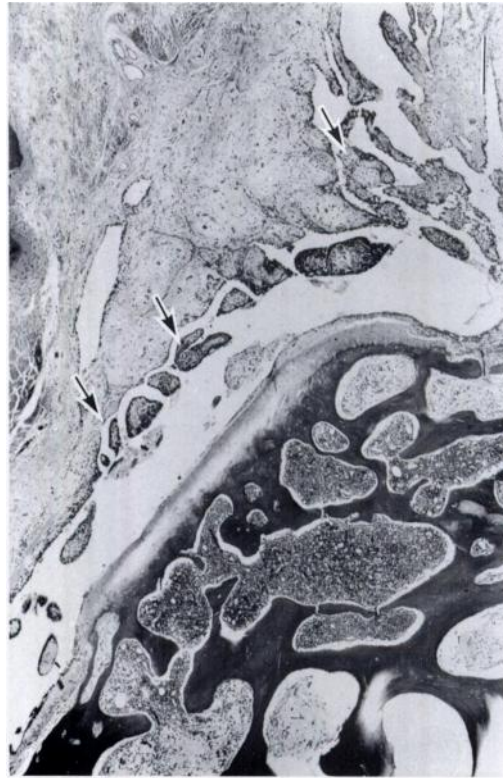


FIGURE 4. Villous proliferation of synovial membrane (arrows) at the metatarsal joint. H&E stain. Bar = 260 μm .

thinned, and in some places had been resorbed. Bone marrow, which was filled with myelopoietic elements, was often interconnected with periosteal loose connective tissue resulting in infiltration of myelocytic cells and neutrophils into the periosteal tissue. Adjacent muscles and tendons were involved. The synovial space was filled with loose periosteal connective tissue accompanying numerous blood vessels. The tibial articular cartilage was eroded, and the synovial membrane at the metacarpal joints had villous proliferation (Fig. 4). No marked changes were found in other organs.

Various species of mammals develop HPOA, although most reports on the syndrome are from humans (Shneerson, 1981) and domestic dogs (Brodey, 1971). This is the first known report in a raccoon dog,

an inhabitant of east Asia. Pulmonary lesions including chronic bronchitis with pyogranulomatous lesions associated with *Nocardia*-like bacteria seemed to be the cause of HPOA in the raccoon dog. Doige (1988) postulated that pulmonary lesions lead to reflex vasomotor changes and increase the blood flow to the extremities; increased arterial pressures, hyperemia, and edema of the periosteum lead to thickening of the periosteum, both by fibrous tissue and later by new bone formation (Doige, 1988). Since osteophyte formation was limited to epi- and metaphyseal regions of the four limbs, the case seemed to be a newly developing lesion. New bone formation and thickening of the limbs may occur very rapidly but may regress if the primary lesion is removed (Brodey, 1971). Of interest in this case is the involvement

of articulations, which has not been reported in the dog or other animal species (Palmer, 1993). Whether the invasive nature of the affected periosteum to synovial cavities is peculiar to this species, or some other disease present in this particular patient was responsible for the joint lesions, is uncertain at present.

LITERATURE CITED

- BRODEY, R. S. 1971. Hypertrophic osteoarthropathy in the dog: A clinicopathologic survey of 60 cases. *Journal of American Veterinary Medical Association* 159: 1242-1256.
- DOIGE, C. 1988. Skeletal system. *In* Special veterinary pathology, R. G. Thomson (ed.). B.C. Decker Incorporation, Burlington, Ontario, Canada, pp. 467-507.
- LUNA, L. G. 1968. Manual of histologic staining methods of the Armed Force Institute of Pathology, 3rd ed. McGraw-Hill Book Company, New York, New York, pp. 217-240.
- PALMER, N. 1993. Hypertrophic osteopathy. *In* Pathology of domestic animals, 4th ed., Vol. 1, J. V. F. Jubb, P. C. Kennedy, and N. Palmer (eds.). Academic Press, New York, New York, pp. 116-118.
- SHNEERSON, J. M. 1981. Digital clubbing and hypertrophic osteoarthropathy: The underlying mechanisms. *The British Journal of Diseases of the Chest* 75: 113-131.

Received for publication 20 December 1993.