



Fulminant *Streptococcus pneumoniae* Meningitis in a Lion-tailed Macaque (*Macaca silenus*) without Detected Signs

Authors: Graczyk, Thaddeus K., Cranfield, Michael R., Kempke, Sandra E., and Eckhaus, Michael A.

Source: Journal of Wildlife Diseases, 31(1) : 75-78

Published By: Wildlife Disease Association

URL: <https://doi.org/10.7589/0090-3558-31.1.75>

BioOne Complete (complete.BioOne.org) is a full-text database of 200 subscribed and open-access titles in the biological, ecological, and environmental sciences published by nonprofit societies, associations, museums, institutions, and presses.

Your use of this PDF, the BioOne Complete website, and all posted and associated content indicates your acceptance of BioOne's Terms of Use, available at www.bioone.org/terms-of-use.

Usage of BioOne Complete content is strictly limited to personal, educational, and non - commercial use. Commercial inquiries or rights and permissions requests should be directed to the individual publisher as copyright holder.

BioOne sees sustainable scholarly publishing as an inherently collaborative enterprise connecting authors, nonprofit publishers, academic institutions, research libraries, and research funders in the common goal of maximizing access to critical research.

Fulminant *Streptococcus pneumoniae* Meningitis in a Lion-tailed Macaque (*Macaca silenus*) without Detected Signs

Thaddeus K. Graczyk,¹ Michael R. Cranfield,² Sandra E. Kempske,² and Michael A. Eckhaus,³ ¹ The Johns Hopkins University, School of Hygiene and Public Health, Department of Molecular Microbiology and Immunology, 615 North Wolfe Street, Baltimore, Maryland 21205, USA; ² The Baltimore Zoo, Druid Hill Park, Baltimore, Maryland 21217, USA; ³ The Johns Hopkins University, School of Medicine, Department of Pathology, 720 Rutland Avenue, Baltimore, Maryland 21205, USA

ABSTRACT: A 3-month-old lion-tailed macaque (*Macaca silenus*) infant that died on 2 February 1985 in the Baltimore Zoo (Baltimore, Maryland, USA) due to fulminating *Streptococcus pneumoniae* meningitis had congested, edematous lungs, and thickened and congested brain leptomeninges with a grayish-yellow fluid within the subarachnoid brain space. From bacterial cultures made postmortem of the subarachnoid brain space fluid, cerebrospinal fluid, throat secretions, nasal secretions, and lung fluid, we isolated pure cultures of group B streptococci, alpha hemolytic *S. pneumoniae*, type 19F (capsular). We also isolated *Staphylococcus aureus* and *S. hemolytica* from antemortem nasal and throat bacterial cultures from all 13 animals of the *M. silenus* colony. *Streptococcus pneumoniae* meningitis in *M. silenus* has not been previously reported.

Key words: Lion-tailed macaque, *Macaca silenus*, *Streptococcus pneumoniae*, pneumococcal meningitis, nonhuman primate infant.

The lion-tailed macaque (*Macaca silenus*) is one of the most severely endangered species (Ali, 1985). *Streptococcus pneumoniae* is a pathogenic bacterium with 83 antigenically distinct types and serotypes of various pathogenicity (Erickson, 1980) that are spread by the aerosol route. Good and May (1971) reported pneumonia, peritonitis, and low-morbidity meningitis (with clinical signs) due to *S. pneumoniae* in *Macaca mulatta*, *M. fascicularis*, *M. nemestrina*, *M. radiata*, and *M. speciosa*. However, the pathogen had not been reported from *M. silenus*.

Lion-tailed macaques (*M. silenus*) have been housed in the Baltimore Zoo, Baltimore, Maryland (USA) since 1977. The animals were kept in two cohorts of four animals, and in one cohort of five animals. The three cohorts of lion-tailed macaques

were housed in three separate, tiled exhibits with a barred front and glass that protected them from public exposure. The diet of all animals consisted of Purina Monkey Chow-25 (Ralston Purina Co., St. Louis, Missouri, USA) and small quantities of fruits, vegetables, sunflower seeds, and a vitamin supplement (Pervinal, Nutritional Supplements, Brentwood, New Jersey, USA). The animals had access to the drinking water. The exhibits were cleaned daily with 0.02% aqueous solution of sodium hypochlorite (The Clorox Company, Oakland, California, USA), and Antimicrobial Soap (Curtin Matheson Scientific Inc., Houston, Texas, USA). Vermin control included monthly treatments of the exhibit areas with Gencor 9% Insect Spray (Residix, Dallas, Texas). The behavior of the animals was monitored daily by zoo keepers, and all animals were examined weekly by a veterinarian.

On 30 October 1984, an 11-yr-old female from the cohort of five monkeys gave birth to her seventh, clinically healthy, infant. The gestation and parturition periods were normal, as were the antepartum and postpartum behaviors of the female. The neonate appeared clinically normal, and had no history of medical problems. On 2 February 1985, the infant was found dead in the morning. No clinical signs were exhibited on the preceding day. The infant was necropsied. Histological smears of cerebrospinal fluid and lung fluid were prepared according to the protocol of Bevelander and Ramaley (1974), and stained with hematoxylin and eosin. Sections of brain and lungs were fixed in 10% neutral buffered formalin, embedded in paraffin,

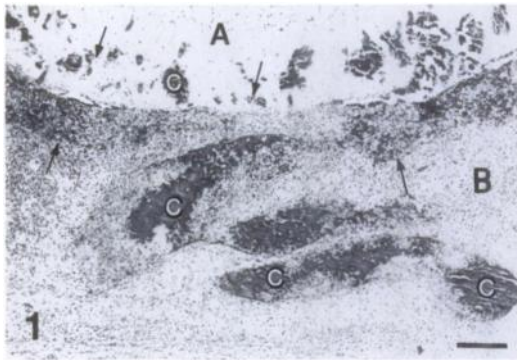


FIGURE 1. Cerebral cortex of superficial grey matter (A) and subarachnoid space, meningitis (B) of the lion-tailed macaque (*Macaca silenus*) infant that died due to fulminating *Streptococcus pneumoniae* meningitis. C, dilated blood vessels with associated microhemorrhages and expanded infiltration of mononuclear inflammatory cells (arrows). H + E. Bar = 10 μ m.

cut into 5 μ m sections and stained with hematoxylin and eosin. Bacterial cultures were attempted from cerebrospinal fluid, subarachnoid brain stem space fluid, throat secretions, nasal secretions, and lung fluid. Preparation of bacterial cultures followed the procedures of Facklam and Washington (1992). Gram-stains and identification of *S. pneumoniae* by the bile solubility test and the Optochin sensitivity test followed the protocol of Facklam and Washington (1992). The coagulination test was performed according to the protocol of Duguid and Ross (1989) to determine serological type of the pathogen. After the fatal case was identified, nasal and pharyngeal swabs were taken according to the protocol of Snader and Soare (1970) from all 13 remaining *M. silenus*.

At necropsy, there was a generalized atrophy of skeletal muscle and mild dehydration. The lungs were moderately congested, diffusely edematous, and exuded a serosanguineous fluid upon sectioning. Focal hemorrhages of the lungs also were noted. The leptomeninges covering the brain were diffusely thickened and severely congested. A grayish-yellow fluid was seen within the subarachnoid space

overlying the ventral aspect of the brain stem.

Based on microscopic examination, there was a dense cellular infiltrate, moderate amounts of fibrin, and numerous distended arterioles and venules associated with microhemorrhages in the subarachnoid space (Fig. 1). The infiltrate was composed of large numbers of degenerative neutrophils and macrophages, with fewer lymphocytes. Necrosis and thrombosis of venules with adjacent foci of hemorrhage were prominent in the subarachnoid space. Numerous extracellular, Gram-positive cocci, predominantly arranged in pairs, were seen scattered throughout the leptomeningeal infiltrate. The underlying superficial cerebral cortical gray matter contained multifocal hemorrhages. The inflammatory infiltrate extended into the space around blood vessels in the brain. Bacterial cultures of the subarachnoid brain stem space fluid, cerebrospinal fluid, throat secretion, nasal secretions, and the lung fluid yielded pure cultures of group B streptococci, alpha hemolytic *S. pneumoniae*, type 19F (capsular). All pathogen isolates were of the same type.

Based on the nasal and pharyngeal bacterial cultures of 13 *M. silenus* we found *Staphylococcus aureus* and *Streptococcus hemolytica* in all animals; but no *S. pneumoniae* was detected.

Good and May (1971) found that 225 (3.0%) of 7,424 nares and nasopharyngeal secretions of five species of macaques (*Macaca mulatta*, *M. fascicularis*, *M. nemestrina*, *M. radiata*, and *M. speciosa*) contained *S. pneumoniae*. In non-human primates, stress-related factors such as transportation, viral infections (Brendt et al., 1974; Jones et al., 1984), and decreased immunocompetence 2 to 6 mo postpartum due to waning of passive immunity are proposed to be the main factors that increase susceptibility to *S. pneumoniae* infection (Fox and Wikse, 1971). We concluded that the decreased immunocompetence due to the waning of passive

immunity could be a factor that predisposed the infant to sepsis.

The oral route of spread for *S. pneumoniae* is most common. However, evidence for the cellular invasion of group B streptococci (GBS) was provided by Rubens et al. (1991) who showed that intramniotic injection of pregnant *M. nemestrina* with GBS produced an early onset of fatal GBS infection in infants. However, in the present case, the six previous siblings were uninfected, and the mother was *S. pneumoniae*-negative after the death of her infant. Considering these facts, we believe that the bacterial infection was acquired spontaneously, and not via cellular invasion.

The striking observation in this case was that the *S. pneumoniae* meningitis did not produce clinical signs, such as sensorineural deafness that could indicate meningitis; however, fatal pneumococcal meningitis without symptoms was reported in a human (Callahan, 1989). The reason for absence of meningeal signs in meningitis is unknown (Callahan, 1989).

The gross pathology observed in the present study was similar to that observed in experimentally-induced meningitis in animal infants (Tureen et al., 1990; Rodriguez et al., 1991), and the observed pathology was evidence for loss of cerebrovascular autoregulation. As shown by Goitein and Shapiro (1992) in a rabbit model, an irreversible increment of intracranial pressure, hemodynamic collapse, cerebral ischemia, and death were observed 25 hr post-inoculation of *S. pneumoniae* into the cisterna magna. Thus, if the meningitis is identified based on clinical signs, medical treatment can be initiated immediately. Chest auscultation that may be of value in detection of clinical signs usually is not performed in *M. silenus* due to the tenuous bond between dam and infant.

For purposes of prevention we believe that lion-tailed macaques should be housed in enclosures with adequate space, venti-

lation, and strict hygiene. Nasal and pharyngeal cultures should be obtained on all newly acquired animals. Personnel working with lion-tailed macaques should wear masks in order to eliminate spread of the pathogen.

We thank S. Hill and W. L. Nicholson for consultation. We received financial support from the AKC Fund of New York for this study.

LITERATURE CITED

- ALI, R. 1985. An overview of the status and distribution of the lion-tailed macaque. In *The lion-tailed macaque: Status and conservation*, P. G. Heltne (ed.). Alan R. Liss, Inc., New York, New York, pp. 13–25.
- BEVELANDER, G., AND J. A. RAMALEY (editors). 1974. *Essentials of histology*. C. V. Mosby Company, St. Louis, Missouri, 348 pp.
- BRENDT, R. F., W. E. McDONOUGH, AND J. S. WALKER. 1974. Persistence of *Diplococcus pneumoniae* after influenza virus infection in *Macaca mulatta*. *Infection and Immunity* 10: 369–374.
- CALLAHAN, M. 1989. Fulminating bacterial meningitis without meningeal signs. *Annals of Emergency Medicine* 18: 90–93.
- DUGUID, J. P., AND P. W. ROSS. 1989. *Streptococcus pneumoniae (pneumococcus)*. In *Practical medical microbiology*, J. G. Collee, J. P. Duguid, A. G. Fraser, and B. P. Marmion (eds.). Churchill Livingstone, New York, New York, pp. 327–334.
- ERICKSON, E. D. 1980. Streptococcosis. In *Handbook series in zoonoses; bacterial, rickettsial and mycotic diseases*, J. H. Stelle (ed.). CRC Press, Inc., Boca Raton, Florida, pp. 65–80.
- FACKLAM, R. R., AND J. A. WASHINGTON. 1992. *Streptococcus* and related catalase-negative gram-positive cocci. In *Manual of clinical microbiology*, A. Balow (ed.). American Society for Microbiology, Washington D.C., pp. 238–257.
- FOX, J. G., AND S. E. WIKSE. 1971. Bacterial meningoencephalitis in rhesus monkeys: Clinical and pathological features. *Laboratory Animal Science* 21: 558–563.
- GOITEIN, K. J., AND M. SHAPIRO. 1992. Intracranial pressure and cerebral perfusion pressure in experimental *Streptococcus pneumoniae* meningitis. *Journal of Experimental Medicine* 192: 41–47.
- GOOD, R. C., AND B. D. MAY. 1971. Respiratory pathogens in monkeys. *Infection and Immunity* 3: 87–93.
- JONES, E. E., P. L. ALFORD, AND A. L. REINGOLD. 1984. Predisposition to invasive pneumococcal illness following parainfluenza type III virus in-

- fection in chimpanzees. *Journal of the American Veterinary Medical Association* 185: 1351-1353.
- RODRIGUEZ, A. F., S. L. KAPLAN, E. P. HAWKINS, AND E. O. MASON. 1991. Hematogenous pneumococcal meningitis in the infant rat: Description of a model. *The Journal of Infectious Diseases* 164: 1207-1209.
- RUBENS, C. E., H. V. RAFF, J. C. JACKSON, E. Y. CHI, J. T. BIELITZKI, AND S. L. HILLER. 1991. Pathophysiology and histopathology of group B streptococcal sepsis in *Macaca nemestrina* primates induced after intraamniotic inoculation: Evidence for bacterial cellular invasion. *The Journal of Infectious Diseases* 164: 320-330.
- SNADER, S. B., AND O. A. SOARE. 1970. A method for collection of throat specimens from laboratory primates for the rapid identification of respiratory infections. *Laboratory Animal Science* 20: 518-520.
- TUREEN, J. H., R. J. DWORKIN, S. L. KENNEDY, M. SACHADEVA, AND M. A. SANDE. 1990. Loss of cerebrovascular autoregulation in experimental meningitis in rabbits. *Journal of Clinical Investigation* 85: 577-581.

Received for publication 4 April 1994.