



## **Exclusion of Copper from Altered Hepatocytes in White Perch (*Morone americana*) with Hepatic Copper Storage**

Author: Bunton, Tracie E.

Source: Journal of Wildlife Diseases, 31(1) : 99-103

Published By: Wildlife Disease Association

URL: <https://doi.org/10.7589/0090-3558-31.1.99>

---

BioOne Complete ([complete.BioOne.org](https://complete.BioOne.org)) is a full-text database of 200 subscribed and open-access titles in the biological, ecological, and environmental sciences published by nonprofit societies, associations, museums, institutions, and presses.

Your use of this PDF, the BioOne Complete website, and all posted and associated content indicates your acceptance of BioOne's Terms of Use, available at [www.bioone.org/terms-of-use](https://www.bioone.org/terms-of-use).

Usage of BioOne Complete content is strictly limited to personal, educational, and non-commercial use. Commercial inquiries or rights and permissions requests should be directed to the individual publisher as copyright holder.

---

BioOne sees sustainable scholarly publishing as an inherently collaborative enterprise connecting authors, nonprofit publishers, academic institutions, research libraries, and research funders in the common goal of maximizing access to critical research.

## Exclusion of Copper from Altered Hepatocytes in White Perch (*Morone americana*) with Hepatic Copper Storage

Tracie E. Bunton, Division of Comparative Medicine, Johns Hopkins University School of Medicine, Baltimore, Maryland 21205, USA

**ABSTRACT:** Iron is excluded from foci of hepatocellular alteration in carcinogenesis of rodents and some fish. Among white perch (*Morone americana*), there is a condition of hepatic copper storage in which copper-loaded livers are produced naturally. In a group of fish collected from the Chesapeake Bay, Maryland (USA), from September to December 1990, we observed hepatic lesions which excluded copper similar to the phenomenon of iron exclusion, in a white perch with over 3,600  $\mu\text{g/g}$  wet weight hepatic copper. The lesions were of two types: one with cells morphologically different from normal hepatocytes and which had diminished to absolute exclusion of copper with the copper specific histochemical stain rubeinic acid, and a second with cells morphologically similar to normal hepatocytes which had only a partial exclusion of copper. Although the exact cause and nature of the lesions was not determined, intrinsic copper toxicity, environmental pollution, or a combination of these factors may have contributed to their development.

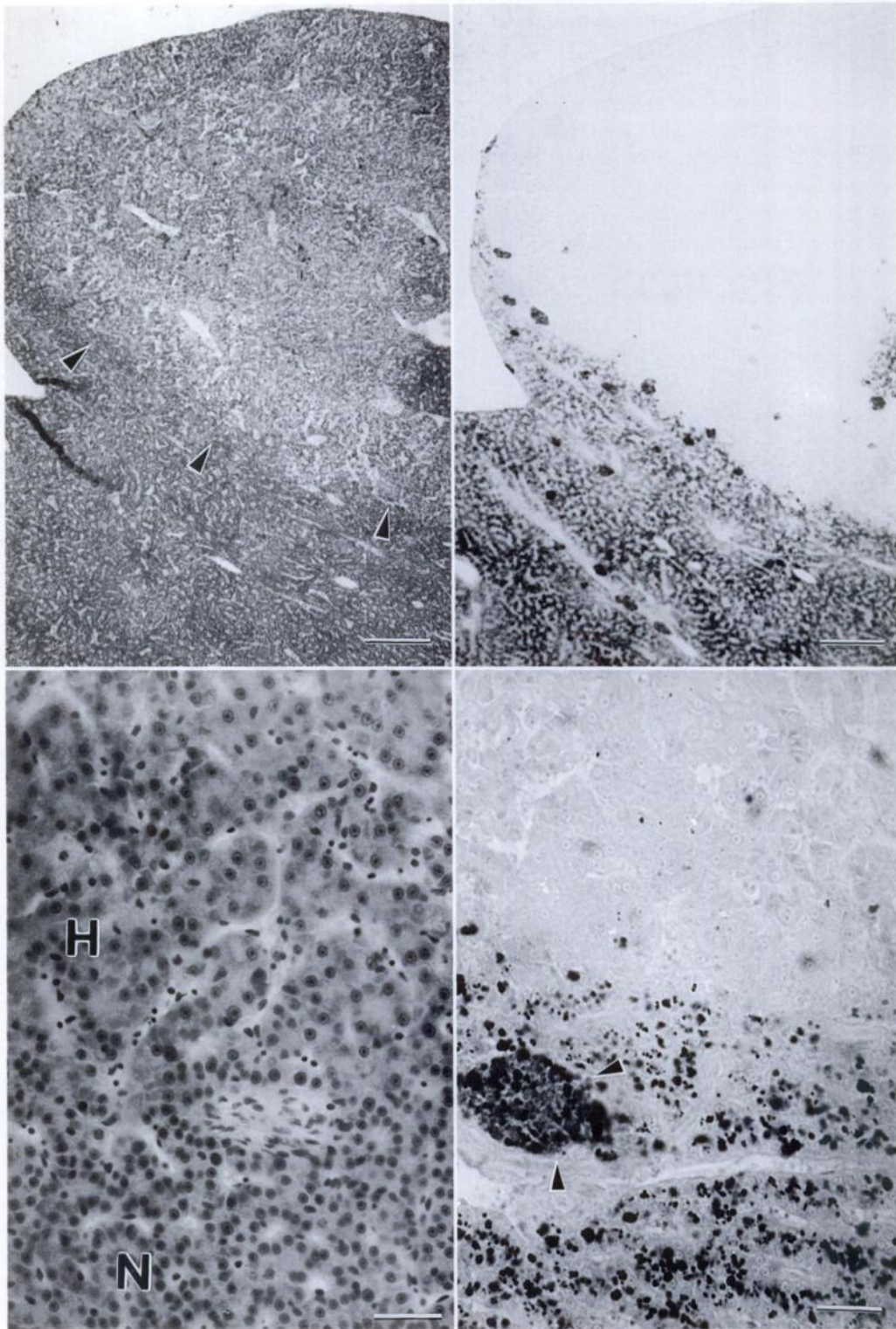
**Key words:** Carcinogenesis, liver, iron neoplasia, white perch, *Morone americana*.

The exclusion of iron from populations of altered and neoplastic hepatocytes has long been recognized as a marker in rodent carcinogenesis (Williams et al., 1976, 1979; Williams, 1976), and has also been seen in English sole (*Parophrys vetulus*) (Myers et al., 1987) and rainbow trout (*Salmo gairdneri*) (Lee et al., 1989). In contrast, copper levels are elevated in hepatocellular carcinoma compared to non-neoplastic liver in man (Haratake et al., 1986, 1987a, b). White perch (*Morone americana*) have a condition of hepatic copper storage characterized by an age-related, progressive accumulation of copper in hepatic lysosomes (Bunton et al., 1987), with evidence of secondary copper cytotoxicity when the lysosomal storage capacity is exceeded (Bunton and Frazier, 1990). Histologically, the presence of copper can be detected in

white perch with liver copper concentrations of greater than 85  $\mu\text{g/g}$  wet weight by the use of rubeinic acid histochemical stain (Bunton, 1990). In this report I describe the partial and total exclusion of copper from altered hepatocytes in an adult white perch with hepatic copper storage.

An adult female white perch weighing 261.3 grams and measuring 235 mm was part of a group of fish collected from the Chesapeake Bay (39°17'N, 76°28'W) from September to December 1990 to study hepatic copper storage in this species. At necropsy, the liver had many tan, slightly raised nodules of  $\leq 5$  mm diameter. The remaining hepatic parenchyma was dark reddish-brown. A portion of liver was analyzed for copper by atomic absorption spectrophotometry as described by Bunton et al. (1987) and other samples were fixed by immersion in Bouins fixative, embedded in paraffin, sectioned at 5.0  $\mu\text{m}$ , and stained with hematoxylin and eosin. Liver sections also were stained with rubeinic acid (Uzman, 1956) for copper and Perl's reagent for iron (Perls, 1867).

The hepatic copper concentration was 3,615  $\mu\text{g/g}$  wet weight liver, whereas control values from striped bass (*Morone saxatilis*) were previously determined to be 3 to 4  $\mu\text{g/g}$  (Bunton et al., 1987). Hepatocytes were filled with numerous large cytoplasmic granules which were positive for copper with rubeinic acid stain. Large aggregates of macrophages also stained positively for copper. The tan nodules seen grossly consisted of hypertrophied hepatocytes with abundant eosinophilic cytoplasm and karyomegaly, and degenerative hepatocytes with hypereosinophilic cytoplasm and condensed to pyknotic nuclei. The hypertrophied hepatocytes in some



lesions maintained a normal sinusoidal distribution, but in others were arranged in dense clusters. Compression was recognized by obliteration of sinusoids both within the lesions and in adjacent parenchyma. The presence of compression and disorganization in lesions was evidence that lesions were proliferative. With rubeinic acid stain, lesions were either completely negative for copper or contained varying amounts compared to the surrounding parenchyma (Figs. 1 to 4). Lesions completely devoid of copper or containing a minimal amount consisted primarily of hypertrophied hepatocytes, with degenerative cells eliciting most of the positive reactions. Lesions with compression were completely negative. There were additional lesions of variable size which differed from the others in that the hepatocytes within were identical morphologically to the surrounding hepatocytes. However, with rubeinic acid, they were sharply demarcated from surrounding parenchyma by an abrupt reduction in the amount of copper present (Fig. 5). Both normal parenchyma and lesions were negative for iron.

In white perch, an inherent abnormality in copper metabolism exists which results in the natural production of copper-loaded livers. The condition is age-related, with greater hepatic copper concentrations in larger, older fish (Bunton et al., 1987). The large size of the fish and high hepatic copper concentration are evidence for the chronicity of copper storage in this fish. However, the temporal relationship be-

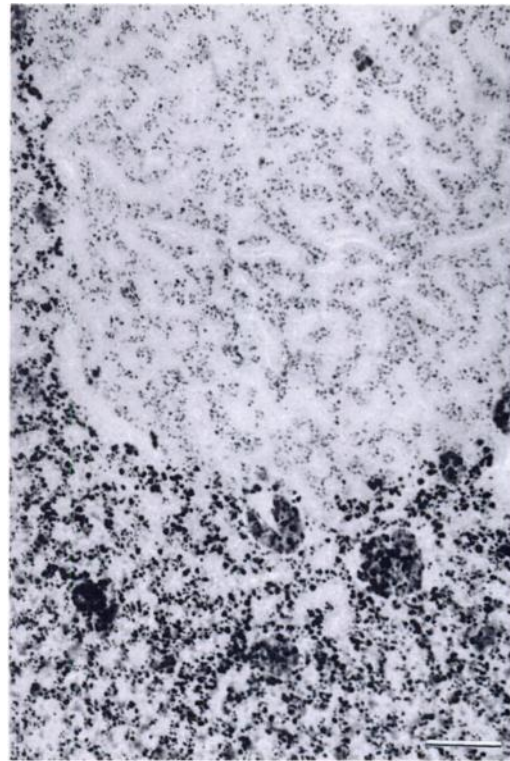


FIGURE 5. Well circumscribed focus of hepatocytes with an intermediate amount of cytoplasmic copper detected by rubeinic acid. This lesion would have been difficult to detect with H&E. Bar = 70  $\mu$ m.

tween the proliferative lesions seen in this case and cellular copper content is less clear. The initial lesion may have been cellular degeneration with secondary proliferation, with proliferative cells either having resistance to copper accumulation

←

FIGURE 1. Liver nodule which protruded above the normal surface. Border with normal parenchyma is delineated by arrows. H&E. Bar = 700  $\mu$ m.

FIGURE 2. Serial section from same area as Figure 1 stained with rubeinic acid has sharp demarcation of copper loaded hepatocytes from copper excluded nodular region. Bar = 700  $\mu$ m.

FIGURE 3. Area of normal hepatocytes (N) adjacent to hypertrophied (H) hepatocytes with abundant cytoplasm. H&E. Bar = 25  $\mu$ m.

FIGURE 4. Similar area as shown in Figure 3 stained with rubeinic acid. Copper-positive cytoplasmic granules in hepatocytes and macrophage aggregate (arrows) are absent from hypertrophied cells. Bar = 25  $\mu$ m.

or being in existence for too short a time to have accumulated detectable levels of copper. In contrast, hepatocytes in lesions containing intermediate levels of copper often appeared identical to surrounding hepatocytes and thus had not undergone an obvious morphologic change. It is not clear whether these lesions, often of substantial size, represented a separate clonal expansion of hepatocytes distinct from both normal and morphologically altered hepatocytes, or if they were a stage in the development or regression of the latter. Because this case represented only one time point, it was not possible to resolve these questions. However, this case raises interesting questions about mechanisms of metal exclusion from these types of lesions.

It was difficult to assess the nature of the lesions in this case, but some appeared to be proliferative and to progress to the point where compression and loss of normal architecture occurred. In a survey of estuarine tributaries of the Chesapeake Bay, various hyperplastic and neoplastic hepatic lesions in adult white perch were described (May et al., 1987) which included cholangiomas, clear cell foci and basophilic foci of cellular alteration. Five percent of the fish reportedly had hepatocellular neoplasms which were described as clear cell adenomas or basophilic neoplasms; the latter resembled basophilic foci but were larger in size with more irregular borders (May et al., 1987). The small basophilic cells described as comprising those lesions appeared to be distinct from the proliferative cells described here, but absent or diminished copper with rubeinic acid staining was reported in all lesions compared to surrounding hepatocytes.

The cause of the lesions seen in this case was not determined. Both intrinsic copper toxicity and exposure to environmental pollutants could be factors. Signs of intrinsic copper cytotoxicity in white perch included ultrastructural evidence of increased cytoplasmic and organelle turnover (Bunton and Frazier, 1989) but DNA damage could not be assessed. However, cop-

per is protective in some types of carcinogenesis (Howell, 1958), and hepatocellular carcinoma generally is not associated with Wilson's disease in humans (Wilkinson et al., 1983). Thus, environmental factors may have played a larger role in this case. Several chemical carcinogens and metals have been included on the Chesapeake Bay Toxics of Concern List (Chesapeake Bay Program, 1991). As fish are becoming increasingly important as sentinels of environmental pollution, it is important to recognize factors that may influence the biology of neoplasia in these species.

I thank the Department of Natural Resources for the acquisition of white perch. This work was supported in part by Public Health Service grant RR00130 from the National Institutes of Health.

#### LITERATURE CITED

- BUNTON, T. E. 1990. Comparison of three histochemical staining methods for the detection of copper in white perch (*Morone americana*). *Journal of Comparative Pathology* 102: 25-31.
- , AND J. M. FRAZIER. 1989. Hepatocellular ultrastructure in white perch (*Morone americana*) with abnormal hepatic copper storage. *Marine Environmental Research* 28: 375-382.
- , S.M. BAKSI, S. G. GEORGE, AND J. M. FRAZIER. 1987. Abnormal hepatic copper storage in a teleost fish (*Morone americana*). *Veterinary Pathology* 24: 515-524.
- CHESAPEAKE BAY PROGRAM. 1991. Chesapeake Bay toxics of concern list. Basinwide Toxics Reduction Strategy Commitment Report. Chesapeake Bay Program Toxics Subcommittee's and Living Resources Subcommittee's Joint Criteria and Standards Workgroup. U.S. Environmental Protection Agency, Washington, D.C., pp. 1-7.
- HARATAKE, J., A. HORIE, NAKASHIMA, S. TAKEDA, AND A. MORI. 1986. Minute hepatoma with excessive copper accumulation. *Archives of Pathology and Laboratory Medicine* 110: 192-194.
- , ———, AND S. TAKEDA. 1987a. Histochemical and ultrastructural study of copper-binding protein in hepatocellular carcinoma. *Cancer* 60: 1269-1274.
- , ———, ———, K. KOBORI, H. SATO, AND S. TOKUDOME. 1987b. Tissue copper content in primary and metastatic liver cancers. *Acta Pathologica Japonica* 37: 231-238.
- HOWELL, J. S. 1958. The effect of copper acetate

- on p-dimethylaminoazobenzene carcinogenesis in the rat. *British Journal of Cancer* 12: 594-608.
- LEE, B. C., J. D. HENDRICKS, AND G. S. BAILEY. 1989. Iron resistance of hepatic lesions and nephroblastoma in rainbow trout (*Salmo gairdneri*) exposed to MNNG. *Toxicologic Pathology* 17: 474-482.
- MAY, E. B., R. LUKACOVIC, H. KING, AND M. M. LIPSKY. 1987. Hyperplastic and neoplastic alterations in the liver of white perch (*Morone americana*) from the Chesapeake Bay. *Journal of the National Cancer Institute* 79: 137-143.
- MYERS, M. S., L. D. RHODES, AND B. B. MCCAIN. 1987. Pathologic anatomy and patterns of occurrence of hepatic neoplasms, putative preneoplastic lesions, and other idiopathic hepatic conditions in English sole (*Parophrys vetulus*) from Puget Sound, Washington. *Journal of the National Cancer Institute* 78: 333-363.
- PERLS, M. 1867. Nachweis von Eisenoxyl in gewissen Pigmenten. *Virchows Archive für Pathologische Anatomie und für Klinische Medizin* 39: 42-48.
- UZMAN, L. L. 1956. Histochemical localization of copper with rubeinic acid. *Laboratory Investigation* 3: 299-305.
- WILKINSON, M. L., B. PORTMANN, AND R. WILLIAMS. 1983. Wilson's disease and hepatocellular carcinoma: Possible protective role of copper. *Gut* 24: 767-771.
- WILLIAMS, G. M. 1976. Functional markers and growth behavior in preneoplastic hepatocytes. *Cancer Research* 36: 2540-2543.
- , M. KLAIBER, S. E. PARKER, AND E. FARBER. 1976. Nature of early appearing, carcinogen-induced liver lesions resistant to iron accumulation. *Journal of the National Cancer Institute* 57: 157-165.
- , N. HIROTA, AND J. M. RICE. 1979. The resistance of spontaneous mouse hepatocellular neoplasms to iron accumulation during rapid iron loading by parenteral administration and their transplantability. *American Journal of Pathology* 94: 65-74.

*Received for publication 20 August 1993.*