

Fusarium solani Fungal Infection of the Lateral Line Canal System in Captive Scalloped Hammerhead Sharks (*Sphyma lewini*) in Hawaii

Authors: Crow, Gerald L., Brock, James A., and Kaiser, Steve

Source: Journal of Wildlife Diseases, 31(4) : 562-565

Published By: Wildlife Disease Association

URL: <https://doi.org/10.7589/0090-3558-31.4.562>

BioOne Complete (complete.BioOne.org) is a full-text database of 200 subscribed and open-access titles in the biological, ecological, and environmental sciences published by nonprofit societies, associations, museums, institutions, and presses.

Your use of this PDF, the BioOne Complete website, and all posted and associated content indicates your acceptance of BioOne's Terms of Use, available at www.bioone.org/terms-of-use.

Usage of BioOne Complete content is strictly limited to personal, educational, and non - commercial use. Commercial inquiries or rights and permissions requests should be directed to the individual publisher as copyright holder.

BioOne sees sustainable scholarly publishing as an inherently collaborative enterprise connecting authors, nonprofit publishers, academic institutions, research libraries, and research funders in the common goal of maximizing access to critical research.

***Fusarium solani* Fungal Infection of the Lateral Line Canal System in Captive Scalloped Hammerhead Sharks (*Sphyrna lewini*) in Hawaii**

Gerald L. Crow,¹ James A. Brock,² and Steve Kaiser,^{3,4} ¹ Waikiki Aquarium, School of Ocean and Earth Science and Technology, University of Hawaii, 2777 Kalakaua Ave., Honolulu, Hawaii 96815, USA; ² Aquaculture Development Program, State of Hawaii, Honolulu, Hawaii 96813, USA; ³ Sea Life Park Hawaii, Makapuu Pt., Waimanalo, Hawaii 96795, USA; ⁴ Current address: Atlantis at Paradise Island, P.O. Box N4777, Naussau, Bahamas

ABSTRACT: Two of five scalloped hammerhead sharks (*Sphyrna lewini*) captured May 1987 in Hawaii (USA) developed granulomatous exudative mycotic dermatitis localized in the lateral line canal system. The lesion initially was noted in the cephalic canals, but over a period of months extended into the lateral canal. *Fusarium solani* and *Vibrio* spp. were isolated from the canal exudate of both sharks. Bacterial colonies were not observed in the canal walls or surrounding tissues. *Fusarium solani* infection resulted in a chronic physical and behavioral deterioration of the two sharks; one shark was euthanized in September 1988 and the other in July 1989. This is the first report of *Fusarium solani* infection in the lateral line canal system and the third account in hammerhead sharks.

Key words: Husbandry, shark pathology, *Fusarium solani*, *Sphyrna lewini*, hammerhead shark mycoses, granulomatous response.

An infection of the fungus *Fusarium solani* was described from the bonnethead shark (*Sphyrna tiburo*) maintained in a public aquarium (Muhvich et al., 1989). The infection resulted in a chronic myositis with fungal hyphae penetration into cartilage (Muhvich et al., 1989). *Aureobasidium* sp. (= *Pullularia* sp.) (Otte, 1964) and *Exophiala pisciphila* (Gaskins and Cheung, 1986) are two other fungi known from mycoses of elasmobranchs. Noga (1990) provides an excellent review of fungal diseases of marine poikilothermic animals.

Kaneohe Bay (21°30'N, 157°50'W), the island of Oahu, Hawaii (USA) is one of the pupping grounds for the scalloped hammerhead shark (*Sphyrna lewini*) in the Hawaiian Islands. In May 1987, five juvenile *S. lewini* (fork length of 402 to 488 mm) were captured by hook and line, transported in a boat live-well for release

into the Sea Life Park Hawaii's reef tank, Makapuu, Oahu. The reef tank is a 1,135,550 l system supplied with saltwater from a well. Saltwater flow to the tank was approximately 15,000 l/min. Water quality parameters ranged as follows: temperature 23 to 25 C, salinity 32 to 35 parts per thousand, pH 7.43 to 7.96, oxygen 5.56 to 5.88 mg/l, total ammonium 0.009 to 0.153 mg-N/l, and nitrite-nitrate 0.721 to 0.772 mg-N/l. A wide variety of Hawaiian teleost fish, hammerhead sharks, and the stingray (*Dasyatis latus*) are displayed in the exhibit. The hammerhead sharks were fed a diet of previously frozen smelt (*Mallotus villosus*), herring (*Clupea harengus*), and squid (*Loligo* sp.).

In June 1988, one shark (shark A) was observed with swollen cephalic canal pores of the lateral line canal system. A whitish colored viscous fluid was visible as a discharge from the pores. Over the next 3 mo, the swelling progressively increased and spread throughout the entire lateral line canal system of the shark. A second shark (shark B) began to have similar physical signs in February 1989. Alterations of swimming patterns were noted in both sharks. Changes in swim-glide patterns, slow swimming and occasional rapid burst swimming behavior were observed with increased frequency as the disease progressed. In the final stages, shark B began to bump the tank rock decor which resulted in a ruptured right eye. Due to their debilitated condition both sharks were euthanized by a spear shot which severed the spinal cord; shark A was killed on 29 September 1988 and shark B was killed on 20 July 1989.

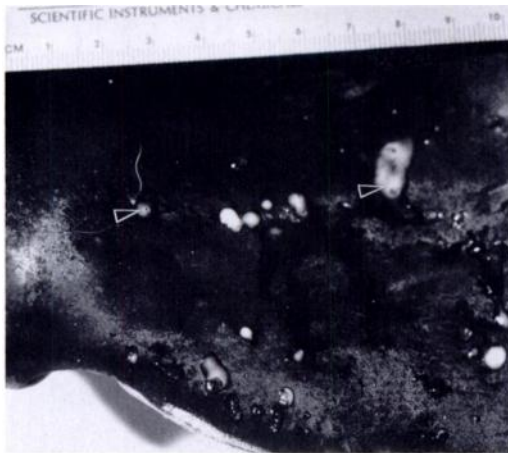


FIGURE 1. Right side of the laterally expanded head of a scalloped hammerhead shark (*Sphyrna lewini*). Note swollen canal pores and the white exudative fluid discharge (arrowheads) from the supraorbital cephalic canal of the lateral line.

Both male sharks were necropsied. Shark A was 978 mm and shark B was 1,079 mm in fork length. Both animals had an extensive white exudate with traces of blood throughout the lateral line system (Figs. 1 and 2). The exudate was more pronounced in the supraorbital and infraorbital canals. No other gross changes were noted.

The cephalic canals were sampled for the presence of bacteria by inoculating brain heart infusion agar supplemented with 2% NaCl and sheep's blood, and thiosulfate citrate bile salts agar (Difco Lab-

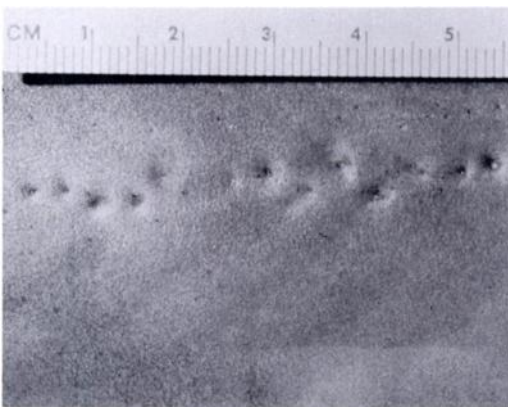


FIGURE 2. Swollen lateral canal pores of a scalloped hammerhead shark (*Sphyrna lewini*).

oratories, Detroit, Michigan, USA). Bacteria isolated from the samples were identified by the Gram stain, oxidase test (Organin Teknika Corporation, Durham, North Carolina, USA), and API 20E system (Bio Merieux Vitek, Inc., Hazelwood, Missouri, USA). The canal exudate was also inoculated onto Sabouraud dextrose agar (Difco Laboratories) supplemented with 2% NaCl containing 10,000 IU/ml penicillin, 40,000 mcg/ml streptomycin, and actidione 10 mg/ml (all from Sigma Chemicals, St. Louis, Missouri).

Samples of brain, cephalic canals, lateral line, liver, spleen, pancreas, and kidney were collected from both sharks and placed in 10% neutral buffered formalin for histopathological evaluation. Tissues were embedded in paraffin, sectioned at 5 μ m, and stained with hematoxylin and eosin. Selected sections were stained with Gomori methenamine silver nitrate and periodic acid Schiff (Humason, 1979).

Microscopically in cross section the lateral line canal was engorged with exudate (Fig. 3) composed of epithelioid cells, macrophages, neutrophils, red blood cells, and occasional fungal hyphae (Fig. 4). Epithelioid cells were widespread, infiltrating the canal walls (Fig. 5), adjacent muscle, and connective tissues. Bacterial colonies were not observed in the canal wall or surrounding tissues. Overall, the host response was localized and best characterized as chronic and granulomatous. Internal organs were unremarkable microscopically.

The following microorganisms were isolated from the lateral line exudate of the sharks. Bacteria: *Vibrio damsela* (sharks A and B) and *V. alginolyticus* (shark A). Fungus: *Fusarium solani* was recovered from both sharks. *Fusarium solani* from shark B was identified by P. Nelson (Nelson et al., 1983) deposited in the Fusarium Research Center (Department of Plant Pathology, The Pennsylvania State University, University Park, Pennsylvania, USA; accession number S-1227).

In these scalloped hammerhead sharks, *Fusarium solani* produced a granuloma-

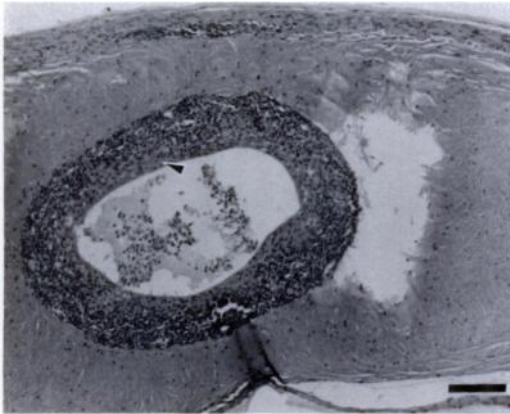


FIGURE 3. Cross section of lateral line canal with chronic inflammation (arrowhead) and exudative fluid present in canal of a scalloped hammerhead shark (*Sphyrna lewini*). H&E. Bar = 100 μ m.

tous exudative mycotic dermatitis of the lateral line canal system. A granulomatous response to pathogens has been reported in elasmobranchs from a fungal liver infection (Otte, 1964) and nematode infections of the brain, ovary, and uterus (Credille et al., 1993).

The rapid growth of husbandry techniques now allows for the routine housing of 70 shark species. The following sharks have been maintained at Sea Life Park Hawaii's reef tank with no clinical signs of mycoses (maximum longevity in parentheses): *Carcharhinus galapagensis* (6 yr), *C. melanopterus* (4 yr), *C. amblyrhynchos* (3 yr), *Triaenodon obesus* (4 yr), *Negaprion acutidens* (5 yr), *Ginglymostoma cirratum* (6 yr).

Many factors could be associated with *Fusarium solani* infection. *Fusarium* spp. are common aquatic fungi in water pipes and tanks (Austwick, 1984). Cuticular abrasion followed by fungal colonization of wounds is well documented in crustaceans (Brock and Lightner, 1990) and skin abrasion colonization in sharks also is likely (Muhvich et al., 1989).

Resistance to disease (Fries, 1986), environmental stressors, and species or age characteristics could be important to *Fusarium* spp. infection of sharks. An ana-

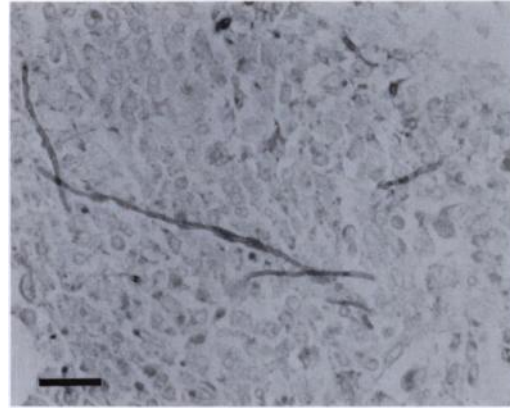


FIGURE 4. *Fusarium solani* hyphae in the cephalic canal exudate of a scalloped hammerhead shark (*Sphyrna lewini*). PAS. Bar = 25 μ m.

tomical feature characteristic of hammerhead sharks may also be associated with *Fusarium* spp. infection. The lateral expansion of the head of hammerhead sharks as illustrated for *Cestracion* (= *Sphyrna*) *tiburo* (Garman, 1888) and *Sphyrna zygaena* (von Bonde, 1933) has altered the cephalic canals.

We believe that the debilitating nature of *F. solani* infection and the absence of internal organ involvement raises intriguing questions about mycotoxin production. Smith et al. (1989) speculated about *F. solani* toxigenic capabilities. However, the knowledge of *F. solani* ability to produce

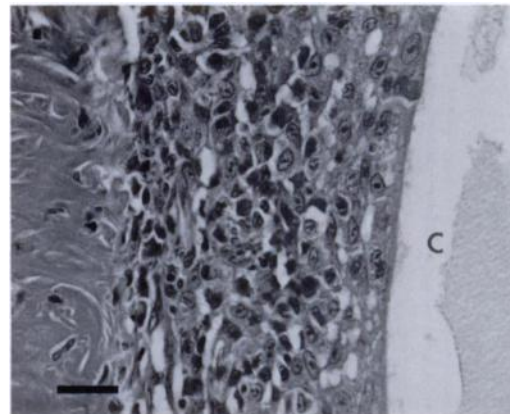


FIGURE 5. Granulomatous inflammation of the cephalic canal (C) wall of a scalloped hammerhead shark (*Sphyrna lewini*). H&E. Bar = 25 μ m.

mycotoxin(s) is still only rudimentary and more detailed studies are needed (Marasas et al., 1984).

This is the first report of *Fusarium solani* infection in the scalloped hammerhead shark *Sphyrna lewini* and an infection of the lateral line canal system. It is the third account of *F. solani* in hammerhead sharks. An immunocompromised hammerhead shark, an anatomical characteristic, or physiological response may predispose them to "fusariomycosis" in captive facilities.

The authors thank Sea Life Park Hawaii administrators for allowing active research, P. Nelson for positively identifying *F. solani* and placing it in the collection, R. Young of Oceanic Institute for water analysis and C. Lau for photographs of Figures 1 and 2, and B. Carlson, C. Hopper, and K. Yates for their manuscript review. We also gratefully acknowledge the Aquaculture Development Program, Department of Land and Natural Resources, State of Hawaii for financial support and the Veterinary Diagnostic Laboratory, Department of Agriculture, State of Hawaii for use of facilities, and laboratory work carried out on this project.

LITERATURE CITED

- AUSTWICK, P. K. C. 1984. *Fusarium* infections in man and animals. In *The applied mycology of Fusarium*, M. O. Moss and J. E. Smith (eds.). Cambridge University Press, Cambridge, London, United Kingdom, pp. 129-140.
- BROCK, J. A., AND D. V. LIGHTNER. 1990. Diseases of Crustacea. In *Diseases of marine animals*, Vol. 3, O. Kinne (ed.). Biologische Anstalt Helgoland, Hamburg, Germany, pp. 245-349.
- CREDILLE, K. M., L. K. JOHNSON, AND R. REIMSCHUESSEL. 1993. Parasitic meningoencephalitis in nurse sharks (*Ginglymostoma cirratum*). *Journal of Wildlife Diseases* 29: 502-506.
- FRIES, C. R. 1986. Effects of environmental stressors and immunosuppressants on immunity in *Fundulus heteroclitus*. *American Zoologist* 26: 271-282.
- GARMAN, G. 1888. On the lateral line canal system of the Selachia and Holocephala. *Bulletin of the Museum of Comparative Zoology, Harvard* 17: 57-119.
- GASKINS, J. E., AND P. J. CHEUNG. 1986. *Exophiala pisciphila* a study of its development. *Mycopathologia* 93: 173-184.
- HUMASON, G. L. 1979. *Animal tissue techniques*, 4th ed. W. H. Freeman, San Francisco, California, 661 pp.
- MARASAS, W. F. O., P. E. NELSON, AND T. A. TOUSSOUN. 1984. Sections Martinella and Ventricosum. In *Toxigenic Fusarium species identity and mycotoxicology*. The Pennsylvania State University Press, University Park, Pennsylvania, pp. 263-272.
- MUHVICH, A. G., R. REIMSCHUESSEL, M. M. LIPSKY, AND R. O. BENNETT. 1989. *Fusarium solani* isolated from newborn bonnethead sharks, *Sphyrna tiburo* (L.). *Journal of Fish Diseases* 12: 57-62.
- NELSON, P. E., T. A. TOUSSOUN, AND W. F. O. MARASAS. 1983. *Fusarium* species: An illustrated manual for identification. The Pennsylvania State University Press, University Park, Pennsylvania, 193 pp.
- NOGA, E. J. 1990. A synopsis of mycotic diseases of marine fishes and invertebrates. In *Pathology in marine science*, F. O. Perkins and T. C. Cheng (eds.). Academic Press, San Diego, California, pp. 143-160.
- OTTE, E. 1964. Eine Mykose bei einem Stachelrochen (*Trigon pastinacae* L.). *Wiener Tierärztliche Monatsschrift* 51: 171-175.
- SMITH, A. G., A. G. MUHVICH, K. H. MUHVICH, AND C. WOOD. 1989. Fatal *Fusarium solani* infections in baby sharks. *Journal of Medical and Veterinary Mycology* 27: 83-91.
- VON BONDE, C. 1933. Contributions to the morphology of the Elasmobranchii I. The craniology and neurology of a hammerhead shark, *Sphyrna (Cestracion) zygaena* (Linnaeus). *Journal of Comparative Neurology* 58: 377-403.

Received for publication 25 June 1994.