

Protozoan Parasites and Pathological Findings in *Hydromys Chrysogaster* (Muridae: Hydromyinae) From Queensland

Authors: L. R. Smales, and D. L. Obendorf

Source: Journal of Wildlife Diseases, 32(2) : 344-347

Published By: Wildlife Disease Association

URL: <https://doi.org/10.7589/0090-3558-32.2.344>

BioOne Complete (complete.BioOne.org) is a full-text database of 200 subscribed and open-access titles in the biological, ecological, and environmental sciences published by nonprofit societies, associations, museums, institutions, and presses.

Your use of this PDF, the BioOne Complete website, and all posted and associated content indicates your acceptance of BioOne's Terms of Use, available at www.bioone.org/terms-of-use.

Usage of BioOne Complete content is strictly limited to personal, educational, and non-commercial use. Commercial inquiries or rights and permissions requests should be directed to the individual publisher as copyright holder.

BioOne sees sustainable scholarly publishing as an inherently collaborative enterprise connecting authors, nonprofit publishers, academic institutions, research libraries, and research funders in the common goal of maximizing access to critical research.

Protozoan Parasites and Pathological Findings in *Hydromys Chrysogaster* (Muridae: Hydromyinae) From Queensland

L. R. Smales¹ and D. L. Obendorf,^{2,1}The Department of Biology, Central Queensland University, Rockhampton, Queensland 4702, Australia. ²Tasmanian Department of Primary Industry and Fisheries, Mount Pleasant Laboratories, Kings Meadows, Tasmania 7249, Australia

ABSTRACT: Tissues from 23 Australian water rats (*Hydromys chrysogaster*) collected from five localities in central and northern Queensland, Australia, between February 1992 and May 1993, were examined for protozoan parasites and additional pathological changes. We found *Klossiella hydromyos* in the kidneys, *Toxoplasma gondii* in the brain and skeletal muscles and *Sarcocystis* sp. in the somatic musculature. Other pathological findings, including interstitial nephritis, interstitial pneumonia and a tongue abscess, as well as helminth-induced lesions in the lungs, mesenteries, stomach wall and cecal wall were also noted.

Key words: Protozoa, parasites, pathology, Australian water rat, *Hydromys chrysogaster*, Queensland.

The Australian water rat, *Hydromys chrysogaster*, Geoffroy 1804, is found only in Australia, New Guinea, and associated islands, where it inhabits permanent bodies of freshwater or brackish water, and ocean beaches (Olsen, 1991).

Surveys of the parasites and pathology of water rats, including protozoa, have been carried out in Tasmania (Obendorf and Smales, 1985), Victoria and South Australia (Smales et al., 1990) and northern Queensland (Glazebrook et al., 1977, 1978). In this study, the prevalence of protozoa and any associated pathological findings in water rats from central and northern Queensland were determined. Twenty-three water rats were live-trapped, in collapsible wire box traps (Australian Entomological Supplies, Coorabell via Bangalow, New South Wales, Australia), using bread and sardine baits, from central and northern Queensland between February 1992 and May 1993. Eight water rats were collected from the town reaches of the Ross River, Townsville (19°19'S, 146°44'E); eight from the town reaches of the Fitzroy River, Rockhampton (23°21'S,

150°29'E); three from Wild Duck Island, Shoalwater Bay (22°0'S, 149°52'E); three from Rosslyn Bay boat harbor, central Queensland coast (23°10'S, 150°47'E) and one from Kurrimine Beach, northern Queensland coast (17°48'S, 146°6'E). Animals were euthanized by overdose with pentobarbitone sodium (Nembutal®) (Boehringer Ingelheim Pty Ltd., Artarmon, New South Wales, Australia) injected intraperitoneally. The external surface, nares, and oral cavity of each water rat was examined macroscopically for lesions. The subcutaneous tissues, body cavities, mesenteries and viscera were examined under a dissecting microscope. Pieces of skeletal muscle were taken from the thigh of each water rat as was tissue from the diaphragm, tongue, esophagus, stomach, jejunum, colon, liver, spleen, kidney, adrenal gland, urinary bladder, and brain. Tissues were fixed in 10% formalin, embedded in paraffin, sectioned at 5 µm, and stained with hematoxylin and eosin. The presence and location of protozoan species and any associated pathology was recorded. Protozoa were identified following Barker et al. (1975) and Munday et al. (1978).

Three species of protozoan parasites were identified: *Klossiella hydromyos* Winter and Watts, 1971; *Toxoplasma gondii* Nicolle and Manceau, 1908; and *Sarcocystis* spp. Lancaster, 1882 (Table 1). *Klossiella hydromyos*, originally described from the kidneys of a water rat from Brisbane (Winter and Watt, 1971), was reported in 14 of 355 rodents from north Queensland by Glazebrook et al. (1977), but they did not specify the prevalence in water rats. The occurrence of *K. hydromyos* in all areas surveyed in this study, including the isolated off shore Wild Duck

TABLE 1. Protozoan parasites found in 23 *Hydromys chrysogaster* from sites in central and northern Queensland, 1992 to 1993.

Site	<i>Klossiella hydromyos</i> (kidney)	<i>Toxoplasma gondii</i> (brain)	<i>Sarcocystis</i> spp. ^a (skeletal muscle)	<i>Toxoplasma gondii</i> and/or <i>Sarcocystis</i> spp. ^b (skeletal muscle)
Kurrimine Beach	1/1 ^c	0/1	1/1	0/1
Ross River	7/8	2/8	1/8	2/8
Wild Duck Island	1/3	0/3	0/3	0/3
Fitzroy River	3/8	2/8	0/8	4/8
Roslyn Bay	2/3	1/3	0/8	3/3
Totals for infected localities	14/23	5/19	2/9	9/19
Total prevalence (%), all localities	60	22	9	39

^a Thick-walled muscle cysts with large zooites, up to 12 μ m.

^b Thin-walled muscle cysts with small zooites, up to 8 μ m (After Munday et al., 1978).

^c Number infected/number sampled.

Island is evidence that this coccidian is a common parasite of Queensland water rats (Fig. 1). Since *K. hydromyos* also has been reported from Victoria and South Australia (Smales et al., 1990) but not Tasmania (Barker et al., 1975; Obendorf and Smales, 1985) it probably is found only throughout mainland Australia. *Klossiella* spp. are regarded as benign protozoa of the renal tubules of a wide range of Australian marsupials (Barker et al., 1975) as well as rodents (Winter and Watt, 1971).

Cysts, typical of *Toxoplasma gondii* (Munday et al., 1978), were found in the brains of five water rats (Fig. 2). In four animals the cysts were not associated with any host inflammatory responses. In one

animal, however, the cysts were associated with a focal non-suppurative inflammation of the surrounding brain tissue. The widespread occurrence of *T. gondii* throughout Australia (Munday et al., 1978) coincides with the distribution of the definitive host *Felis catus*. In northern Queensland, water rats were considered by Glazebrook et al. (1977) to be significant rodent carriers of *T. gondii* and the relatively high prevalence of *T. gondii* (22%) in this study supported that view. *Toxoplasma gondii* cysts were not found in any of the water rats from Wild Duck Island. This result was expected because cats do not occur on this presently uninhabited island. Definitive *T. gondii* status of rodents from Wild Duck Island would require a larger sampling

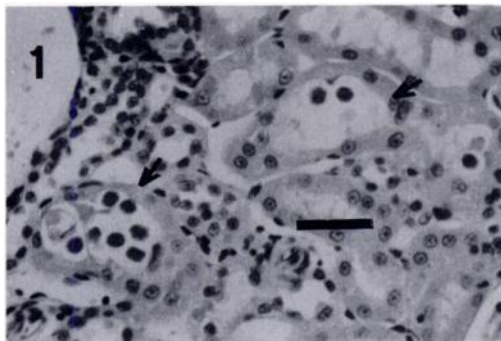


FIGURE 1. *Klossiella hydromyos* sporocysts in the kidney tubules of *Hydromys chrysogaster* H&E. Bar = 25 μ m.

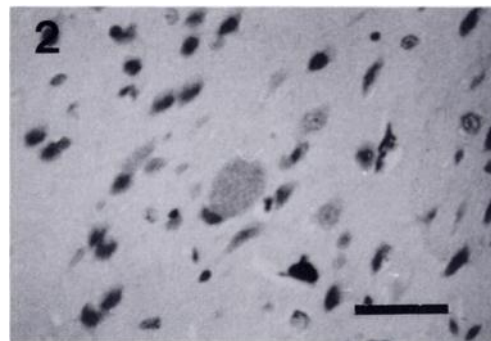


FIGURE 2. *Toxoplasma gondii* cyst in the brain of *Hydromys chrysogaster*. H&E. Bar = 20 μ m.

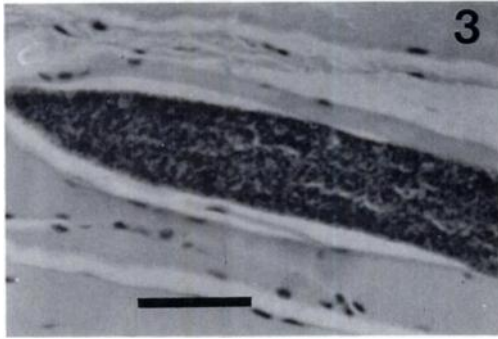


FIGURE 3. Thin-walled cyst in the skeletal muscle tissue of *Hydromys chrysogaster*. H&E. Bar = 100 μ m.

with serological testing of blood for the presence of *T. gondii* antibodies.

Eleven water rats had either thick-walled or thin-walled protozoal cysts, in skeletal muscle tissue (Table 1): The thick-walled cysts with large zoites were typical of *Sarcocystis* spp., previously found in water rats from Tasmania (Obendorf and Smales, 1985) and Victoria (Smales et al., 1990). *Sarcocystis* spp. have not previously been recorded from Queensland water rats. The thin-walled cysts with small zoites had features that were more typical of *T. gondii* than *Sarcocystis* spp., but could not be differentiated conclusively (Fig. 3). Intestinal coccidia were not specifically looked for using fecal flotation techniques, but no stages of these parasites were detected in histological sections of intestinal walls.

A number of other pathological conditions were detected. Cysts containing metacestodes were detected in the mesentery of one animal from Townsville. Such cysts have not previously been recorded from water rats.

The water rat from Kurrimine Beach had a small abscess on the tongue caused by a penetrating foreign body. Four animals, two from Townsville, one from Rockhampton and one from Rosslyn Bay, had mast cell infiltrates in the musculature of the tongue; this may have been an inflammatory reaction to a parasitic (possibly

nematode) infection. In two animals from Wild Duck Island, a nematode was detected in the epithelial lining of the tongue. Nematode infections have not previously been reported from this site in the water rat.

A submucosal granuloma, containing a nematode, was found in the gastric mucosa of one animal from Townsville; lesions containing larval nematodes and nematode associated parasitic submucosal nodules were found in two other animals from Townsville. Similar specimens from the mesenteries and stomach of water rats from Innisfail northern Queensland, labelled *Ophidascaris robertsi* (Sprent and Mines, 1960) Sprent and McKeown, 1979 are held in the Queensland Museum (GL 5678, G15680, GL7396 and G15690) All the specimens from this study however, as well as the museum collection, conform to the descriptions by Sprent (1970) of the larval stages of *Ophidascaris moreliae* Sprent, 1969. Although water rats from southern Australia commonly have nematode induced lesions in the stomach wall, these are caused by infection with the adult acuarioids *Antechiniella sertatum* Smales, 1991 and *Synhimantus australiensis* (Beveridge and Barker, 1975) Quentin and Beveridge, 1986 (Smales et al., 1990).

One animal from Wild Duck Island had an interstitial pneumonia with generalized thickening of the alveolar walls and aggregates of lymphocytes around airways and blood vessels. Glazebrook et al. (1977) reported interstitial pneumonia in 88 of 355 rodents from tropical habitats in northern Queensland, although it was not stated which of the 15 species examined were infected. Interstitial pneumonia was not found in water rats from southern locations (Obendorf and Smales, 1985; Smales et al., 1990). A nematode was associated with an eosinophilic peribronchitis in the animal from Kurrimine Beach (Fig. 4). Two animals from Townsville had focal interstitial nephritis.

We thank Karl French for his assistance with trapping and dissecting animals from

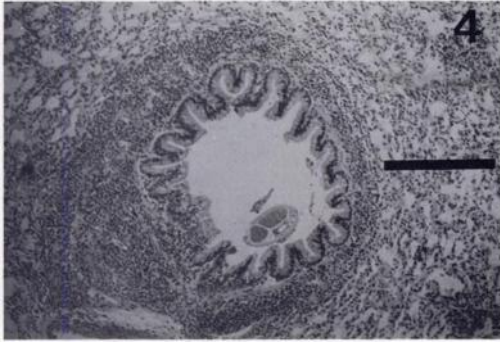


FIGURE 4. Nematode associated with eosinophilic peribronchiolitis in the lung of *Hydromys chrysogaster*. H&E. Bar = 190 μ m.

Central Queensland, and Dr. D. Spratt for assistance in nematode identification.

LITERATURE CITED

- BARKER, I. K., B. L. MUNDAY, AND K. E. HARRIGAN. 1975. *Klossiella* spp. in the kidneys of peramelid, petaurid and macropodid marsupials. *Zeitschrift für Parasitenkunde* 46: 35–41.
- GLAZEBROOK, J. S., R. S. F. CAMPBELL, AND G. W. HUTCHINSON. 1977. The pathology of feral rodents in north Queensland II. Studies on zoonotic infections. *Tropenmedizin und Parasitologie* 28: 545–551.
- _____, _____, _____, AND N. D. STALLMAN. 1978. The occurrence and distribution of zoonotic infections in north Queensland rodents. *Australian Journal of Experimental Biology and Medical Science* 56: 147–156.
- MUNDAY, B. L., R. W. MASON, W. J. HARTLEY, P. J. A. PRESIDENTE, AND D. L. OBENDORF. 1978. *Sarcocystis* and related organisms in Australian Wildlife: I. Survey findings in mammals. *Journal of Wildlife Diseases* 14: 417–433.
- OBENDORF, D. L., AND L. R. SMALES. 1985. The internal parasites and pathological findings in *Hydromys chrysogaster* (Muridae: Hydromyinae) from Tasmania. *Australian Journal of Zoology* 37: 657–663.
- OLSEN, P. D. 1991. Aquatic rats. In *Complete book of Australian mammals*, R. Strahan (ed.). Collins, Angus and Robertson, North Ryde, Australia, pp. 366–369.
- SMALES, L. R., A. K. MILLER, AND D. L. OBENDORF. 1990. Parasites of the water rat, *Hydromys chrysogaster*, from Victoria and New South Wales. *Australian Journal of Zoology* 37: 657–663.
- SPRENT, J. F. A. 1970. Studies on ascaridoid nematodes in pythons: The life history and development of *Ophidascaris moreliae* in Australian pythons. *Parasitology* 60: 97–122.
- WINTER, H., AND D. WATT. 1971. *Klossiella hydromyos* n.sp. from the kidneys of an Australian water rat (*Hydromys chrysogaster*). *Veterinary Pathology* 8: 222–231.

Received for publication 10 April 1995.