

Isolation of *Yersinia pseudotuberculosis* and *Listeria monocytogenes* Serotype 4 from a Gray Fox (*Urocyon cinereoargenteus*) with Canine Distemper

Authors: Sharon S. Black, Frank W. Austin, and Elise McKinley

Source: Journal of Wildlife Diseases, 32(2) : 362-366

Published By: Wildlife Disease Association

URL: <https://doi.org/10.7589/0090-3558-32.2.362>

BioOne Complete (complete.BioOne.org) is a full-text database of 200 subscribed and open-access titles in the biological, ecological, and environmental sciences published by nonprofit societies, associations, museums, institutions, and presses.

Your use of this PDF, the BioOne Complete website, and all posted and associated content indicates your acceptance of BioOne's Terms of Use, available at www.bioone.org/terms-of-use.

Usage of BioOne Complete content is strictly limited to personal, educational, and non-commercial use. Commercial inquiries or rights and permissions requests should be directed to the individual publisher as copyright holder.

BioOne sees sustainable scholarly publishing as an inherently collaborative enterprise connecting authors, nonprofit publishers, academic institutions, research libraries, and research funders in the common goal of maximizing access to critical research.

Isolation of *Yersinia pseudotuberculosis* and *Listeria monocytogenes* Serotype 4 from a Gray Fox (*Urocyon cinereoargenteus*) with Canine Distemper

Sharon S. Black, Frank W. Austin, and Elise McKinley, Diagnostic Laboratory Services, College of Veterinary Medicine, Mississippi State University, Mississippi State, Mississippi 39762, USA

ABSTRACT: In February 1993, clinical, pathological, and microbiological investigations were performed on an adult female gray fox (*Urocyon cinereoargenteus*) from northern Mississippi (USA). The fox had clinical signs consistent with canine distemper virus encephalitis. Eosinophilic inclusions characteristic of canine distemper virus were in the nuclei and cytoplasm of cerebral neurons and glial cells and in the cytoplasm of urinary, gastric, pancreatic and biliary epithelial cells. The liver contained multifocal microscopic nodular foci of granulomatous to pyogranulomatous inflammation and necrosis with large colonies of small Gram-negative coccobacilli. A low number of small Gram-positive bacilli were within viable-appearing Kupffer cells and hepatocytes. *Yersinia pseudotuberculosis* and *Listeria monocytogenes* serotype 4 were isolated from the liver and a mesenteric lymph node.

Key words: Gray fox, *Urocyon cinereoargenteus*, canine distemper, encephalitis, hepatitis, *Listeria monocytogenes*, *Yersinia pseudotuberculosis*.

The bacteria *Yersinia pseudotuberculosis* and *Listeria monocytogenes* are both global in distribution and prevalent in nature (Hubbert, 1972; Wetzler, 1981; Dijkstra, 1981), acquired by fecal-oral transmission (Baskin, 1980; Courtieu, 1991) and pathogenic in animals and humans (Hubbert, 1972; Wetzler, 1981; Courtieu, 1991). We report a case of coexisting infections of *Y. pseudotuberculosis* and *L. monocytogenes* in a wild gray fox (*Urocyon cinereoargenteus*) with canine distemper.

In February 1993, an adult female gray fox was found in a horse pasture in rural northern Mississippi, USA (33°26'N, 88°51'W). The fox was described as listless and ataxic, and it did not exhibit signs of fear upon close contact with humans. The fox was further examined at the Animal Health Center at the Mississippi State University College of Veterinary Medicine

where it had intermittent rhythmic chewing movements and twitching of the legs. Viral encephalitis due to either canine distemper or rabies was suspected. The fox was euthanized with a lethal dose (86 mg/kg) of barbiturate (Beuthanasia®-D Special; Schering-Plough Animal Health Corp., Kenilworth, New Jersey, USA) administered intravenously and necropsied.

The body condition of the fox was good. Approximately four 1 to 3 mm diameter white foci were on the surface of the liver and extended into the underlying parenchyma. The cranioventral lung lobes contained a few small focal areas of atelectasis and hyperemia. One half of the brain was submitted to the Mississippi State Board of Health, Public Health Laboratory for rabies direct fluorescent antibody (DFA) testing (Velleca and Forrester, 1981). Samples of brain, heart, lung, liver, kidney, urinary bladder, spleen, adrenal gland, thyroid gland, pancreas and gastrointestinal tract were fixed in neutral buffered 10% formalin for histopathology. These tissues were embedded in paraffin, sectioned at 5 µm, and stained with hematoxylin and eosin (H&E). Select microscopic sections of liver were stained with a Brown and Brenn Gram stain (Luna, 1960).

Fresh liver, kidney, and a mesenteric lymph node were evaluated for bacteriology. Specimens were directly plated on Trypticase Soy Agar (TSA) with 5% sheep blood, Colistin Nalidixic Acid (CNA) agar with 5% sheep blood, and MacConkey agar (all from Becton Dickinson Microbiology Systems (BBL®); Cockeysville, Maryland, USA) for isolation. Tissue specimens also were enriched in brain heart infusion broth (Difco, Detroit, Michigan,

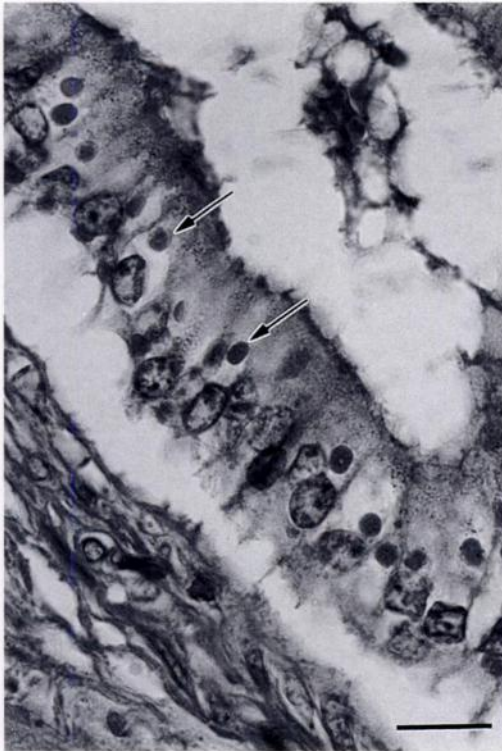


FIGURE 1. Numerous canine distemper virus inclusions (arrows) in the cytoplasm of intrahepatic biliary epithelium in the liver of a gray fox. H&E. Bar = 20 μ m.

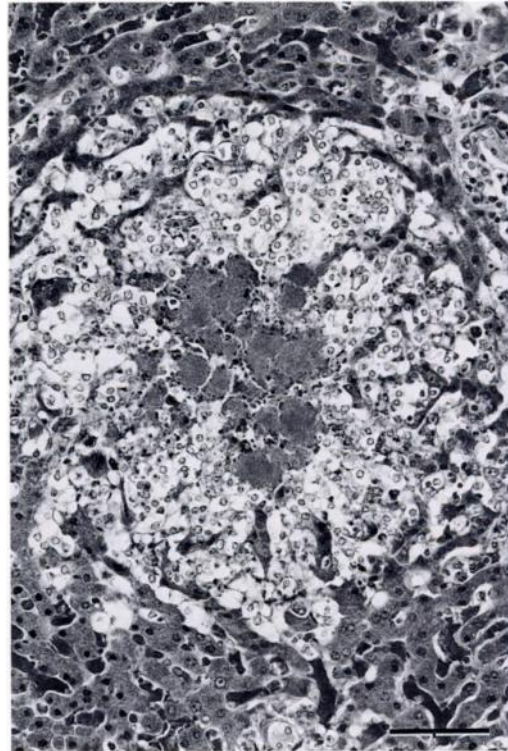


FIGURE 2. Nodular focus of necrosis and granulomatous inflammation containing colonies of *Yersinia pseudotuberculosis* in the liver of a gray fox. H&E. Bar = 160 μ m.

USA) and used to inoculate CDC (Centers for Disease Control) anaerobic agar plates (BBL[®]) which were incubated in anaerobic BIO-BAGS (BBL[®]). All cultures were incubated at 37 C and examined daily for growth.

Microscopically, the cerebral white matter had mild lymphocytic perivascular cuffing and vacuolization of the neuropil characteristic of demyelination. Small numbers of eosinophilic intranuclear and intracytoplasmic inclusions in neurons and glial cells of the cortical gray matter were characteristic of canine distemper virus. Similar inclusions were numerous in the cytoplasm of the epithelial cells of the urinary bladder mucosa, renal pelves, gastric mucosa, pancreatic ducts, and intrahepatic bile ducts (Fig. 1); the extrahepatic biliary epithelium was not examined. The liver contained many randomly distributed, 50

to 500 μ m diameter foci of inflammation and necrosis consisting of nodular accumulations of macrophages with small numbers of neutrophils (Fig. 2). Most of these foci contained colonies of bacteria that appeared finely granular and lightly basophilic in H&E-stained sections. The bacterial colonies were composed of small Gram-negative coccobacilli. A few Gram-positive bacilli were in the cytoplasm of viable-appearing Kupffer cells and hepatocytes scattered throughout the hepatic parenchyma. The histopathologic findings were consistent with demyelinating encephalitis due to canine distemper virus and multifocal granulomatous to pyogranulomatous bacterial hepatitis. Differential etiologic diagnoses considered for the hepatitis were *Yersinia pseudotuberculosis*, *Yersinia pestis*, *Salmonella* spp. and *Francisella tularensis*.

Cultures of the liver and lymph node each produced heavy growth of single Gram-negative and Gram-positive rod isolates after 24 to 48 hr incubation following direct plating on TSA, CNA agar, and MacConkey agar; no growth was obtained from the kidney cultured on these media. Brain heart infusion broth enrichment cultures of liver, lymph node, and kidney did not contain recognized pathogens when subcultured on CDC anaerobic agar plates. No obligate anaerobes were isolated. *Yersinia pseudotuberculosis* was identified using the API 20E® system (bioMerieux Vitek, Hazelwood, Missouri, USA) and cytochrome C oxidase testing. *Listeria monocytogenes* was identified using the API Coryne® system (bioMerieux Vitek) along with a Christie, Atkins, and Muench-Petersen (CAMP) test (Christie et al., 1944) and a motility test (Bille and Doyle, 1991). *Listeria monocytogenes* was further characterized as serotype 4 using Bacto-*Listeria* O Antisera types 1, 4 and Poly (Difco) in the rapid slide test. Both isolates were cryopreserved and placed in the Pathogen Repository at the College of Veterinary Medicine. The rabies DFA test on the brain was negative.

Canine distemper is a viral disease of Canidae, Mustelidae, and Procyonidae worldwide and has been documented in a variety of wild and captive fox species, including the gray fox (Budd, 1981). In a recent 18-yr survey of diseases diagnosed in gray foxes from the southeastern United States, canine distemper contributed to mortalities in the gray fox population more often than any other infectious or noninfectious disease; some foxes had toxoplasmosis or cryptosporidiosis concurrently with distemper (Davidson et al., 1992a). Listeriosis concurrent with distemper in a gray fox has been reported by Jakowski and Wyand (1971). Salmonellosis and adenovirus infections were reported in unvaccinated ranch foxes with distemper (Ayroud et al., 1992). The immunosuppressive effect of distemper in dogs is well-docu-

mented and may predispose them to other infectious diseases (Dungworth, 1993).

Yersinia pseudotuberculosis is a Gram-negative coccobacillus that is worldwide in distribution and infects humans and a wide variety of wild and domestic mammals and birds (Hubbert, 1972; Wetzler, 1981). Epizootics of *Y. pseudotuberculosis* have caused the loss of significant numbers of animals in laboratory colonies and zoos (Baskin, 1980). Epizootics have recently occurred in a wildlife park (Welsh et al., 1992) and in farmed herds of red deer (*Cervus elaphus*), elk (*C. elaphus canadensis*), fallow deer (*Dama dama*), and red deer-elk hybrids (Sanford, 1995). Wild birds and rodents are important reservoirs of *Y. pseudotuberculosis*, and ingestion of feed contaminated with feces and predation of carrier animals are potential methods of infection (Baskin, 1980). The lesions that develop vary with the species of animal infected (Baskin, 1980). In birds and some mammals, *Y. pseudotuberculosis* produces disseminated nodular foci of pyogranulomatous inflammation containing large numbers of organisms throughout the viscera, similar to the hepatic lesions in the gray fox of the present report.

Listeria monocytogenes is a Gram-positive bacillus that can cause septicemia, abortion, or encephalitis in humans and animals (Courtieu, 1991). *Listeria monocytogenes* is ubiquitous in nature (Dijkstra, 1981) and may be shed in the feces of infected animals and humans (Briones et al., 1992). Despite its widespread distribution, *L. monocytogenes* causes sporadic disease, and humans and animals are most commonly infected through ingestion of contaminated food (Courtieu, 1991). In a previous report, a gray fox with canine distemper and listeriosis had foci of hepatocellular necrosis containing numerous Gram-positive bacilli, and *L. monocytogenes* was cultured from the liver (Jakowski and Wyand, 1971). In contrast, Gram-positive bacilli in the liver of the gray fox in the present report were found in small numbers within viable-appearing Kupffer

cells and hepatocytes and were not identified within inflammatory foci. Thus, *Y. pseudotuberculosis* may have been the primary bacterial pathogen responsible for the foci of necrosis and inflammation in the liver of this fox.

The practice of using translocated wild canids such as gray foxes, red foxes (*Vulpes vulpes*), and coyotes (*Canis latrans*), from commercial sources to stock fox-chasing enclosures is increasing and is considered a potential health risk to indigenous wildlife, domestic animals, and humans; many gray foxes obtained during an investigation of illegal wildlife translocation were infected with canine distemper virus (Davidson et al., 1992b). The stress of capture, handling, and transport combined with the immunosuppressive effect of canine distemper virus may precipitate bacterial disease in foxes carrying *Y. pseudotuberculosis* (Obwolo, 1980) or *L. monocytogenes* (Gronstol, 1986). Concentrating the foxes in pens or enclosures facilitates the transmission of infectious diseases among them. Consequently, the potential for transmission of diseases such as listeriosis and yersiniosis to wild or domestic animals and to humans directly or indirectly exposed to translocated foxes, their carcasses, or feces may be significant.

This research is supported by the Mississippi Agricultural and Forestry Experiment Station (MAFES) under project #MISV-0842 and the College of Veterinary Medicine, Mississippi State University. This paper is MAFES publication #J-8800.

LITERATURE CITED

- AYROUD, M., D. HAINES, AND B. TERRANE. 1992. Canine distemper and secondary infections in unvaccinated ranch foxes. *Canadian Veterinary Journal* 33: 617.
- BASKIN, G. B. 1980. Comparative aspects of *Yersinia pseudotuberculosis* infection in animals. In *Comparative pathology of zoo animals*, R. J. Montali and G. Migaki (eds.). Smithsonian Institution Press, Washington, D.C., pp. 219–223.
- BILLE, J., AND M. P. DOYLE. 1991. Listeria and erysipelothrix. In *Manual of clinical microbiology*, 5th ed., A. Balows, W. J. Hausler, K. L. Herrmann, H. D. Isenberg and H. J. Shadomy (eds.). American Society for Microbiology, Washington, D.C., pp. 287–295.
- BRIONES, V., M. M. BLANCO, A. MARCO, N. PRATS, J. F. FERNÁNDEZ-GARAYZÁBAL, G. SUÁREZ, M. DOMINGO, AND L. DOMÍNGUEZ. 1992. Biliary excretion as possible origin of *Listeria monocytogenes* in fecal carriers. *American Journal of Veterinary Research* 53: 191–193.
- BUDD, J. 1981. Distemper. In *Infectious diseases of wild mammals*, 2nd ed., J. W. Davis, L. H. Karstad, and D. O. Trainer (eds.). The Iowa State University Press, Ames, Iowa, pp. 31–44.
- CHRISTIE, R., F. E. ATKINS, AND E. MUENCH-PEETERSEN. 1944. A note on the lytic phenomenon shown by group B streptococci. *Australian Journal of Experimental Biology and Medicine* 22: 197–200.
- COURTIEU, A. L. 1991. Latest news on listeriosis (review). *Comparative Immunology and Microbiology of Infectious Diseases* 14: 1–7.
- DAVIDSON, W. R., V. F. NETTLES, L. E. HAYES, E. W. HOWERTH, AND C. E. COUVILLION. 1992a. Diseases diagnosed in gray foxes (*Urocyon cinereoargenteus*) from the southeastern United States. *Journal of Wildlife Diseases* 28: 28–33.
- , M. J. APPEL, G. L. DOSTER, O. E. BAKER, AND J. F. BROWN. 1992b. Diseases and parasites of red foxes, gray foxes, and coyotes from commercial sources selling to fox-chasing enclosures. *Journal of Wildlife Diseases* 28: 581–589.
- DIJKSTRA, R. G. 1981. Listeriosis. In *Infectious diseases of wild mammals*, 2nd ed., J. W. Davis, L. H. Karstad, and D. O. Trainer (eds.). The Iowa State University Press, Ames, Iowa, pp. 306–316.
- DUNGWORTH, D. L. 1993. The respiratory system. In *Pathology of domestic animals*, 4th ed., Vol 2, K. V. F. Jubb, P. C. Kennedy, and N. Palmer (eds.). Academic Press, Orlando, Florida, pp. 539–699.
- GRONSTOL, H. 1986. Listeria. In *Pathogenesis of bacterial infections in animals*, C. L. Gyles and C. O. Thoen (eds.). Iowa State University Press, Ames, Iowa, pp. 48–55.
- HUBBERT, W. T. 1972. Yersiniosis in mammals and birds in the United States. *The American Journal of Tropical Medicine and Hygiene* 21: 458–463.
- JAKOWSKI, R. M., AND D. S. WYAND. 1971. Listeriosis associated with canine distemper in a gray fox. *Journal of the American Veterinary Medical Association* 159: 626–628.
- LUNA, L. G. *Manual of histologic and special staining techniques of the Armed Forces Institute of Pathology*, 2nd ed. McGraw-Hill Book Company, New York, New York, p. 222–223.
- OBWOLO, M. J. 1980. The pathogenesis of yersiniosis. In *Comparative pathology of zoo animals*, R. J. Montali and G. Migaki (eds.). Smithsonian Institution Press, Washington, D.C., pp. 225–229.
- SANFORD, E. S. 1995. Outbreaks of yersiniosis caused by *Yersinia pseudotuberculosis* in farmed

- cervids. *Journal of Veterinary Diagnostic Investigation* 7: 78–81.
- VELLECA, W. M., AND F. T. FORRESTER. 1981. Laboratory methods for detecting rabies, U.S. Department of Health and Human Services, Public Health Service, Centers for Disease Control, Atlanta, Georgia, pp. 69–87.
- WELSH, R. D., R. W. ELY, AND R. J. HOLLAND. 1992. Epizootic of *Yersinia pseudotuberculosis* in a wildlife park. *Journal of the American Veterinary Medical Association* 201: 142–144.
- WETZLER, T. F. 1981. Pseudotuberculosis. In *Infectious diseases of wild mammals*, 2nd ed., J. W. Davis, L. H. Karstad, and D. O. Trainer (eds.). The Iowa State University Press, Ames, Iowa, pp. 253–262.

Received for publication 12 July 1995.