

## **Synovial Chondromatosis in a Great Horned Owl (*Bubo virginianus*)**

Authors: M. O. Howard, M. A. Nieves, and K. G. Miles

Source: *Journal of Wildlife Diseases*, 32(2) : 370-372

Published By: Wildlife Disease Association

URL: <https://doi.org/10.7589/0090-3558-32.2.370>

---

BioOne Complete ([complete.BioOne.org](https://complete.BioOne.org)) is a full-text database of 200 subscribed and open-access titles in the biological, ecological, and environmental sciences published by nonprofit societies, associations, museums, institutions, and presses.

Your use of this PDF, the BioOne Complete website, and all posted and associated content indicates your acceptance of BioOne's Terms of Use, available at [www.bioone.org/terms-of-use](https://www.bioone.org/terms-of-use).

Usage of BioOne Complete content is strictly limited to personal, educational, and non-commercial use. Commercial inquiries or rights and permissions requests should be directed to the individual publisher as copyright holder.

---

BioOne sees sustainable scholarly publishing as an inherently collaborative enterprise connecting authors, nonprofit publishers, academic institutions, research libraries, and research funders in the common goal of maximizing access to critical research.

## Synovial Chondromatosis in a Great Horned Owl (*Bubo virginianus*)

M. O. Howard,<sup>1</sup> M. A. Nieves,<sup>2</sup> and K. G. Miles,<sup>2</sup> <sup>1</sup>Department of Veterinary Pathology, College of Veterinary Medicine, Iowa State University, Ames, Iowa 50011, USA; <sup>2</sup>Veterinary Clinical Sciences, College of Veterinary Medicine, Iowa State University, Ames, Iowa 50011, USA

**ABSTRACT:** A case of synovial chondromatosis in a great horned owl (*Bubo virginianus*) was found in June 1993. In radiographs of bilateral swelling of the scapulohumeral joint we observed numerous mineralized foci in the soft tissue. The foci were identified by light microscopy as cartilaginous metaplasia. This is the first report of synovial chondromatosis in an owl.

**Key words:** Synovial chondromatosis, synovial chondromas, raptor, great horned owl, *Bubo virginianus*.

Synovial chondromatosis is a condition in which the synovial lining of a bursa, tendon sheath, or joint has numerous metaplastic nodules of hyaline cartilage (synovial chondromas) (Pool, 1990). These nodules may undergo endochondral ossification and may detach into the synovial fluid and irritate the synovium (Palmer, 1993). The condition has been described in humans and domestic animals. This report is the first description of synovial chondromatosis in an adult great horned owl.

A mature female, great horned owl (*Bubo virginianus*) weighing 1.147 kg, was found in Story County, Iowa (USA) (41°53'N, 93°36'W), in June 1993 and brought to the Wildlife Care Clinic at Iowa State University College of Veterinary Medicine. The bird was emaciated, depressed, and dehydrated. Soft tissue swelling of the right shoulder was painful to palpation. Extension of both scapulohumeral joints was reduced. Forcible extension of the wings caused pain. The packed cell volume and total protein (Schuco clinical refractometer, Henry Schein, Inc., Port Washington, New York, USA) were 36% and 1.6 g/dl, respectively.

Radiography (Picker GX 1050 X-ray generator, Picker International, Wood Dale, Illinois, USA) of the shoulder joints was performed. Soft tissue swellings surrounded both scapulohumeral joints. Mul-

tiple mineralized foci with smooth, thin bony rims were present cranial to each scapulohumeral joint (Fig. 1). The adjacent proximal humerus and thoracic girdle were unaffected.

Exploration of the scapulohumeral joints for excisional biopsies was performed. Complete removal of the masses was not achieved and the bird was euthanized using Beuthanasia (Schering-Plough Animal Health Corp., Kenilworth, New Jersey) at 1 ml per 18 kg body weight, intravenously into the basilic vein.

Samples submitted for biopsy included portions of what appeared to be synovial lining and free and attached bony masses. The tissue was fixed in 10% neutral buffered formalin, embedded in paraffin, sectioned at 5 µm and stained with hematoxylin and eosin. The biopsy diagnosis was chronic proliferative plasmacytic synovitis and chondro-osseous metaplasia. Fluid aspirated from the pseudoarthrosis was diagnosed cytologically as chronic active inflammation of a joint, bursa or tendon sheath.

The most prominent lesion observed at necropsy was bilateral enlargement of the scapulohumeral area which involved the joints and adjacent soft tissue. A 30 × 30 × 30 mm sac filled with approximately 75 ml of yellow clear viscous fluid was present on the caudodorsal aspect of the right shoulder. A 5 × 5 × 3 mm firm, flesh colored mass was attached to the articular surface of the right humerus. The articular surfaces of the scapula and humerus otherwise were devoid of any lesions. The capsules of both scapulohumeral joints were thickened and the left contained numerous firm, discernible, intracapsular nodules.

Microscopically, the firm masses in the

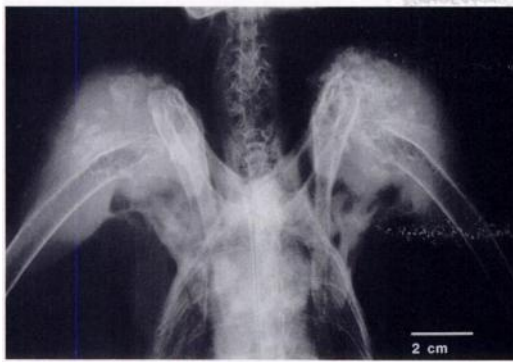

FIGURE 1. Radiograph of a ventrodorsal view of the great horned owl with lateral projection of the extended wings. Mineralized foci are distributed over an approximately 3 cm region near each shoulder and are more coalesced on the left side.

synovium of both shoulders were round, islands of cartilage surrounded by fibrous connective tissue (Fig. 2). The lacunae were haphazardly arranged and contained chondrocytes with dark pyknotic nuclei. Some lacunae were empty while others contained variable sized chondrocytes. A few chondrocytes were binucleated. Several foci contained spicules of well formed coarse woven bone lined by osteoblasts. Hematopoietic cells were evident in marrow spaces (Fig. 3). The periarticular sac had a similar morphologic appearance. In addition, papillary proliferation of the connective tissue formed fingerlike fronds into the cavity. A mild lymphoplasmacytic infiltrate was present in the synovium and in the wall of the periarticular cyst. Adjacent skeletal muscle was severely atrophic and regenerative myocytes were evident.

Synovial chondromatosis is characterized by the formation of multiple, benign cartilaginous nodules in the synovium. It is believed to be a reactive process of unknown origin (Fechner and Mills, 1992). When the majority of these nodules undergo bony transformation, the term osteochondromatosis is used. In humans, most cases involve the knee; however, there are separate reports involving the joints of the shoulder, carpal and tarsal bones, ankle, and mandible (Fechner and

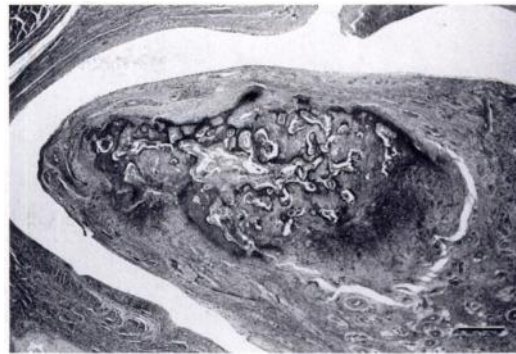

FIGURE 2. A cartilaginous nodule with osseous metaplasia located in the synovial membrane of the great horned owl's scapulohumeral joint. H&E. Bar = 200  $\mu\text{m}$ .

Mills, 1992). The condition maybe self-limiting and occasionally resolves spontaneously (Milgram, 1977).

Primary (idiopathic) and secondary (trauma, chronic irritation, inflammation) forms occur in nonhuman animals (Pool, 1990). The primary form is rare. Secondary synovial chondromatosis is usually an incidental finding at necropsy. It accompanies chronic secondary osteoarthritis of the major limb joints of older horses and dogs (Pool, 1990). The coexistence of these lesions is evidence that the cartilaginous metaplasia of the synoviocytes into chondrocytes may result from chronic irritation (Pool, 1990). An extra-articular form of the disease arising in a bursa can

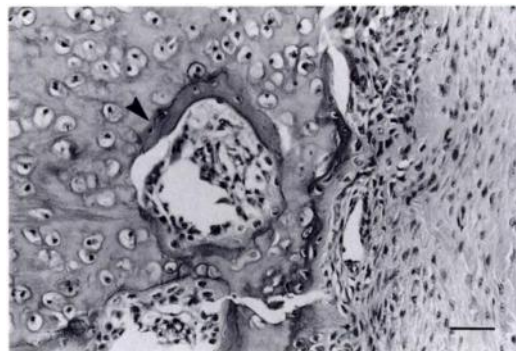


FIGURE 3. Osseous metaplasia (arrowhead) and marrow elements within a cartilaginous nodule of the great horned owl. H&E. Bar = 70  $\mu\text{m}$ .

occur, (Fechner and Mills, 1992; Pool, 1990) and in humans may coexist with intra-articular synovial chondromatosis (Fechner and Mills, 1992). Treatment of choice in both animals and humans is removal of any loose bodies within the joint and resection of affected synovium. This does not, however, alter the predisposing condition.

The cause of synovial chondromatosis in this case was undetermined. Fibrous connective thickening of the synovium and surrounding joint tissue and the presence of a lymphoplasmacytic infiltrate are strong evidence for a chronic inflammatory process. Perhaps the bird sustained an injury resulting from caudal overextension of the shoulder joints. We found no reports on occurrence of osteoarthritis or other joint diseases that might predispose raptors to synovial osteochondromatosis.

In humans, an important consideration in the differential diagnosis of this condition is synovial chondrosarcoma. Malignant transformation of synovial chondromatosis to chondrosarcoma is rare in humans (Smith, 1977). There is only one suspected case of malignant transformation in a domestic animal (Pool, 1990).

nant transformation of synovial chondromatosis to chondrosarcoma is rare in humans (Smith, 1977). There is only one suspected case of malignant transformation in a domestic animal (Pool, 1990).

#### LITERATURE CITED

- FECHNER, R. E., AND S. E. MILLS. 1992. Tumors of the bones and joints. *In* Atlas of tumor pathology, 3rd Series, Fascicle 8., J. Rosai and L. H. Sobin (eds.). Armed Forces Institute of Pathology, Washington, D.C., pp. 279-282.
- MILGRAM, J. W. 1977. Synovial osteochondromatosis. A histopathological study of thirty cases. *Journal of Bone and Joint Surgery [American Volume]* 59: 792-801.
- PALMER, N. 1993. Bones and joints. *In* Pathology of domestic animals, Vol. 1, 4th ed., K. V. F. Jubb, P. C. Kennedy and N. Palmer (eds.). Academic Press, Inc, San Diego, California, pp. 1-181.
- POOL, R. R. 1990. Tumors and tumor-like lesions of joints and adjacent soft tissues. *In* Tumors in domestic animals, 3rd ed., J. E. Moulton (ed.). University of California Press, Berkeley, California, pp. 102-156.
- SMITH, C. F. 1977. Synovial chondromatosis. *Orthopedic Clinics of North America* 10: 861-868.

*Received for publication 6 March 1995.*