

Cluster of Rabies Cases of Probable Bat Origin among Red Foxes in Prince Edward Island, Canada

Authors: Daoust, Pierre-Yves, Wandeler, Alexander I., and Casey, G. Allen

Source: Journal of Wildlife Diseases, 32(2) : 403-406

Published By: Wildlife Disease Association

URL: <https://doi.org/10.7589/0090-3558-32.2.403>

BioOne Complete (complete.BioOne.org) is a full-text database of 200 subscribed and open-access titles in the biological, ecological, and environmental sciences published by nonprofit societies, associations, museums, institutions, and presses.

Your use of this PDF, the BioOne Complete website, and all posted and associated content indicates your acceptance of BioOne's Terms of Use, available at www.bioone.org/terms-of-use.

Usage of BioOne Complete content is strictly limited to personal, educational, and non - commercial use. Commercial inquiries or rights and permissions requests should be directed to the individual publisher as copyright holder.

BioOne sees sustainable scholarly publishing as an inherently collaborative enterprise connecting authors, nonprofit publishers, academic institutions, research libraries, and research funders in the common goal of maximizing access to critical research.

Cluster of Rabies Cases of Probable Bat Origin among Red Foxes in Prince Edward Island, Canada

Pierre-Yves Daoust,¹ Alexander I. Wandeler,² G. Allen Casey,² ¹ Department of Pathology and Microbiology, Atlantic Veterinary College, University of Prince Edward Island, Charlottetown, Prince Edward Island, Canada C1A 4P3; ² Rabies Unit, Animal Diseases Research Institute, Agriculture Canada, P.O. Box 11300, Station H, Nepean, Ontario, Canada K2H 8P9

ABSTRACT: Between 15 November and 13 December 1993, three cases of rabies of probable bat origin were confirmed in red foxes (*Vulpes vulpes*) from the same area of Prince Edward Island, Canada, previously thought to be free of rabies in terrestrial mammals. Such clusters have rarely been described in North America.

Key words: Rabies, red fox, *Vulpes vulpes*, bat, case report.

Rabies is enzootic among some bat species throughout North America (Baer and Smith, 1991). Rabies of bat origin is diagnosed only occasionally in individual domestic and wild terrestrial mammals, and bat strains of rabies virus are not known to play an important role in terrestrial rabies enzootics (Smith and Baer, 1988). The reasons for this are not clear but may involve several factors, such as the amount and duration of virus excretion in the host's saliva, the degree of aggressive behavior caused by the disease, the length of the incubation period of the disease, and the population dynamics particular to the host species (Wandeler, 1991). These factors also may explain why, generally, a single species of terrestrial mammal acts as the main reservoir of rabies in different geographic areas. Individual cases of rabies of probable bat origin in domestic and wild terrestrial mammals were reported recently in eastern Canada (Webster et al., 1989). However, clusters of such cases have rarely been described in North America. We report a cluster of rabies of probable bat origin in red foxes (*Vulpes vulpes*) in the province of Prince Edward Island (PEI), Canada.

On 15 November 1993, a freshly dead red fox found in a backyard at the edge of the town of Summerside (46°22'N,

63°45'W), central PEI, was submitted for necropsy by a conservation officer of the PEI Fish & Wildlife Division to the Atlantic Veterinary College (AVC), University of Prince Edward Island, Charlottetown. This animal was a male of undetermined age in very poor body condition, as indicated by the complete absence of fat reserves. Its stomach was empty, but there was no gross lesion other than emaciation. Samples of brain, peripheral nerves, eye, heart, lung, liver, kidney, bladder, adrenal gland, skeletal muscle, and testicle were fixed in 10% formalin, dehydrated in graded alcohol, embedded in paraffin, sectioned at 5 µm, and stained with hematoxylin and eosin. Half of the brain was frozen at -20 C. Microscopically, the only significant lesion was a nonsuppurative encephalitis which included perivascular cuffing, diffuse and multifocal microgliosis, and the presence of acidophilic intracytoplasmic inclusion bodies compatible with Negri bodies within a few neurons. Rabies viral antigen was identified by the fluorescent antibody technique in the brain of this animal with the use of fluorescein-labelled anti-nucleoprotein antibodies prepared at the Animal Diseases Research Institute, Agriculture Canada (Nepean, Ontario, Canada) (Webster and Casey, 1988).

We attempted to identify the virus variant by determining the reaction patterns of viral antigen in brain smears with a panel of 15 anti-nucleoprotein monoclonal antibodies (MAbs), and of virus grown on murine neuroblastoma cells (line NA-C1300, originally supplied by Dr. T. J. Wiktor, Wistar Institute of Anatomy and Biology, Philadelphia, Pennsylvania, USA) with a panel of 99 anti-nucleoprotein, anti-

TABLE 1. Reaction patterns of selected anti-nucleoprotein monoclonal antibodies (MAb) with some rabies virus variants in northeastern North America.

MAb	Rabies virus variants						
	1 ^a	2	3	4	5	6	7
5DF12	+ ^b	+	+	+	+	+	+
16DA2	+	-	+	+	±	±	±
20CB11	+	+	-	+	+	+	+
24FF11	-	+	-	-	-	-	-
26BD6	+	+	+	+	-	-	-
26BH11	+	±	+	-	+	+	+
32FF1	+	+	-	+	+	+	+
38FG5	+	+	-	+	+	+	+
39BH4	+	+	+	+	+	+	+
7D2	-	±	+	+	±	±	±

^a 1, Ontario fox rabies virus variant; 2, mid-Atlantic raccoon rabies virus variant; 3, big brown bat (*Eptesicus fuscus*) type I variant (Ontario and Québec); 4, big brown bat type II variant (Ontario and Québec); 5, isolate from little brown bat (*Myotis lucifugus*), Atlantic province of Nova Scotia, 1994; 6, isolates from terrestrial mammals from Atlantic provinces (Webster et al., 1989); and 7, isolates from Prince Edward Island foxes.

^b +, MAb binding to rabies virus antigen; -, MAb not binding to rabies virus antigen; ±, reaction of MAb with rabies virus antigen very weak or variable.

phosphoprotein, and anti-glycoprotein MAbs, using criteria for rabies variant identification as described by Rupprecht et al. (1991). All MAbs used come from hybridoma cultures that were originally prepared by Goding's (1986) technique at the Swiss Rabies Centre (Institute of Veterinary Virology, University of Bern, Switzerland) or at the Animal Diseases Research Institute, Agriculture Canada. The reaction pattern of the isolated virus was clearly distinct from that of all rabies virus variants associated with bat rabies in the Canadian provinces of Québec and Ontario, and different from all characterized terrestrial mammal rabies viruses known to occur in Canada or in neighboring states in the United States (Table 1). Viruses that resemble the isolate from the PEI fox were recovered in previous years from two red foxes, one bovine and one little brown bat (*Myotis lucifugus*) originating in other Canadian Atlantic provinces (Table 1) (Webster et al., 1989). These Atlantic rabies isolates tentatively were rated as bat

rabies virus variants, mainly because of the lack of persistent enzootic rabies in terrestrial mammals in this region.

Because rabies had never been diagnosed in PEI between 1958 and 1993 (Animal Diseases Research Institute, Agriculture Canada, unpublished records), conservation officers from the provincial Fish and Wildlife Division were asked to submit any other red fox found dead or with a suspicious behavior to AVC for necropsy. Between 15 November 1993 and 7 February 1995, 26 additional red foxes collected in PEI within a radius of 100 km from Summerside were submitted. Of these 26 animals, 18 were submitted before 19 January 1994, including two that were collected within 1 km from the index case. Samples of brain, heart, lung, liver, kidney and skeletal muscle from all these animals were fixed in 10% formalin and prepared for microscopic examination as described previously. Most of these animals had died from trauma. However, the two additional animals collected from the same area as the index case had microscopic evidence of a nonsuppurative encephalitis which subsequently was confirmed as rabies by the use of fluorescein-labelled anti-nucleoprotein antibodies, as described previously. The isolates from these two animals also were grown on murine neuroblastoma cells. Based on a panel of 99 MAbs to rabies viral antigen, there were only minor differences in reaction pattern among these two isolates and that from the index case. One of these two animals was a female identified as an adult, based on the absence of growth plates in the distal ends of its radii and ulnae (Larson and Taber, 1980). It was collected on 6 December 1993 but, according to local residents, had been dead for approximately 4 wk. The other, an adult male, was found on 13 December 1993 but was estimated to have been dead for approximately 2 wk. A sample of one of the mandibular salivary glands from this animal was included with the other tissue samples for microscopic examination. Microscopi-

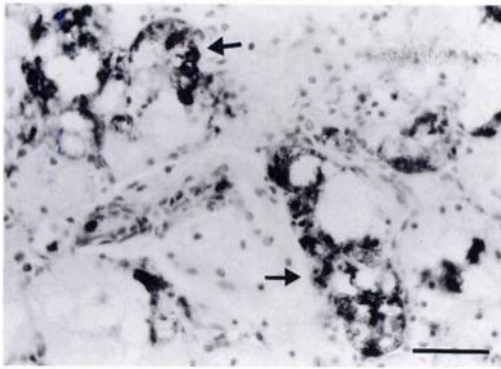


FIGURE 1. Immunoperoxidase staining of rabies antigen in clusters of acini (arrows) from a salivary gland of a red fox with rabies of probable bat origin. Bar = 40 μ m.

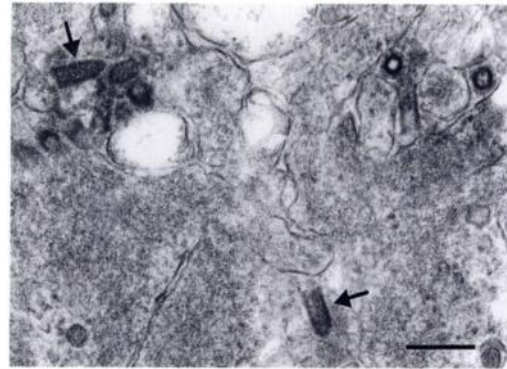


FIGURE 2. Electron micrograph of the apical portions of two acinar cells from the salivary gland of a red fox with rabies of probable bat origin. A few virions, some with the typical bullet shape of rhabdoviruses (arrows), are in the cytoplasm. Bar = 200 nm.

cally, the interstitium of this tissue contained multifocal aggregates of inflammatory cells which, however, could not be characterized further because of autolysis. Using an immunohistochemical test (avidin-biotin complex) with a polyclonal anti-rabies serum (Balachandran and Charlton, 1994), we observed an abundance of positively staining material within numerous acini and excretory ducts in this tissue (Fig. 1). A portion of formalin-fixed salivary gland was prepared for electron microscopic examination (Bozzola and Russell, 1992). Ultrastructurally, a small number of rhabdoviral particles could be found within this sample (Fig. 2).

The basis for this small cluster of bat rabies in red fox could not be determined, although two obvious scenarios must be considered, keeping in mind that probably only a fraction of the animals involved in the epizootic actually were found and submitted: either each animal independently had contact with rabid bats, or some degree of intraspecific transmission occurred. Only two species of bats are known from PEI: the little brown bat and the northern long-eared bat (*Myotis septentrionalis*) (Donald F. McAlpine, Curator of Zoology, New Brunswick Museum, Saint John, New Brunswick, Canada, pers. comm.). Winter roosts for bats are rare on PEI, and members of both species normally migrate out

of the province before the end of September.

Considering that the third rabid fox, submitted on 13 December 1993, may have died in late November, and assuming that it had acquired rabies directly from a bat shortly before the latter left PEI, the duration of the incubation period would have been approximately 9 wk, which, although long, is within the range documented for this disease (Blancou et al., 1991). However, it would seem necessary to invoke a local epizootic of rabies among bats in the Summerside area, in order for at least three red foxes to have been infected independently by bats within, at most, a few weeks of each other. Alternatively, the demonstration of rabies antigen and the presence, albeit in small numbers, of complete virions in the salivary glands of one of the three foxes in this report are evidence of the possibility of intraspecific transmission. The only other known cluster of rabies of bat origin in terrestrial mammals in North America involved two separate incidents in Dutchess County, New York (USA), one in late 1983 and the other in late 1987, each involving three cases of rabies in gray foxes (*Urocyon cinereoargenteus*) (Smith and Baer, 1988). Transient transmission of rabies of bat or-

igin among terrestrial mammals is a possibility that cannot be discounted.

ACKNOWLEDGMENTS

We thank the members of the Prince Edward Island Fish & Wildlife Division for their excellent cooperation, particularly Tim Lash, its acting director, Roland Richard, who submitted the three rabid foxes, and Randall Dibblee, who reviewed the manuscript. We also thank Jennifer Brown for her information on bats of Prince Edward Island, Dorota Wadowska for her excellent ultrastructural work, Janet Armstrong for growing the viral isolates on neuroblastoma cells and for the monoclonal antibody work, and Frances Muldoon for performing the immunohistochemical stainings.

LITERATURE CITED

- BAER, G. M., AND J. S. SMITH. 1991. Rabies in non-hematophagous bats. *In* The natural history of rabies, 2nd ed., G. M. Baer (ed.). CRC Press, Boca Raton, Florida, pp. 341–366.
- BALACHANDRAN, A., AND K. M. CHARLTON. 1994. Experimental rabies infection of non-nervous tissue in skunks (*Mephitis mephitis*) and foxes (*Vulpes vulpes*). *Veterinary Pathology* 31:93–102.
- BLANCOU, J., M. F. A. AUBERT, AND M. ARTOIS. 1991. Fox rabies. *In* The natural history of rabies, 2nd ed., G. M. Baer (ed.). CRC Press, Boca Raton, Florida, pp. 257–290.
- BOZZOLA, J. J., AND L. D. RUSSELL. 1992. Electron microscopy. Principles and techniques for biologists. Jones and Bartlett Publishers, Boston, Massachusetts, 542 pp.
- GODING, J. W. 1986. Monoclonal antibodies. Principles and practice, 2nd ed. Academic Press, London, England, 315 pp.
- LARSON, J. S., AND R. D. TABER. 1980. Criteria of sex and age. *In* Wildlife management techniques manual, 4th ed., S. D. Schemnitz (ed.). The Wildlife Society, Washington, D.C., pp. 143–202.
- RUPPRECHT, C. E., B. DIETZSCHOLD, W. H. WUNNER, AND H. KOPROWSKI. 1991. Antigenic relationships of lyssaviruses. *In* The natural history of rabies, 2nd ed., G. M. Baer (ed.). CRC Press, Boca Raton, Florida, pp. 69–100.
- SMITH, J. S., AND G. M. BAER. 1988. Epizootiology of rabies: The Americas. *In* Rabies. J. B. Campbell and K. M. Charlton (eds.). Kluwer Academic Publishers, Boston, Massachusetts, pp. 267–299.
- WANDELER, A. I. 1991. Carnivore rabies: Ecological and evolutionary aspects. *Hystrix* 3:121–135.
- WEBSTER, W. A., AND G. A. CASEY. 1988. Diagnosis of rabies infection. *In* Rabies. J. B. Campbell and K. M. Charlton (eds.). Kluwer Academic Publishers, Boston, Massachusetts, pp. 201–222.
- , ———, AND K. M. CHARLTON. 1989. Bat-induced rabies in terrestrial mammals in Nova Scotia and Newfoundland. *Canadian Veterinary Journal* 30:679.

Received for publication 7 April 1995.