



Herpesvirus Particles Associated With Oral and Respiratory Lesions in a California Desert Tortoise (*Gopherus agassizii*)

Authors: Pettan-Brewer, K. C. B., Drew, M. L., Ramsay, E., Mohr, F. C., and Lowenstine, L. J.

Source: Journal of Wildlife Diseases, 32(3) : 521-526

Published By: Wildlife Disease Association

URL: <https://doi.org/10.7589/0090-3558-32.3.521>

BioOne Complete (complete.BioOne.org) is a full-text database of 200 subscribed and open-access titles in the biological, ecological, and environmental sciences published by nonprofit societies, associations, museums, institutions, and presses.

Your use of this PDF, the BioOne Complete website, and all posted and associated content indicates your acceptance of BioOne's Terms of Use, available at www.bioone.org/terms-of-use.

Usage of BioOne Complete content is strictly limited to personal, educational, and non - commercial use. Commercial inquiries or rights and permissions requests should be directed to the individual publisher as copyright holder.

BioOne sees sustainable scholarly publishing as an inherently collaborative enterprise connecting authors, nonprofit publishers, academic institutions, research libraries, and research funders in the common goal of maximizing access to critical research.

Herpesvirus Particles Associated With Oral and Respiratory Lesions in a California Desert Tortoise (*Gopherus agassizii*)

K. C. B. PETTAN-BREWER,¹ M. L. DREW,^{2,4} E. RAMSAY,^{3,5} F. C. MOHR,¹ and L. J. LOWENSTINE,^{1,6,1}

Department of Veterinary Pathology, Microbiology and Immunology, School of Veterinary Medicine, University of California, Davis, California 95616, USA; ² California Department of Fish and Game, 1701 Nimbus Road, Rancho Cordova, California 95670, USA; ³ Department of Medicine, School of Veterinary Medicine, University of California, Davis, California 95616, USA; ⁴ Present address: Department of Zoo Medicine, College of Veterinary Medicine, Texas A&M University, College Station, Texas 77843-445, USA; ⁵ Present address: Department of Environmental Medicine, College of Veterinary Medicine, University of Tennessee, Knoxville, Tennessee 37910, USA; ⁶ Present Address: Department of Pathology, San Diego Zoo, P.O. Box 551, San Diego, California 92112, USA

ABSTRACT: A 60-year-old captive California desert tortoise (*Gopherus agassizii*) which died in August 1990 at the University of California, Davis, California (USA), during treatment for colonic impaction had marked caseous necrosis of the oral cavity, choana, trachea, and lungs. Numerous intranuclear inclusion bodies and a large number of syncytial giant cells were seen in the oral cavity and respiratory tract along with bacterial granulomas. *Pasteurella testudinis*, *Streptococcus veridans*, and coagulase-negative *Staphylococcus spp.* were cultured from the lesions. Using electron microscopy, herpesvirus particles were observed in intranuclear inclusions and cytoplasm. Viral stomatitis, tracheitis, and bronchopneumonia complicated by bacterial infection were diagnosed. Although respiratory disease is common in desert tortoises, this is believed to be the first report of association with a viral infection.

Key words: Herpesvirus infection, *Gopherus (Xerobates) agassizii*, desert tortoise, respiratory disease.

The desert tortoise (*Gopherus agassizii*) is considered the oldest, longest living land vertebrate in North America. It is indigenous to the southwestern United States (California, Nevada, Utah, Arizona) and northern Mexico (Sonora), and has an estimated life span of 62 to 120 yr or more (Schmidt and Inger, 1957). Desert tortoise populations north and west of the Colorado River in the southwest U.S. are listed as threatened by the U.S. Federal Government Fish and Wildlife Service. Respiratory diseases are recognized to be of major importance in captive husbandry of these reptiles (Fowler, 1980; Jacobson et al., 1991). Upper respiratory tract disease (URTD) is a very significant potentially

transmissible disease in free-ranging desert tortoise as well (Jacobson et al., 1991).

Herpesvirus have been characterized from many taxa including reptiles. In chelonians, herpesviruses have been described in association with skin, ocular, and respiratory lesions in captive green sea turtles (*Chelonia mydas*) (Rebell et al., 1975; Jacobson et al., 1986); generalized infection in a painted turtle (*Chrysemys picta*) (Cox et al., 1980) and in two Pacific pond turtles (*Clemmys marmorata*) (Frye et al., 1977); hepatitis in captured map turtles (*Graptemys spp.*) (Jacobson et al., 1982); oropharyngeal lesions in a desert tortoise (*Gopherus agassizii*) (Harper et al., 1982) and in Argentine tortoises (*Geochelone chilensis*) (Jacobson et al., 1985); stomatitis and enteritis in Hermann's (*Testudo hermanni*) and four-toed (*Testudo (Agrionemys) horsfieldii*) tortoises (Lange et al., 1989); and stomatitis and encephalitis in Mediterranean land tortoises (*Testudo hermanni* and *Testudo graeca*) (Muller et al., 1990).

Upper respiratory tract disease in desert tortoises has been associated with *Pasteurella testudinis* (Snipes and Biberstein, 1982, 1991), and with *Mycoplasma agassizii* (Jacobson et al., 1991; Schumacher et al., 1993; Brown et al., 1994). The possibility of an underlying viral agent causing respiratory disease in desert tortoises has been investigated but not yet confirmed (Jacobson et al., 1991).

A 60-year-old male California desert tortoise was presented to a veterinary clinic, in Morro Bay, California (35°21'N,

120°50'W) in July 1990 because of weight loss and anorexia. The animal had been a long-term captive and its owner had changed many times. The origin of the tortoise was unknown, but the present owner acquired the animal approximately 1 yr previously. The animal had entered hibernation in November 1989 and emerged in January 1990.

After treatment with antibiotics and vitamin injections for 1 mo, no clinical improvement was noted. On re-presentation to the veterinarian, severe stomatitis and colonic impaction were diagnosed by physical examination and radiographs, respectively.

The tortoise was referred to the Veterinary Medical Teaching Hospital (VMTH), University of California, Davis, California for evaluation. On presentation, the animal was emaciated, dehydrated, and lethargic. Based on a physical examination, it had a severe stomatitis and a palpably enlarged bowel in the right caudal coelomic cavity.

Blood was collected from the jugular vein and submitted to the Hematology and Clinical Chemistry Laboratories, VMTH for analysis. Total white and red blood cell counts were performed in a hemocytometer (Neubauer®, American Optical, Buffalo, New York, USA) using Natt & Herrick's buffer with 0.5 ml of 0.5% new methylene blue (Campbell, 1995). Clinical chemistries were performed using Daco's Analyzer (Coulter Diagnostics, Hialeah, Florida, USA). No significant abnormalities were noted on hematology or serum biochemistry. A culturette (Becton Dickinson Company, Cockeysville, Maryland, USA) was used to culture the oral cavity and was submitted to the Microbiology Laboratory, VMTH. The swab was streaked onto 5% bovine blood agar and incubated at 37 C (98 F) for 24 hr and 72 hr (Biberstein and Zee, 1990). Isolates from the oral cavity were identified by morphology, colony characteristics and biochemical reactions to be *Pasteurella testudinis* (Snipes and Biberstein, 1982)

and *Candida* spp. (Biberstein and Zee, 1990).

Initial treatment included 40 ml/kg lactated Ringer's solution intra-coelomically every 24 hr, 5 mg/kg trimethoprim sulfa (Tribrissan® 24%, Coopers Animal Health, Inc., Kansas City, Kansas, USA) intramuscularly every 24 hr for 2 days and then once every other day, 20 ml mineral oil orally every other day, an enema using 20 to 50 ml warm water every 12 to 24 hr, and 0.5 ml Nystatin (Mycostatin®, Squibb Co., Princeton, New Jersey, USA) orally every 24 hr.

A small amount of dry, firm fecal material was passed the first day post-admission. Based on radiographs, we diagnosed severe colonic dilatation and fecal impaction which had not changed during the month since the referral radiographs.

After 3 days of treatment, no clinical improvement was noted and the animal continued to be anorectic and passed no feces. An endoscope was introduced through the cloaca to visualize the obstruction, but attempts to facilitate passage of the obstruction were unsuccessful. The tortoise became progressively weaker over the next 4 days and died 7 days after admission.

At gross post mortem examination the major lesions included a white, plaque-like thickening of the oral mucosa, especially the tongue (Fig. 1); thickening of the tracheal mucosa and filling of the lumen by white caseous material that extended distally to involve principal bronchi and pulmonary parenchyma; and cecal and colonic impaction.

Specimens of lung, trachea, tongue, and a choanal swab were collected aseptically and evaluated for bacteriological and fungal flora as done for the oral cavity. *Pasteurella testudinis*, *Streptococcus veridans*, and coagulase-negative *Staphylococcus* spp. were cultured. *Pasteurella testudinis* was the predominant organism cultured from lung. It also was cultured from tongue, trachea and choana, and was accompanied by equal or greater numbers of *Streptococcus veridans* and coagulase-neg-

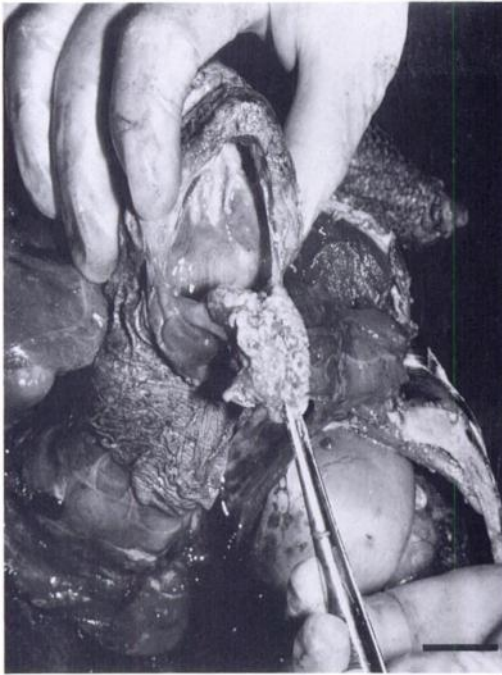


FIGURE 1. Desert tortoise oral cavity at post mortem examination. Note the thick white membrane covering the tongue and filling the choana. Bar = 1 cm.

ative *Staphylococcus* spp. Since only formalin-fixed tissues were saved, virus isolation was not attempted.

Representative samples of oral cavity, tongue, trachea, lungs, liver, heart, pancreas, kidneys, gastro-intestinal tract, thyroid gland, and gonads were fixed in buffered 10% formalin solution. Because this was a cosmetic examination, brain and nasal cavity could not be examined histologically. Following dehydration through graded alcohol and embedding in paraffin, 5 μ m sections were cut and stained with hematoxylin and eosin. The periodic acid Schiff (PAS), Grocott's methenamine silver (GMS), and Brown and Brenn (B&B) tissue Gram stains were performed on tongue, trachea, and lung for demonstration of microbiologic organisms (Luna, 1968).

In the tongue there was severe papillary epithelial hyperplasia, vesicle formation in stratum spinosum, necrosis and desqua-

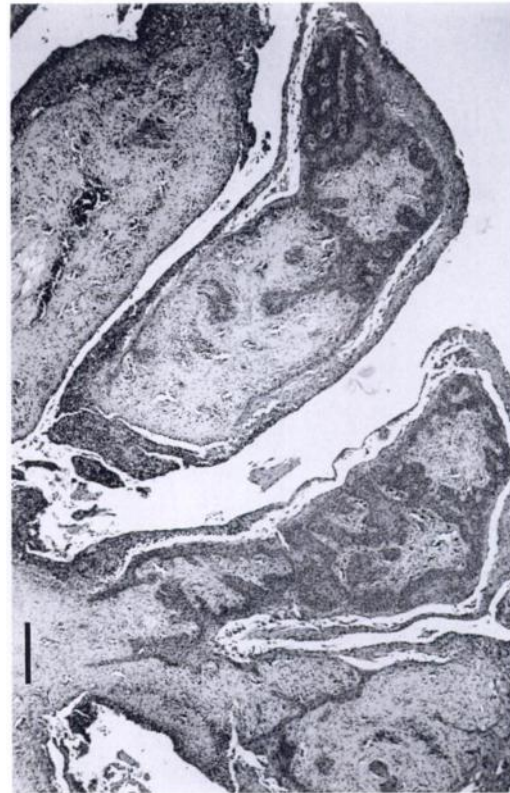

FIGURE 2. Papillary epithelial hyperplasia of the glossal mucosa with attached pseudomembrane of desquamate epithelium and inflammatory cells. Hematoxylin and eosin. Bar = 760 μ m.

mation of superficial layers of the epithelium with formation of a pseudomembrane composed of necrotic epithelium, granulocytes, red blood cells and bacterial colonies (Fig. 2). Many epithelial cells contained amphophilic intranuclear inclusion bodies and syncytial giant cells with eosinophilic nuclei and margined chromatin were seen.

The trachea was diffusely infiltrated by large numbers of granulocytes associated with extensive necrosis of epithelium and multiple areas of ulceration with exudation of fibrin and accumulation of necrotic cellular debris and granulocytes. Cells lining the principal airways often were hypertrophic and hyperplastic, with enlarged vacuolated nuclei. Many affected cells contained amphophilic intranuclear inclusion

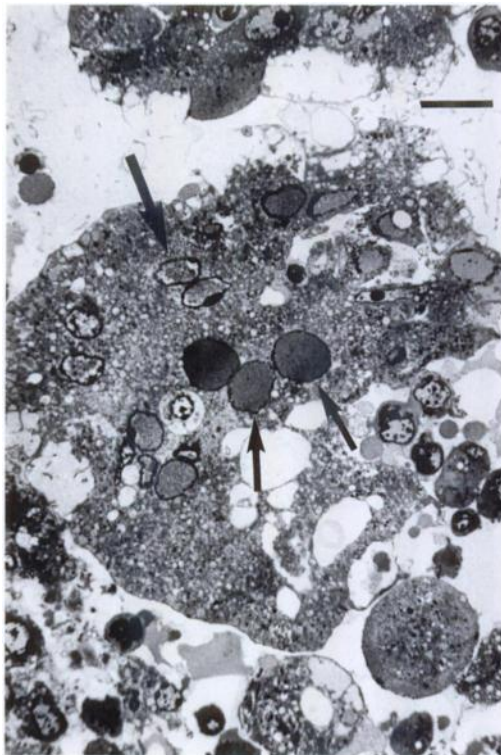


FIGURE 3. Toluidine blue-stained plastic embedded thick section of tortoise lung with a desquamated bronchiolar epithelial syncytial cell containing both amphophilic (small arrows) and Cowdry type A (large arrow) intranuclear inclusion bodies. Bar = 15 μ m.

bodies, margined nuclear chromatin and compressed nucleoli. Eosinophilic Cowdry type A inclusions also were seen. Syncytial cells also containing amphophilic and Cowdry type A intranuclear inclusion bodies were seen in the bronchial epithelium (Fig. 3). The airways were filled with sloughed epithelium, sometimes with intranuclear inclusions and syncytial cells, and necrotic debris. The pulmonary parenchyma contained multiple granulomas centered in airways consisting of multinucleated giant cells, epithelioid macrophages and a central zone of necrotic epithelial and inflammatory cell debris with scattered Gram-negative bacterial colonies. There was extensive exudation of fibrin and granulocytes into the remaining parenchymal septa and air spaces (faveoli).

Giant cells and intranuclear inclusions were present in airway epithelium and in the granuloma walls. No fungi were identified with either PAS or GMS stains.

For electron microscopic examination, sections of tongue, trachea and lung were fixed initially by immersion in 10% formalin. Tissues were post-fixed in 1% osmium tetroxide (PolySciences Inc., Warrington, Pennsylvania, USA), embedded in an Embedardite mixture (EMS, Fort Washington, Pennsylvania and Ted Pella Inc., Redding, California) sectioned at 1 μ m, stained with toluidine blue (J. T. Baker Chemical Co., Phillisburg, New Jersey) and examined with a light microscope. Ultrathin sections were placed on copper grids, stained with uranyl acetate and lead citrate (Mallinckrodt Chemical Works, Saint Louis, Missouri, USA) and examined with a Zeiss electron microscope (Zeiss 10A TEM, Oberkochen, Germany). Calculation of size of viral particles was by direct measurement from negatives of known magnification.

By electron microscopy, inclusions were found to contain viral particles with round to hexagonal profiles, averaging 110 nm diameter with electron-lucent or electron-dense cores (Fig. 4). Mature enveloped particles, averaging 147 nm in diameter were seen in the cytoplasm (Fig. 4. inset). The morphology, size of particles, and associated cytopathology were pathognomonic for herpesviruses infection.

Based on the histopathologic and electron microscope findings described in this report, we identified a herpesvirus associated with a respiratory disease in a desert tortoise. There is one previous report of herpesvirus in a captive desert tortoise (Harper et al., 1982) and none in free-ranging desert tortoises. The captive animal had pharyngitis, but no respiratory tract involvement. Herpesvirus-associated stomatitis, encephalitis and enteritis, but not pneumonia, have been described from other land tortoises (Harper et al., 1982; Jacobson et al., 1985; Lange et al., 1989; Müller et al., 1990). Jacobson et al. (1991)

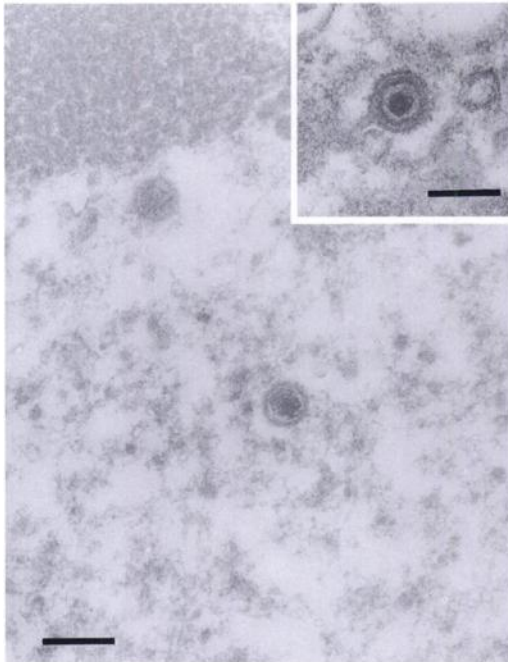


FIGURE 4. Transmission electron micrograph of intranuclear viral particles with average diameter of 110 nm and morphology compatible with a herpesvirus (Lead citrate and uranyl acetate). bar = 150 nm. Inset: Cytoplasmatic enveloped virions with an average diameter of 147 nm. Lead citrate and uranyl acetate; bar = 150 nm.

and Brown et al. (1994) failed to identify a virus in desert tortoises with URTD, despite detailed pathologic studies and viral isolation attempts. In the cases of URTD in desert tortoises reported by Jacobson et al. (1991), the cellular response was primarily proliferative, with diffuse infiltrates of plasma cells, heterophils and histiocytes. Severe necrosis was not a prominent feature. Lesions in the tortoise we report involved the oral cavity, trachea and lungs in contrast with Jacobson et al. (1991) where lesions were primarily confined to the nasal cavity. The viral inclusions in our case were unique and provided some evidence for viral participation in the pathogenesis of the oral and respiratory lesions. Further studies are needed to define the prevalence of herpesvirus infection in desert and other tortoises and its potential as a primary respiratory pathogen.

The authors gratefully acknowledge Dr. Avery W. Brewer and Ms. Vivianna Wong for their technical assistance with transmission electron microscopy and photomicrography.

LITERATURE CITED

- BIBERSTEIN, E. L., AND Y. C. ZEE. 1990. Review of veterinary microbiology. Blackwell Scientific Publications, Chicago, Illinois, 612 pp.
- BROWN, M. B., I. M. SHUMACHER, P. A. KLEIN, K. HARRIS, T. CORREL, AND E. R. JACOBSON. 1994. *Mycoplasma agassizii* causes upper respiratory tract disease in the desert tortoise. *Infection and Immunity* 62: 4580–4586.
- CAMPBELL, T. W. 1995. Avian hematology and cytology, 2nd ed. Iowa State University Press, Ames, Iowa, 104 pp.
- COX, W. R., W. A. RAPLEY, AND I. K. BARKER. 1980. Herpesvirus like infection in a painted turtle (*Chrysemys picta*). *Journal of Wildlife Diseases* 16: 445–449.
- FOWLER, M. E. 1980. Comparison of respiratory infection and hypovitaminosis A in desert tortoises. *In The comparative pathology of zoo animals*, R. J. Montali and G. Migaki (eds.). Smithsonian Institution Press, Washington, D.C., pp. 93–98.
- FRYE, F. L., L. S. OSHIRO, F. R. DUTRA, AND J. D. CARNEY. 1977. Herpesvirus-like infection in two Pacific pond turtles. *Journal of the American Veterinary Medical Association* 171: 882–884.
- HARPER, P. A. W., D. C. HAMMOND, AND W. HEUSCHELE. 1982. A herpesvirus-like agent associated with a pharyngeal abscess in a desert tortoise. *Journal of Wildlife Diseases* 18: 491–494.
- JACOBSON, E. R., J. M. GASKIN, AND H. WAHLQUIST. 1982. Herpesvirus-like infections in map turtles. *Journal of the American Veterinary Medical Association* 181: 1322–1324.
- , S. CLUBB, J. M. GASKIN, AND C. GARDINER. 1985. Herpesvirus-like infection in Argentine tortoises. *Journal of the Veterinarian Medical Association* 187: 1227–1229.
- , J. M. GASKIN, M. ROELKE, E. C. GREINER, AND J. ALLEN. 1986. Conjunctivitis, tracheitis, and pneumonia associated with herpesvirus infection in green sea turtles. *Journal of the American Veterinary Medical Association* 171: 1020–1023.
- , ———, M. B. BROWN, R. K. HARRIS, C. H. GARDINER, J. L. LAPOINTE, H. P. ADAMS, AND C. REGGIARDO. 1991. Chronic upper respiratory tract disease of free-ranging desert tortoises (*Xerobates agassizii*). *Journal of Wildlife Diseases* 27: 296–316.
- LANGE, H., W. HERBEST, J. M. WIECHERT, AND T. H. SCHLIEBER. 1989. Elektronenmikroskopischer Nachweis von Herpesviren bei einem Massen-

- sterben von griechischen Landschildkroten (*Testudo hermanni*) und Vierzehenschildkroten (*Agrionemys horsfieldi*). Schweizer Archiv für Tierheilkunde 17: 319–321.
- LUNA, L. G. 1968. Manual of histologic staining methods of the Armed Forces Institute of Pathology, 3rd ed. McGraw-Hill Book Company, New York, New York, 258 pp.
- MÜLLER, M., W. SACHSSE, AND N. ZANGGER. 1990. Herpesvirus-epidemie bei der griechischen (*Testudo hermanni*) und der maurischen Landschildkroten (*Testudo graeca*) in der Schweiz. Schweizer Archiv für Tierheilkunde 132: 199–203.
- REBELL, G., A. RYWLIN, AND H. HAINES. 1975. A herpesvirus-type agent associated with skin lesions of green sea turtles in aquaculture. American Journal of Veterinary Research 36: 1221–1224.
- SCHMIDT, K. P., AND R. F. INGER. 1957. Living reptiles of the world. Doubleday and Company Inc., Garden City, New York, 287 pp.
- SCHUMACHER, I. M., I. L. BROWN, E. R. JACOBSON, B. R. COLLINS, AND P. A. KLEIN. 1993. Detection of antibodies to a pathogenic mycoplasma in the desert tortoise. Journal of Clinical Microbiology 31: 1454–1460.
- SNIPES, K. P., AND E. L. BIBERSTEIN. 1982. *Pasteurella testudinis* sp. nov.: A parasite of desert tortoises (*Copherus agassizii*). International Journal of Systematic Bacteriology 32: 201–210.
- , AND ———. 1991. Observation on the occurrence of *Pasteurella testudinis* in clinical specimens from animals. Journal of Veterinary Diagnostic Investigation 3: 174–176.

Received for publication 2 February 1994.