

Isolation of a Poxvirus from a Black-tailed Deer (*Odocoileus hemionus columbianus*)

Authors: J. F. Patton, R. W. Nordhausen, L. W. Woods, and N. J. MacLachlan

Source: Journal of Wildlife Diseases, 32(3) : 531-533

Published By: Wildlife Disease Association

URL: <https://doi.org/10.7589/0090-3558-32.3.531>

BioOne Complete (complete.BioOne.org) is a full-text database of 200 subscribed and open-access titles in the biological, ecological, and environmental sciences published by nonprofit societies, associations, museums, institutions, and presses.

Your use of this PDF, the BioOne Complete website, and all posted and associated content indicates your acceptance of BioOne's Terms of Use, available at www.bioone.org/terms-o-use.

Usage of BioOne Complete content is strictly limited to personal, educational, and non - commercial use. Commercial inquiries or rights and permissions requests should be directed to the individual publisher as copyright holder.

BioOne sees sustainable scholarly publishing as an inherently collaborative enterprise connecting authors, nonprofit publishers, academic institutions, research libraries, and research funders in the common goal of maximizing access to critical research.

Isolation of a Poxvirus from a Black-tailed Deer (*Odocoileus hemionus columbianus*)

J. F. Patton,¹ R. W. Nordhausen,² L. W. Woods,² and N. J. MacLachlan,^{1,3} Department of Pathology, Microbiology and Immunology, School of Veterinary Medicine, University of California, Davis, California 95616, USA; ² California Veterinary Diagnostic Laboratory System, University of California, Davis, California 95616, USA; ³ Corresponding author

ABSTRACT: A poxvirus was isolated during the latter half of 1993 from a black-tailed deer (*Odocoileus hemionus columbianus*) that died of fulminant adenovirus infection in California (USA). The poxvirus was isolated from a pooled tissue homogenate, after repeated serial blind passages in primary black-tailed deer testicular cells. Based on electron microscopic examination of the virus, we observed morphologic features typical of the genus *Orthopoxvirus*, although definitive characterization was not done.

Key words: Poxvirus, black-tailed deer, *Odocoileus hemionus columbianus*.

An adenovirus recently was identified as the apparent causative agent of a fatal hemorrhagic disease of black-tailed deer (*Odocoileus hemionus columbianus*) and mule deer (*Odocoileus hemionus*) in the Sierra-Nevada mountains of California (USA) during the period between July and December, 1993, with sporadic cases occurring in 1994 (Woods et al., 1996). We describe the isolation of a poxvirus from one black-tailed deer fawn from Lake County, California (latitude 39°03'44"N, longitude 123°02'02"W) that died during the epizootic of hemorrhagic disease.

The fawn was observed staggering and salivating excessively prior to death. Lesions identified at necropsy included acute bronchopneumonia and ulceration of the esophagus with accompanying hemorrhagic or fibrinopurulent inflammation. Sections of brain, heart, lung, liver, kidney, spleen, adrenal gland, rumen, abomasum, large and small intestine, skeletal muscle, esophagus, trachea, lymph nodes, pharyngeal oral mucosa, pulmonary artery, skin and thymus were fixed in 10% neutral buffered formalin, embedded in paraffin, and sectioned prior to staining with hematoxylin and eosin. Histologic changes includ-

ed transmural inflammation of the esophagus with vasculitis of associated submucosal vessels, lymphoid necrosis in the spleen, focal necrotizing enteritis with lymphoid necrosis in Peyer patches, and diffuse interstitial pneumonia. Amphophilic intranuclear inclusions were present in the vascular endothelium of affected vessels in the esophagus, and adenovirus particles were demonstrated by electron microscopy (EM) in the lung.

Pooled fresh and frozen (–70 C) sections of lung, spleen, lymph node, and kidney were homogenized together in sterile phosphate buffered saline, centrifuged at 1,500 × G for 10 min, and the supernatant was inoculated onto Vero (African Green Monkey Kidney; American Type Culture Collection [ATCC], Rockville, Maryland, USA), baby hamster kidney (BHK-21; ATCC), bovine turbinate (courtesy of Dr. Mary Sawyer, University of California: Davis), rabbit kidney (RK-13; ATCC), white-tailed deer (*O. virginianus*) carotid artery (Howerth and Stallknecht, 1995) and primary black-tailed deer testicular cells, as described by Woods et al. (1996). Tissue homogenates were inoculated onto individual cell cultures and maintained at 37 C for a minimum of 10 days when they were frozen at –70 C. Up to seven blind passages were done on each inoculum. Cytopathic effect appeared on the seventh day of the sixth blind passage on the primary black-tailed deer testicle cells, and was manifest as focal accumulations of shrunken, highly refractile cells with granular cytoplasm.

Sections of cultured black-tailed deer testicular cells inoculated with the cytopathic agent were prepared for evaluation

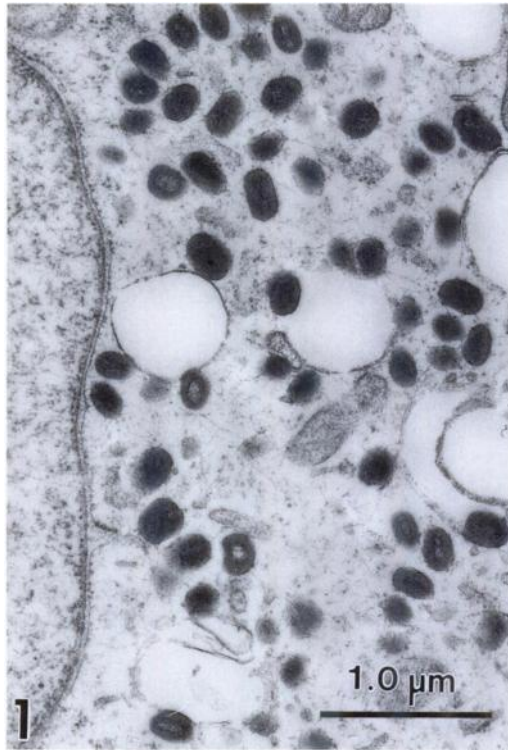


FIGURE 1. Thin section electron micrograph of a black-tailed deer testicular cell with numerous poxvirus particles distributed throughout the cytoplasm.

by thin-section electron microscopy (EM). Cells were scraped from tissue culture flasks, pelleted by centrifugation, and prepared as described by Woods et al. (1996). Numerous large virus particles were present in the cytoplasm (Fig. 1), often in association with discrete viral factories. Cell lysates were prepared for evaluation by negative contrast transmission EM. Cells were lysed with distilled water, and the lysates were stained with 2% phosphotungstate, as described by Spradbrow and Francis (1969). Many particles with morphologic features consistent with those of the genus *Orthopoxvirus* were present. Particles typically were brick-shaped, 160 to 200 by 270 to 300 nm, and most had the capsular (C) form morphology described by Doane and Anderson (1987). Based on thin section EM, we observed hour-glass-shaped core structures with a dense core

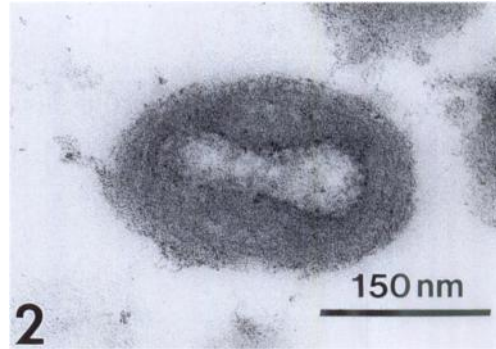


FIGURE 2. Thin section electron micrograph of a poxvirus particle from a black-tailed deer. Note the hour-glass like core structure.

membrane (Fig. 2). Some particles had surface ridges consistent with the mulberry (M) form of poxviruses (Doane and Anderson, 1987) (Fig. 3). Virus particles were not observed in lysates of the other cell cultures inoculated with tissues from the fawn or in lysates of uninoculated black-tailed deer testicular cells.

The pathogenic significance of the poxvirus isolated from the fawn is uncertain, since an adenovirus, related to bovine adenovirus 5, was consistently identified in tissues of deer that died during the epizootic of hemorrhagic disease (Woods et al., 1996). No epidermal lesions typical of poxvirus infection, similar to those described by Williams et al. (1985) in pox-

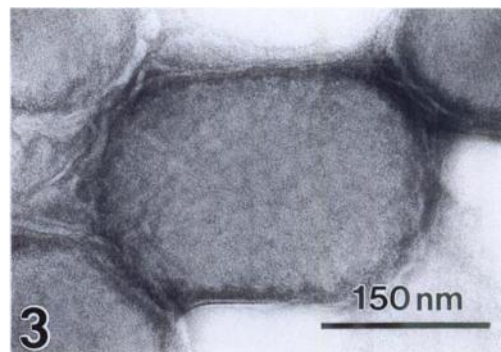


FIGURE 3. Negatively stained electron micrograph of a poxvirus particle from a black-tailed deer. Note the surface ridges consistent with the mulberry form of the virus.

virus-infected mule deer, were present in the tissues evaluated from the fawn.

Poxviruses may infect many different animal species (Nakano, 1977; Lane et al., 1981; Tripathy et al., 1981). There are at least six descriptions of poxvirus infection in cervids, including mule deer (Lance et al., 1983; Williams et al., 1985). The poxvirus described by Williams et al. (1985) had morphologic features similar to those of the virus we describe, although further studies would be required to firmly establish that both these viruses are orthopoxviruses. White-tailed deer and elk (*Cervus elaphus nelsoni*) are susceptible to experimental infection with contagious ecthyma virus (Lance et al., 1983), a parapox virus, as are moose (*Alces alces*) and caribou (*Rangifer tarandus*) (Zarnke et al., 1983). Adenoviruses typically cause only subclinical infections of mammals (Fenner et al., 1993), thus some other agent might predispose deer to fulminant adenovirus infection. It previously has been established that poxvirus infections may be immunosuppressive, because of production of immunomodulatory proteins that interfere with the antiviral activities of complement, interleukin-1 and tissue necrosis factor (Gooding, 1992), but it is unknown whether the poxvirus isolated from this fawn predisposed it to a subsequent fulminant adenovirus infection.

ACKNOWLEDGMENTS

The authors gratefully acknowledge Dr. E. Howerth, University of Georgia, for providing the white-tailed deer carotid artery cells, and Dr. P. Swift, California Department of Fish and Game, for providing normal black-tailed deer tissues.

LITERATURE CITED

- DOANE, F. W., AND N. ANDERSON. 1987. Electron microscopy in diagnostic virology. Cambridge

- University Press, Cambridge, United Kingdom, pp. 87-90.
- FENNER, F. J., E. P. J. GIBBS, F. A. MURPHY, R. ROTT, M. J. STUDDERT, AND D. O. WHITE. 1993. Veterinary virology, 2nd ed. Academic Press, Inc. San Diego, California, pp. 369-390.
- GOODING, L. R. 1992. Virus proteins that counteract host immune defenses. *Cell* 71: 5-7.
- HOWERTH, E. W., AND D. E. STALLKNECHT. 1995. Isolation and culture of large vessel endothelium from white-tailed deer. *Journal of Veterinary Diagnostic Investigation* 7: 137-142.
- LANCE, W. R., C. P. HIBLER, AND J. DEMARTINI. 1983. Experimental contagious ecthyma in mule deer. *Journal of Wildlife Diseases* 19: 165-169.
- LANE, J. M., J. H. STEELE, AND G. W. BERAN. 1981. Pox and parapox virus infections. In *Handbook series in zoonoses*, Vol. II, J. H. Steele (ed.). CRC Press, Inc. Boca Raton, Florida, pp. 365-385.
- NAKANO, J. H. 1977. Comparative diagnosis of poxvirus diseases. In *Comparative diagnosis of viral diseases*, Vol. I, Human and related viruses, Part A, E. Kurstak, and C. Kurstak, (eds.). Academic Press, New York, New York, pp. 287-330.
- SPRADBROW, P. B., AND J. FRANCIS. 1969. Electron microscopy as an aid to the rapid identification of animal viruses. *The Veterinary Record* 84: 244-246.
- TRIPATHY, D. N., L. E. HANSON, AND R. A. CRANDELL. 1981. Poxviruses of veterinary importance: Diagnosis of infections. In *Comparative diagnosis of viral diseases*, Vol. III, Vertebrate animal and related viruses, Part A, E. Kurstak, and C. Kurstak, (eds.). Academic Press, New York, New York, pp. 267-346.
- WILLIAMS, E. S., V. M. BECERRA, E. T. THORNE, T. J. GRAHAM, M. J. OWENS, AND C. E. NUNAMAKER. 1985. Spontaneous poxviral dermatitis and keratoconjunctivitis in free-ranging mule deer (*Odocoileus hemionus*) in Wyoming. *Journal of Wildlife Diseases* 21: 430-433.
- WOODS, L. W., P. K. SWIFT, B. C. BARR, M. C. HORIZNEK, R. W. NORDHAUSEN, M. H. STILLIAN, J. F. PATTON, M. N. OLIVER, K. R. JONES, AND N. J. MACLACHLAN. 1996. Systemic adenovirus infection as a cause of high mortality in mule deer (*Odocoileus hemionus*) in California. *Veterinary Pathology* 33: 125-132.
- ZARNKE, R. L., R. A. DIETRICH, K. A. NEILAND, AND G. RANGLACK. 1983. Serologic and experimental investigation of contagious ecthyma in Alaska. *Journal of Wildlife Diseases* 19: 170-174.

Received for publication 18 April 1995.