

Multicentric Malignant Lymphoma in a Pallid Bat

Authors: Andreasen, Claire B., and Duimstra, Julie R.

Source: Journal of Wildlife Diseases, 32(3) : 545-547

Published By: Wildlife Disease Association

URL: <https://doi.org/10.7589/0090-3558-32.3.545>

BioOne Complete (complete.BioOne.org) is a full-text database of 200 subscribed and open-access titles in the biological, ecological, and environmental sciences published by nonprofit societies, associations, museums, institutions, and presses.

Your use of this PDF, the BioOne Complete website, and all posted and associated content indicates your acceptance of BioOne's Terms of Use, available at www.bioone.org/terms-of-use.

Usage of BioOne Complete content is strictly limited to personal, educational, and non - commercial use. Commercial inquiries or rights and permissions requests should be directed to the individual publisher as copyright holder.

BioOne sees sustainable scholarly publishing as an inherently collaborative enterprise connecting authors, nonprofit publishers, academic institutions, research libraries, and research funders in the common goal of maximizing access to critical research.

Multicentric Malignant Lymphoma in a Pallid Bat

Claire B. Andreasen and Julle R. Dulmstra, Veterinary Diagnostic Laboratory, College of Veterinary Medicine, Oregon State University, Corvallis, Oregon 97331, USA

ABSTRACT: A 2.5-year-old, female pallid bat (*Antrozous pallidus*) was captured in Oregon (USA) in 1990 and later died in 1992. At the time of death, abdominal distension due to ascites, splenomegaly, and hepatomegaly, and a cheek mass were noted. Based on histologic examination of these tissues, a diagnosis of multicentric lymphoma was made. Retroviral particles were not found on electron microscopic examination.

Key words: Bat, lymphoma, *Antrozous pallidus*, neoplasia.

In August 1990, a 2.5-yr-old, female pallid bat (*Antrozous pallidus*) was captured in John Day, Grant County, Oregon, USA (44°30'N, 119°00'W) and later introduced into a pallid bat exhibit (High Desert Museum, Bend, Oregon) in July 1991. The bat's diet consisted of meal worms, crickets, bran, game bird chow, and a vitamin supplement. The bat remained active and healthy until August 1992 when a facial mass and abdominal distension were noted and, shortly thereafter, the bat was found dead. The referring veterinarian performed a necropsy and found a 14 mm diameter cheek mass, abdominal ascites, hepatomegaly, and splenomegaly.

At the time of necropsy, the liver, spleen, and cheek mass were fixed in 10% neutral buffered formalin and submitted for histologic examination to the Oregon State Veterinary Diagnostic Laboratory, Corvallis, Oregon. The tissues were embedded in paraffin, sectioned at 5 μ m, and stained with hematoxylin and eosin. After initial light microscopic examination of histologic sections, remaining sections of the facial mass and spleen were removed from formalin and prepared for transmission electron microscopy in a Lynx el Microscopy Tissue Processor (Leica, Inc., Deerfield, Illinois, USA). These tissues were rinsed in 0.2 M Sorenson's phosphate buffer, pH 7.2 (Dawson et al., 1986), post-fixed with 1.0% OsO₄ for one hour, rinsed in

double distilled water, and dehydrated through a graded acetone series: 10%, 30%, 50%, 70%, 80%, 95%, and three times in 100% for 10 min each. Tissues then were infiltrated with 3:1, 1:1, and 1:3 acetone:resin mixtures for 30 min each, placed in two 1 hr changes of pure resin (Medcast-Araldite 502, Ted Pella, Inc., Redding, California, USA) and an additional change of pure resin for 20 hr. Tissues were embedded in BEEM capsules (Ted Pella, Inc.) and polymerized at 60 C for 24 hr. Ultrathin sections (70 nm) of tissue were cut on a Sorvall MT 5000 ultramicrotome (E. I. du Pont de Nemours & Co., Inc., Claremont, California) with a diamond knife. Grids were stained with solutions of ethanolic uranyl acetate and bismuth subnitrate (Riva, 1974) and observed with a Zeiss EM 10/A transmission electron microscope (LEO, Thornwood, New York, USA) at an accelerating voltage of 60 kV.

Histologic sections of liver contained a multifocal to coalescing infiltrate of neoplastic lymphocytes. In some sections, lobules of neoplastic lymphocytes were more prominent in portal regions than around central veins. The splenic architecture was effaced by the same lymphocyte population. The facial mass was encapsulated by fibrous connective tissue and neoplastic lymphocytes formed cords with intervening sinus spaces that resembled the medullary region of a lymph node (Fig. 1). The neoplastic lymphocytes were somewhat heterogeneous. Many lymphocytes contained clumped, coarse chromatin, which tended to marginate in the nucleus. The nuclei were round or oval and 3.5 to 5 μ m in diameter with indistinct nucleoli. The remaining lymphocytes had round, oval, and occasionally irregular or cleaved nuclei ranging from 4 to 7 μ m in diameter. The

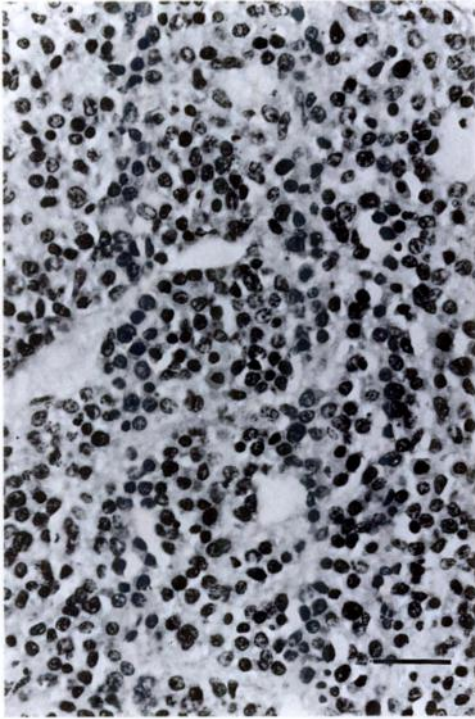


FIGURE 1. Neoplastic lymphocytes within the facial mass of the bat. The pattern of lymphocyte infiltration suggests this was the medullary area of a lymph node. H&E. Bar = 35 μ m.

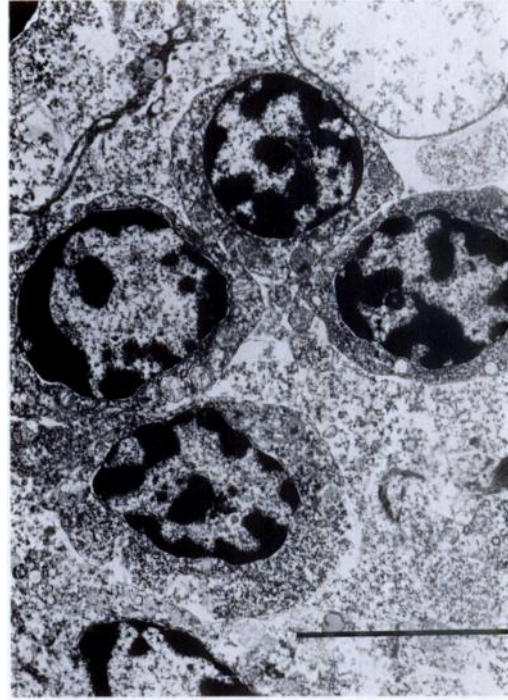


FIGURE 2. Electron micrograph of lymphocytes within the facial mass of the bat. The lymphocytes often contained margined chromatin along the nuclear membrane. Bar = 5 μ m.

nuclei in these larger lymphocytes were more vesicular with a finer, dispersed chromatin pattern. Nucleoli usually were indistinct but were noted in this population of lymphocytes. The lymphocytes often had indistinct cytoplasmic margins which formed coalescing sheets of cells. The mitotic prevalence was one per one to two 45 \times objective fields.

No retroviral particles were seen budding from lymphocytes on electron microscopic examination of multiple thin sections. Lymphocyte nuclei varied in size and shape as described in histologic sections. The nuclear chromatin was coarsely granular and generally margined in clumps along the nuclear membrane (Fig. 2). The cytoplasm contained ribosomes, mitochondria, scattered Golgi complexes, and endoplasmic reticulum but formalin

fixation precluded critical evaluation of cytoplasmic organelles.

We found no published reports of neoplasms in bats. In a survey of bats in the Southeastern United States (Southeastern Cooperative Wildlife Disease Study, College of Veterinary Medicine, University of Georgia, Athens, Georgia, USA), no tumors were found in complete necropsies of 94 bats (E. W. Howerth, pers. comm.). The lymphocytes in this bat were small to medium-size with a predominance of a mature (clumped) nuclear chromatin pattern. Interspersed larger lymphoblastic cells were present. In this case, the examination of only a small lymph node biopsy might be misleading due to the somewhat mixed, mature lymphocyte population; therefore, the lymph node architecture would be necessary to differentiate this lesion from lymphoid hyperplasia.

With only one case, it is unknown if this is representative of lymphoma in bats.

C-type retroviral particles have been associated with lymphosarcoma in pigs (Moulton and Harvey, 1990), gibbons (*Hyllobates lar*), birds, mice, cats (Snyder et al., 1973; Slauson and Cooper, 1990), possibly dogs (Sykes et al., 1985), and cattle (Valli, 1993). The inability to document retroviral particles with electron microscopic examination does not completely exclude the possibility of a viral etiology. As of the winter of 1995, no other neoplasms have occurred in bats housed in the exhibit.

We thank Dr. Neal Hovick and Ms. Mary Jo Roberts for the case submission and additional history, and Ms. Kay A. Fischer for technical assistance.

LITERATURE CITED

- DAWSON, R. M. C., D. C. ELLIOTT, W. H. ELLIOTT, AND K. M. JONES. 1986. Data for biochemical research, 2nd ed., Clarendon Press, Oxford, England, p. 432.
- MOULTON, J. E., AND J. W. HARVEY. 1990. Tumors of the lymphoid and hematopoietic tissues. *In* Tumors in domestic animals, 3rd ed., J. E. Moulton (ed.). University of California Press, Los Angeles, California, pp. 236–258.
- RIVA, A. 1974. A simple and rapid staining method for enhancing the contrast of tissues previously treated with uranyl acetate. *Journal de Microscopie (Paris)* 19: 105.
- SLAUSON, D. O., AND B. J. COOPER. (EDS.). 1990. Disorders of cell growth. *In* Mechanisms of disease, a textbook of comparative general pathology, 2nd ed. Williams and Wilkins, Baltimore, Maryland, pp. 431–438.
- SNYDER, S. P., D. L. DUNCWORTH, T. G. KAWAKAMI, E. CALLAWAY, AND D. T-L. LAU. 1973. Lymphosarcoma in two gibbons (*Hyllobates lar*) with associated C-type virus. *Journal of the National Cancer Institute* 51: 89–94.
- SYKES, G. P., J. M. KING, AND B. C. COOPER. 1985. Retrovirus-like particles associated with myeloproliferative disease in the dog. *Journal of Comparative Pathology* 95: 559–564.
- VALLI, V. E. O. 1993. The hematopoietic system. *In* Pathology of domestic animals, 4th ed. Academic Press, Inc., San Diego, California, pp. 138–156.

Received for publication 31 October 1995.