

Filarial Dermatitis in a Striped Skunk

Authors: Saito, Emi K., and Little, Susan E.

Source: Journal of Wildlife Diseases, 33(4) : 873-876

Published By: Wildlife Disease Association

URL: <https://doi.org/10.7589/0090-3558-33.4.873>

BioOne Complete (complete.BioOne.org) is a full-text database of 200 subscribed and open-access titles in the biological, ecological, and environmental sciences published by nonprofit societies, associations, museums, institutions, and presses.

Your use of this PDF, the BioOne Complete website, and all posted and associated content indicates your acceptance of BioOne's Terms of Use, available at www.bioone.org/terms-of-use.

Usage of BioOne Complete content is strictly limited to personal, educational, and non - commercial use. Commercial inquiries or rights and permissions requests should be directed to the individual publisher as copyright holder.

BioOne sees sustainable scholarly publishing as an inherently collaborative enterprise connecting authors, nonprofit publishers, academic institutions, research libraries, and research funders in the common goal of maximizing access to critical research.

Filarial Dermatitis in a Striped Skunk

Emi K. Saito^{1,2} and Susan E. Little,^{1,3} Southeastern Cooperative Wildlife Disease Study, College of Veterinary Medicine, The University of Georgia, Athens, Georgia 30602, USA; ²School of Veterinary Medicine, The University of Pennsylvania, 3800 Spruce Street, Philadelphia, Pennsylvania 19104, USA; ³Department of Parasitology, College of Veterinary Medicine, The University of Georgia, Athens, Georgia 30602, USA

ABSTRACT: A striped skunk (*Mephitis mephitis*) from Kansas (USA) with severe diffuse dermatitis characterized by extensive alopecic areas, thickened skin, and multiple, scattered cutaneous abscesses on the dorsal aspect of the head, neck, and trunk was submitted for diagnostic evaluation. More than 50 nematodes identified as *Filaria taxideae* were found in the dorsal subcutaneous tissue. Histologic examination of the skin revealed multifocal pyogranulomatous inflammation with intralesional larvated nematode eggs, moderate orthokeratotic hyperkeratosis, and mild acanthosis. The lesions resemble those reported from badgers (*Taxidea taxus*) and a lesser panda (*Ailurus fulgens*) with dermatitis caused by *Filaria taxideae*. Although *F. taxideae* has been previously collected from skunks, this is the first report of filarial dermatitis caused by this nematode in a striped skunk.

Key words: Dermatitis, *Filaria taxideae*, *Mephitis mephitis*, striped skunk.

Dermatitis caused by the nematode *Filaria taxideae* has been described in free-ranging badgers (*Taxidea taxus*) (Keppner, 1971; O'Toole et al., 1993) and in a lesser panda (*Ailurus fulgens*) (Gardiner et al., 1983). Adult *F. taxideae* live in the subcutaneous tissues of the host, usually without evoking a significant inflammatory response. The life cycle of *F. taxideae* is not completely known. Female *F. taxideae* deposit eggs that contain larvae into the dermis of the host. The eggs induce inflammation resulting in ulceration of the epidermis and subsequent release of eggs and larvae onto the skin surface. It is thought that a dipteran intermediate host acquires the parasite while feeding on an infected mammalian definitive host.

Filaria taxideae has been identified from specimens collected from striped skunks (*Mephitis mephitis*) that were originally designated *F. martis* (see Keppner, 1969). However, disease due to *F. taxideae* has not been reported in skunks. This pa-

per describes the lesions of severe dermatitis in a skunk with *F. taxideae*.

On 7 March 1996, an adult male striped skunk was captured in Topeka, Kansas (USA; 39°02'N, 95°41'W). Because of alopecia on its head and back, the animal was killed and submitted to the Kansas Department of Wildlife and Parks (Topeka). The carcass was frozen and submitted to the Southeastern Cooperative Wildlife Disease Study (College of Veterinary Medicine, The University of Georgia, Athens, Georgia, USA) for necropsy. External examination revealed large multifocal to confluent areas of alopecia that were most prominent on the dorsal aspect of the head, the thoracolumbar region, and the base of the tail (Fig. 1). Affected areas of skin were severely thickened. The epidermis was roughened and had multifocal 5 to 10 mm crusts with associated hemorrhage. Cutaneous abscesses also were present. Numerous nematodes were found coiled in the subcutaneous tissues. The nematodes were diffusely distributed in the subcutaneous tissue, but were found primarily on the dorsal aspect of the body. Locations of nematodes did not appear to correspond directly with the areas of gross cutaneous lesions. Occasional areas of calcification were present in the subcutaneous tissue. Except for the skin lesions, the skunk was normal on gross examination.

The subcutaneous nematodes were removed and placed in nematode fixative solution (3% formalin, 5% glycerol, 64.4% ethanol, 27.6% distilled water). The nematodes were identified as *Filaria taxideae* based on the description of Keppner (1969). Representative specimens were deposited in the U.S. National Parasite Collection (Beltsville, Maryland, USA; Assession number 86680). Sections of skin,

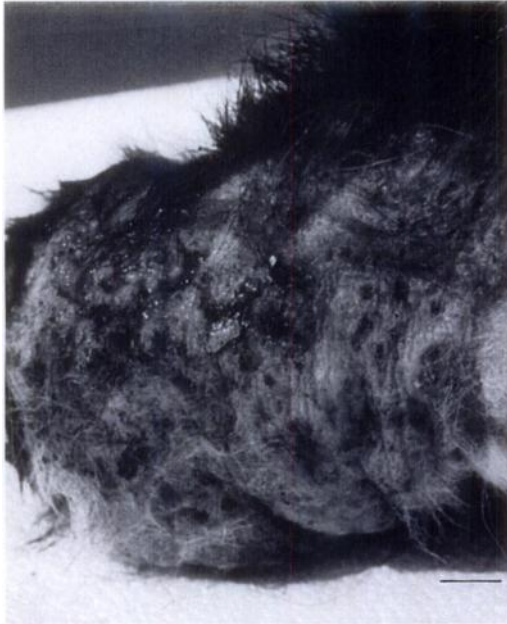

FIGURE 1. Photograph of alopecic area of skin on the dorsal aspect of the head of a striped skunk infected with *Filaria taxideae* showing the multifocal hemorrhagic crusts resulting from filarial dermatitis. Bar = 1.4 cm.

heart, lung, liver, spleen, kidney, stomach, intestine, pancreas, and brain were fixed in neutral buffered 10% formalin, embedded in paraffin, sectioned at 5 μ m, and stained with hematoxylin and eosin (H&E) for histologic examination. Aseptically collected swabs of cutaneous abscesses were submitted to the Athens Diagnostic Laboratory (Athens, Georgia, USA) for aerobic bacterial culture according to standard bacteriologic techniques (Ikram and Hill, 1991). Briefly, swabs were streaked onto 5% sheep blood agar plates directly and after overnight enrichment in thioglycolate broth at 37 C. Inoculated plates were incubated at 37 C, and bacterial colonies identified visually and via testing with an o-nitrophenyl- β -d-galactopyranoside disc (Becton Dickinson & Co., Rutherford, New Jersey, USA). Sections of the cerebrum including hippocampus were submitted to the same laboratory for fluorescent antibody testing for rabies virus (Veleca and Forrester, 1981).

Histologic examination of the skin revealed a hyperplastic epidermis with moderate orthokeratotic hyperkeratosis. Numerous intracorneal, intraepidermal, and dermoepidermal pustules containing granulocytes, mononuclear cells, erythrocytes, and larvated nematode eggs were seen (Fig. 2). In some areas, larvated eggs and inflammatory cells could be seen adhering to an ulcerated epidermis. Occasional linear arrays of eggs were found within a thickened dermis (Fig. 3); scattered mononuclear cells also were noted. Histologic lesions were not apparent in other tissues examined. *Staphylococcus intermedius* was isolated on culture, and *Bacillus* sp. was identified on subculture. The brain sections were negative for rabies.

The lesions seen in this skunk were similar to those described from free-ranging badgers and a lesser panda with *F. taxideae* in that affected animals had alopecia, thickened skin, and pyogranulomatous inflammation associated with the presence of larvated eggs (Keppner, 1971; O'Toole et al., 1993; Gardiner et al., 1983). The lesions in the lesser panda had a primarily dorsal distribution (Gardiner et al., 1983), as was seen in this case; however, *F. taxideae* lesions of badgers are found on the ventral aspect of the animal (O'Toole et al., 1993). Furthermore, while locations of the adult nematodes in badgers and the lesser panda directly corresponded to the cutaneous lesions in these animals (Keppner, 1971; Gardiner et al., 1983; O'Toole et al., 1993), such correspondence was not recognized in this skunk despite the extensive skin lesions.

A high prevalence of infection by *F. taxideae* has been found in free-ranging populations of badgers in Wyoming. O'Toole et al. (1993) report *F. taxideae* infection in 80% of the badgers they examined, with 51% of those animals showing associated dermatitis. In addition, 78% of raccoons (*Procyon lotor*) collected in Texas were found to be infected by *F. taxideae*, but no lesions were associated with these infections (Schaffer et al., 1981).

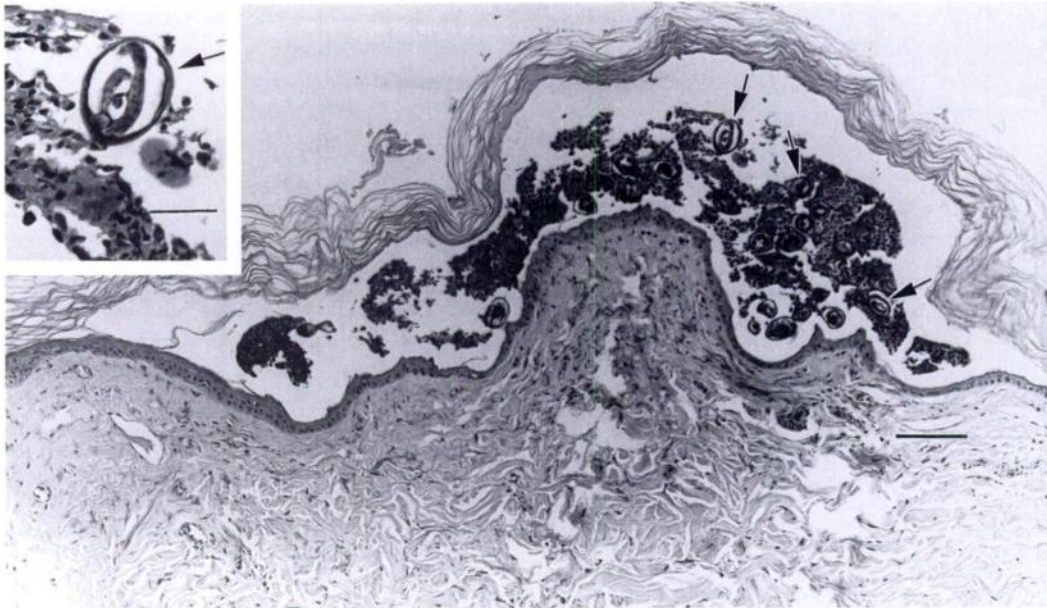


FIGURE 2. Photomicrograph of intracorneal cutaneous pustule containing inflammatory cells, erythrocytes, and larvated eggs (arrows) in a striped skunk with filarial dermatitis. Bar = 79 μm . Inset: distinct larvated nematode egg of *Filaria taxideae* at higher magnification. Bar = 26 μm .

Filaria taxideae has been reported to produce disease in three hosts, but other hosts may be susceptible to infection and development of subsequent dermatitis. Like the badgers, this skunk was in good physical condition; therefore, it is unlikely

that *F. taxideae* infection alone has a significant adverse clinical effect. The adult filarids are minimally invasive within the connective tissue of the subcutaneous region and elicit little inflammation. However, the severe pyoderma that results from the deposition of ova within the dermis of the infected host could potentially lead to sepsis.

The authors thank W. Davidson for assistance with the manuscript and identification of the helminths, and L. Fox for submitting the clinical case. This work was supported through sponsorship from the fish and wildlife agencies of Alabama, Arkansas, Florida, Georgia, Kentucky, Louisiana, Maryland, Mississippi, Missouri, North Carolina, Puerto Rico, South Carolina, Tennessee, Virginia, and West Virginia. Funds were provided by the Federal Aid to Wildlife Restoration Act (50 Stat. 917) and through Grant Agreement 14-45-0009-94-906, National Biological Service, U.S. Department of the Interior.

LITERATURE CITED

GARDINER, C. H., M. R. LOOMIS, J. O. BRITT, JR., AND R. J. MONTALL. 1983. Dermatitis caused by

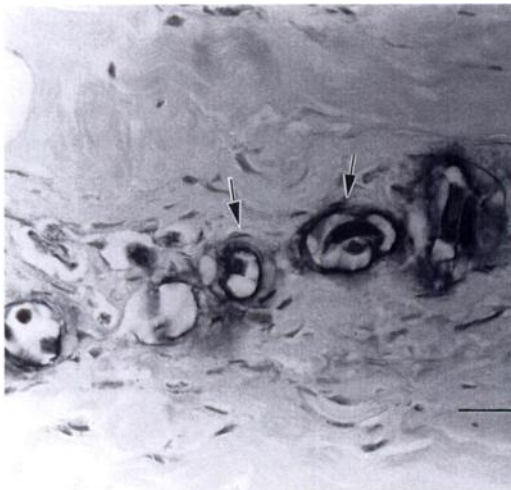


FIGURE 3. Photomicrograph of linear array of nematode eggs (arrows) within the thickened dermis of a striped skunk with filarial dermatitis. Bar = 21 μm .

- Filaria taxideae* in a lesser panda. Journal of the American Veterinary Medical Association 183: 1285-1287.
- IKRAM, M., AND E. HILL. 1991. Microbiology for veterinary technicians. American Veterinary Publications, Inc., Goleta, California, 213 pp.
- KEPPNER, E. J. 1969. *Filaria taxideae* n. sp. (Filarioidea: Filariidae) from the badger, *Taxidea taxus* from Wyoming. Transactions of the Microscopical Society 88: 581-588.
- KEPPNER, E. J. 1971. The pathology of *Filaria taxideae* (Filarioidea: Filariidae) infection in the badger. Journal of Wildlife Diseases 7: 317-323.
- O'TOOLE, D., E. S. WILLIAMS, V. WELCH, C. E. NUNAMAKER, AND C. LYNN. 1993. Subepidermal vesiculobullous filarial dermatitis in free-ranging American badgers (*Taxidea taxus*). Veterinary Pathology 30: 343-351.
- SCHAFFER, G. D., W. R. DAVIDSON, V. F. NETTLES, AND E. A. ROLLOR, III. 1981. Helminth parasites of translocated raccoons (*Procyon lotor*) in the southeastern United States. Journal of Wildlife Diseases 17: 217-227.
- VELLECA, W. M. AND F. T. FORRESTER. 1981. Laboratory methods for detecting rabies. United States Department of Health and Human Services, Public Health Service, Centers for Disease Control, Atlanta, Georgia, 159 pp.

Received for publication 18 February 1997.