

Capillariasis in the Trachea of a Raccoon

Authors: A. N. Hamir, C. Hanlon, and C. E. Rupprecht

Source: Journal of Wildlife Diseases, 33(4) : 880-881

Published By: Wildlife Disease Association

URL: <https://doi.org/10.7589/0090-3558-33.4.880>

BioOne Complete (complete.BioOne.org) is a full-text database of 200 subscribed and open-access titles in the biological, ecological, and environmental sciences published by nonprofit societies, associations, museums, institutions, and presses.

Your use of this PDF, the BioOne Complete website, and all posted and associated content indicates your acceptance of BioOne's Terms of Use, available at www.bioone.org/terms-o-use.

Usage of BioOne Complete content is strictly limited to personal, educational, and non - commercial use. Commercial inquiries or rights and permissions requests should be directed to the individual publisher as copyright holder.

BioOne sees sustainable scholarly publishing as an inherently collaborative enterprise connecting authors, nonprofit publishers, academic institutions, research libraries, and research funders in the common goal of maximizing access to critical research.

Capillariasis in the Trachea of a Raccoon

A. N. Hamir,^{1,3} C. Hanlon,^{2,4} and C. E. Rupprecht,^{2,4} ¹Department of Pathobiology, School of Veterinary Medicine, University of Pennsylvania, New Bolton Center, Kennett Square, Pennsylvania 19348, USA; ²Department of Microbiology and Immunology, Center for Neurovirology, Thomas Jefferson University, Philadelphia, Pennsylvania 19107, USA; Present addresses: ³College of Veterinary Medicine, Oregon State University, Magruder Hall, Corvallis, Oregon 97331, USA; ⁴Centers for Disease Control and Prevention, 1600 Clifton Road, Atlanta, Georgia 30333, USA

ABSTRACT: Cross-sections of nematodes were seen in histologic sections of trachea from a raccoon (*Procyon lotor*) collected in Virginia (USA); they occupied epithelium and contained unembryonated, bioperculated eggs characteristic of the genus *Capillaria* (= *Eucoleus*). A mild inflammatory cell infiltrate in the lamina propria subjacent to the nematode was the only apparent host response. This is the first report of capillariasis in the trachea of raccoons.

Key words: *Capillaria* sp., case report, raccoon, *Procyon lotor*, tracheal epithelium.

Over 300 species of the genus *Capillaria* (Trichuridae; Capillarinae) are known to parasitize a wide range of vertebrate hosts (Anderson, 1992). *Capillaria* (= *Eucoleus*) spp. produce distinct unembryonated bioperculated, barrel-shaped eggs which are easy to recognize in histopathologic tissue sections. In raccoons (*Procyon lotor*), *Capillaria* spp. occur in the mucosa of the alimentary and urinary tracts (Butterworth and Beverley-Burton, 1981), but there are no reports describing these nematodes in the respiratory tract of this host.

Prior to a field investigation of an oral vaccination against rabies in raccoons on Parramore Island (Virginia, USA; 37°32'N; 75°38'W), 23 raccoons were euthanized and various tissues were histopathologically examined to document background lesions in the resident island raccoons (Hanlon et al., 1989). The raccoons were live trapped (Tomahawk live trap Co., Tomahawk, Wisconsin, USA), euthanized by intravenous barbiturate overdose, and necropsied. Tissues were fixed in 10% neutral buffered formalin, processed for histopathology, sectioned at 6 µm and stained with hematoxylin and eosin.

An adult male raccoon necropsied in January 1989 had no observed gross le-

sions, but lesions were seen in a tissue section from the proximal region of the trachea, at the level of the thyroid glands. Within the mucosal epithelium, there were several narrow tunnels containing cross-sections of slender nematodes and their eggs (Fig. 1). The nematode had coelomyarian musculature and the eggs were barrel-shaped, unembryonated, and bioperculated (Fig. 2). These were identified as *Capillaria* (= *Eucoleus*) sp. (Chitwood and Lichtenfels, 1972). There was little inflammatory cellular infiltrate within the tunnels containing the parasites. However, the subjacent lamina propria had moderate numbers of predominantly eosinophils and lesser numbers of lymphocytes and macrophages (Fig. 1).

The taxonomy within the Capillarinae is difficult and unsatisfactory (Anderson, 1992). *Capillaria aerophila* (= *Eucoleus aerophilus*) is found commonly in the respiratory tract of many carnivores (Anderson, 1992), but not in raccoons. Pence (1975) described *Capillaria procyonis* from the esophagus of raccoons. Subsequently, this species was recorded from two other anatomic locations, the tongue (Snyder, 1988) and masticatory mucosa (Scapino and Murphy, 1978). Two other species, *Capillaria putori* in stomach and *C. plica* in the urinary bladder also are described from raccoons (Snyder and Fitzgerald, 1985; Butterworth and Beverley-Burton, 1981). During the last 10 yr we have examined tissues of >600 raccoons from many areas of the United States; this is the only raccoon in which *Capillaria* sp. was seen in the respiratory epithelium.

This case possibly represents the presence of an already known *Capillaria* sp.

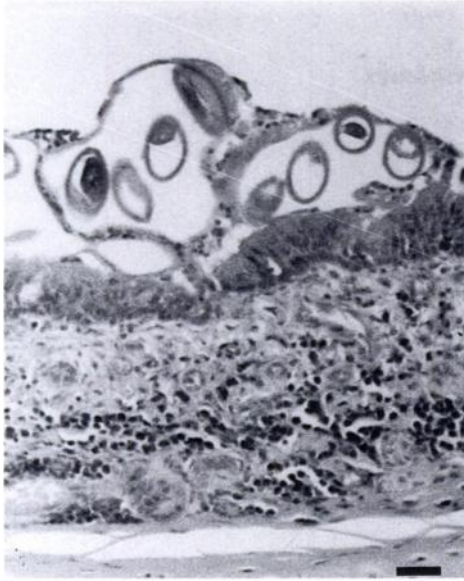


FIGURE 1. Histological section of trachea from a raccoon in Virginia showing eggs of *Capillaria* sp. within narrow tunnels in the tracheal mucosa. The subjacent lamina propria has moderate numbers of inflammatory cells. H&E, Bar = 120 μ m.

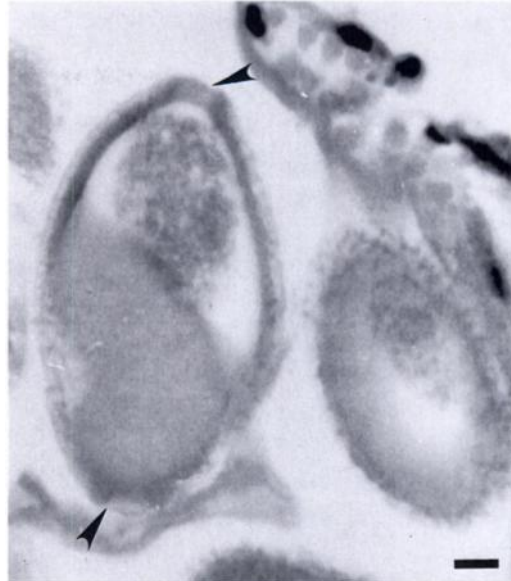


FIGURE 2. Higher magnification of Fig. 1 showing characteristic barrel-shaped unembryonated bi-periculated eggs (arrow heads) of *Capillaria* sp. H&E, Bar = 50 μ m.

from the raccoon that is localized in an aberrant site, although site selection within the host is relatively specific for these nematodes. Alternatively, this may represent a previously described pulmonary *Capillaria* sp. in an aberrant host, or perhaps a new species in its natural site and host species.

We thank B. Lehmann and S. Hindman for technical assistance. This work was supported in part by funds from the Pennsylvania Department of Agriculture, the United States Department of Agriculture (formula funds), and the Department of Pathobiology, University of Pennsylvania.

LITERATURE CITED

- ANDERSON, R. C. 1992. Nematode Parasites of Vertebrates. Their Development and Transmission. CAB International, Wallingford Oxon, United Kingdom, 578 pp.
- BUTTERWORTH, E. W., AND M. BEVERLY-BURTON. 1981. Observations on the prevalence and intensity of *Capillaria* spp. (Nematoda: Trichuroidea) in wild carnivora from Ontario, Canada. Proceedings of the Helminthologic Society of Washington 48: 24–37.
- CHITWOOD, M., AND J. R. LICHTENFELS. 1972. Identification of parasitic metazoa in tissue sections. Experimental Parasitology 32: 407–519.
- HANLON, C. L., D. E. HAYES, A. N. HAMIR, D. E. SNYDER, S. JENKINS, C. P. HABLE, AND C. E. RUPPRECHT. 1989. Proposed field evaluation of a rabies recombinant vaccine for raccoons (*Procyon lotor*). Site selection, target species characteristics, and placebo baiting trials. Journal of Wildlife Diseases 25: 555–567.
- PENCE, D. B. 1975. *Capillaria procyonis* sp. n. (Nematoda: Trichuridae) from the esophagus of the raccoon, *Procyon lotor*. The Journal of Parasitology 61: 815–818.
- SCAPINO, R. P., AND R. A. MURPHY. 1978. Nematode from the masticatory mucosa of the raccoon (*Procyon lotor*). Veterinary Pathology 15: 136–137.
- SNYDER, D. E. 1988. *Capillaria procyonis* (Nematoda: Trichuridae) eggs from the tongue of the raccoon (*Procyon lotor*). Journal of Wildlife Diseases 24: 722–723.
- , AND P. R. FITZGERALD. 1985. Helminth parasites from Illinois raccoons (*Procyon lotor*). The Journal of Parasitology 71: 274–278.
- , A. N. HAMIR, C. A. HANLON, AND C. E. RUPPRECHT. 1991. Lung lesions in an opossum (*Didelphis virginiana*) associated with *Capillaria didelphis*. Journal of Wildlife Diseases 27: 175–177.

Received for publication 10 December 1996.