



Mucormycosis in a Free-ranging Green Tree Frog from Australia

Authors: Berger, Lee, Speare, Rick, and Humphrey, John

Source: Journal of Wildlife Diseases, 33(4) : 903-907

Published By: Wildlife Disease Association

URL: <https://doi.org/10.7589/0090-3558-33.4.903>

BioOne Complete (complete.BioOne.org) is a full-text database of 200 subscribed and open-access titles in the biological, ecological, and environmental sciences published by nonprofit societies, associations, museums, institutions, and presses.

Your use of this PDF, the BioOne Complete website, and all posted and associated content indicates your acceptance of BioOne's Terms of Use, available at www.bioone.org/terms-of-use.

Usage of BioOne Complete content is strictly limited to personal, educational, and non - commercial use. Commercial inquiries or rights and permissions requests should be directed to the individual publisher as copyright holder.

BioOne sees sustainable scholarly publishing as an inherently collaborative enterprise connecting authors, nonprofit publishers, academic institutions, research libraries, and research funders in the common goal of maximizing access to critical research.

Mucormycosis in a Free-ranging Green Tree Frog from Australia

Lee Berger,^{1,2} Rick Speare,² and John Humphrey,¹ ¹CSIRO Australian Animal Health Laboratory, Geelong, Victoria, Australia 3220; ²Department of Public Health and Tropical Medicine, James Cook University, Townsville, Queensland, Australia 4811

ABSTRACT: *Mucor amphibiorum* is reported for the first time from a free-ranging native amphibian, a green tree frog (*Litoria caerulea*) from Queensland, Australia. The nasal cavity was largely replaced by granulomatous inflammatory tissue, and most internal organs had nodular granulomas. Typical mother and daughter sphaerules of *M. amphibiorum* occurred in these nodules which were due to granulomatous inflammation as well as areas of more active mixed inflammation with necrosis. Tissue homogenate from the spleen was inoculated into two cane toads (*Bufo marinus*), and one toad became infected with *M. amphibiorum*.

Key words: Amphibian, fungus, green tree frog, *Litoria caerulea*, *Mucor amphibiorum*, pathology, zygomycete.

Mucor amphibiorum is a fungus originally described by Schipper (1978) which has caused disease and mortality in captive amphibians in Europe (Frank et al., 1974; Frank, 1976) and Australia (Slocombe et al., 1995), free-ranging cane toads (*Bufo marinus*) in northern Australia (Speare et al., 1994), and in platypus (*Ornithorhynchus anatinus*) in Tasmania (Australia) (Obendorf et al., 1993; Munday and Peel, 1983). It is a dimorphic fungus which is unusual for a zygomycete; it occurs in tissues only in a spherical form, while hyphae and the usual reproductive structures are found only in the external environment (Frank et al., 1974; Speare et al., 1994). It reproduces quite differently within organs by producing numerous small daughter sphaerules that are released when the wall of the mother sphaerule degenerates. In this paper we report the occurrence and describe the pathology of *M. amphibiorum* for the first time from a free-ranging amphibian native to Australia, a green tree frog (*Litoria caerulea*).

The *L. caerulea* which was collected from a farm near Biloela (25°45'S, 150°14'E), Queensland (Australia) was

possibly lethargic, although inactivity can be normal for this species. The frog was killed by freezing and sent to the Australian Animal Health Laboratory (AAHL; Ryrie St, Geelong, Victoria, Australia). It was an adult male with a snout-urostyle length of 8.5 cm and was in a poor body condition. A solid, cream coloured mass 5 × 6 mm protruded from the snout and had spread into the surrounding skin (Fig. 1). Other external lesions were not visible. Post mortem examination revealed that the mass had spread through the mucosa and submucosa of the nasal passages, largely occluding the airways. Multiple cream coloured nodules 2 to 3 mm in diameter were present in the right lung. The spleen was enlarged and contained numerous similar nodules, many of which coalesced. Smaller nodules were present in the liver.

Microscopic examination of a crush preparation of the liver revealed many colourless, roughly spherical organisms with refractile walls. There was a great range in size with the larger organisms (mother sphaerules) containing daughter sphaerules (Fig. 2). The smaller organisms contained either no organized contents or only a few small masses.

Organs were fixed in 10% formalin and embedded in paraffin wax. Histological sections were cut at 6 µm and stained with hematoxylin and eosin (H&E), periodic acid-Schiff (PAS) or Grocott's methenamine silver (Luna, 1968). Identification of this fungus was based on its characteristic appearance in tissue sections (see Speare et al., 1994). In H&E sections, sphaerules of *M. amphibiorum* were seen within granulomas in most organs. They were similar to those seen in the crush preparation, but with eosinophilic walls and basophilic con-

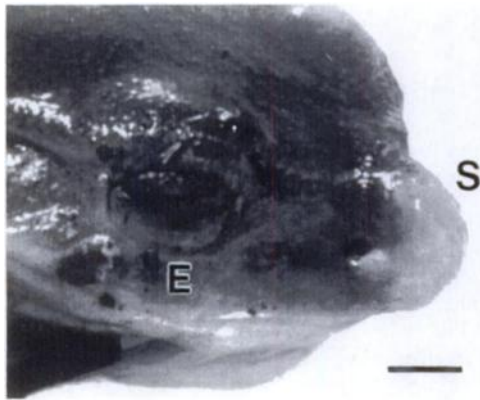


FIGURE 1. Head of *Litoria caerulea* with granulomatous mass protruding from the snout (S) caused by infection with *Mucor amphibiorum*. The eye is above the E. Bar = 5 mm.

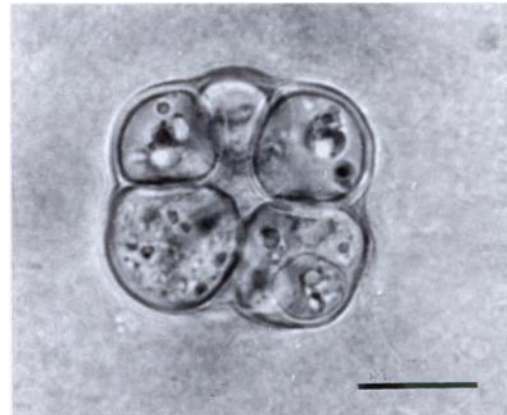

FIGURE 2. Sphaerule of *Mucor amphibiorum* containing daughter sphaerules from crush preparation of granuloma in liver of *Litoria caerulea*. Unstained. Bar = 10 μ m.

tents. Sphaerules ranged in size from 5.1 to 26.0 μ m diameter ($n = 50$) with all mother sphaerules having a diameter >12 μ m ($n = 10$). The internal structure of sphaerules varied, being either homogeneous or granular or consisting of daughter sphaerules. The organisms stained strongly with PAS and methenamine silver stain.

Sphaerules were encapsulated in discrete granulomas which consisted of macrophages, giant cells and occasional lymphocytes usually surrounded by a fibrous capsule. In some granulomas there were foci of acute necrosis associated with infiltration of neutrophils and eosinophils. Granulomas ranged from 242 to 1,610 μ m in diameter. Tissue between the granulomas appeared normal.

The nasal sinuses were largely obstructed by granulomatous inflammation and fibrous tissue (Fig. 3). Bone marrow within the nasal bone also had been replaced by the granulomatous tissue which extended through a nutrient foramen. Large granulomas occurred in the spleen, lung and kidney. In one large renal granuloma sphaerules and foreign body giant cells were present in abundance (Fig. 4). Smaller granulomas were present in liver, bladder, skeletal muscle, dermis and in the subcutaneous lymph sinuses. The liver contained many pigmented melanomacro-

phages, and a few lipid vacuoles were present. Focal areas of the ventricular myocardium were replaced by unencapsulated infiltrating granulomatous inflammation and cardiac muscle degeneration was present in these areas. The gastrointestinal tract did not appear to be involved, apart from granulomatous tissue on the serosa including one point where an infected fat body adhered to the serosa of the intestine. Lesions were not observed in testes, brain and vertebral bone marrow.

A sample of frozen spleen was thawed, macerated, and inoculated into the subdermal lymph sacs in the angle of the thigh and abdomen of two wild caught cane toads (*B. marinus*). Neither cane toad showed clinical signs after 6 wks, at which time they were killed by the percutaneous absorption of pentobarbitone sodium (324 mg/ml); (Lethabarb, Arnolds of Reading Pty Ltd., Victoria, Australia) and examined at necropsy. Lesions typical of those caused by *M. amphibiorum* were present in one toad. Most organs had multiple cream coloured nodules 1 to 2 mm in diameter. On histological examination, typical granulomas containing many *M. amphibiorum* sphaerules were seen in the spleen, liver, kidney, heart, lung, subcutaneous lymph sinuses and skeletal muscle. There were no gross or histological lesions



FIGURE 3. Section of nasal cavity of *Litoria caerulea*. The airways are largely obstructed by fibrous tissue and granulomatous inflammation which also has spread into the bone marrow; A = airway; B = bone marrow within nasal septum. H&E. Bar = 500 μ m.

in the other toad. Although only two cane toads of unknown disease status were inoculated in our experiment, we suspect the infection was transmitted experimentally as the prevalence of *M. amphibiorum* among free-ranging cane toads is <1% (Speare et al., 1994).

The green tree frog we examined had a severe infection and the extent of organ involvement was similar to that of severely affected wild cane toads (Speare et al., 1997). Two types of reactions to *M. amphibiorum* were seen in cane toads, a typical chronic histiocytic reaction with giant cells and a less common suppurative response which occurred in combination with the chronic response. The combined response was present in the green tree frog.

Mucor amphibiorum probably invaded this frog via the nasal passage since lesions in the nasal cavity were well advanced, and lesions were not observed in the gastro-

intestinal tract. The involvement of the head is unusual as only one cane toad described by Speare et al. (1997) had an infection involving the head. Frank et al. (1974) described a European toad (*Bufo bufo spinosa*) with a cutaneous infection on the nose and they suspected the nostril was the primary focus of infection.

Lesions of mucormycosis were present in the large intestine in 48% of the cane toads reported by Speare et al. (1997). Ingestion was suggested as a route of infection. Oral infection has been demonstrated experimentally in cane toads using sporangio-phores (R. Speare, unpubl. data) and in *Rana esculenta* using infected liver (Frank et al., 1974). However, attempts to experimentally infect cane toads orally by spores from infected tissue and by hyphae cultured on agar plates were unsuccessful (R. Speare, unpubl. data).

The green tree frog was in poor body condition and the increase in melanoma-

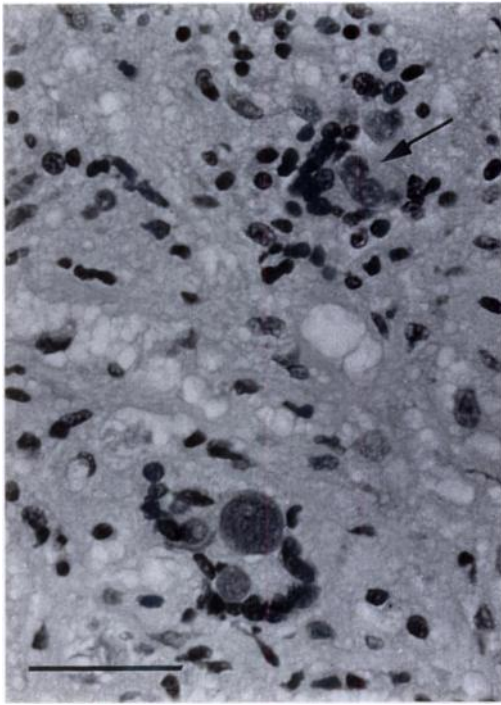


FIGURE 4. Sphaerules of *Mucor amphibiorum* surrounded by giant cells in section of granuloma in kidney of *Litoria caerulea*. Arrow indicates a mother sphaerule breaking down to release numerous daughter sphaerules. H&E. Bar = 40 μ m.

crophages in the liver suggested that it was in a state of catabolism; the pigment is suspected to result from catabolic breakdown products (R. Speare, unpubl. data). Debilitation would be expected due to the extent of the space occupying lesions, particularly in the nasal passage. Alternatively, poor condition may have lead initially to a compromised immune system allowing the fungus to invade. *M. amphibiorum* is suspected to be a primary pathogen of cane toads because heavy infections were seen in toads in good body condition (Speare et al., 1997). The epizootics that have occurred in captive amphibians (Frank, 1976; Slocombe et al., 1995) are further evidence that *M. amphibiorum* is a primary pathogen of amphibians.

Mucor amphibiorum is known to have a wide host specificity among animals with lower body temperatures, but this is the first report in a free-ranging native am-

phibian. In Australia, the diseases of cane toads have been investigated (Speare et al., 1994), but little is known about the diseases of free-ranging native frogs. This may explain why mucormycoses is known to occur in cane toads in Australia but has not been found in wild frogs. However, infection of frogs at the Royal Melbourne Zoo was thought to have been introduced by wild-caught giant green tree frogs (*Litoria infrafraenata*) from northern Australia donated to the zoo (Slocombe et al., 1995). An epizootic in captive amphibians in Europe involved a range of species, including frogs, toads and salamanders; and this was suspected to have spread from a green tree frog imported from Australia (Frank, 1976). In transmission experiments, *Rana temporaria*, *R. esculenta* and *Bufo bufo* usually died within a month, lizards were mildly infected, and rats, mice and guinea pigs were unaffected (Frank et al., 1974; Frank, 1976).

The issue of host specificity is important because the cane toad, an introduced amphibian, is expanding its range in Australia (van Beurden and Grigg, 1980). The distribution of *M. amphibiorum* in Australia is unknown, but it is possible cane toads may spread the disease which could then affect native wildlife in Australia. Biloela, near Rockhampton in northern Australia where the green tree frog was collected is within the known range of *M. amphibiorum* in cane toads (Speare et al., 1994). The distribution of the fungus, as estimated from reports of disease, is discontinuous because Tasmanian platypus and cane toads in Australia are geographically separated. Speare et al. (1994) isolated *M. amphibiorum* from soil samples and were able to grow hyphae on soil. The fungus also was isolated from feces of infected toads suggesting that cane toads may contaminate the environment. More data is needed to determine the susceptibility of Australian native frogs to *M. amphibiorum*.

We thank C. Bourne for collecting this frog and G. Russell for preparing the his-

tology. We are grateful to A. Hyatt for providing facilities and supplying the gross photograph. L. Skerratt's and K. McColl's comments on the manuscript are appreciated. L. Berger was supported by funds provided by Wet Tropics Management Authority, and by the Department of Environment and Heritage (Queensland, Australia).

LITERATURE CITED

- FRANK, W. 1976. Mycotic infections in amphibians and reptiles. In *Proceedings of the Third International Wildlife Disease Conference*, L. A. Page (ed.), Plenum Press, New York, New York, pp. 73–88.
- , U. ROESTER, AND H. J. SCHOLER. 1974. Sphaerulenbildung bei einer *Mucor*-spezies in inneren organen von amphibien. Vorläufige Mitteilung. *Zentralblatt für Bakteriologie, Parasitenkunde, Infektionskrankheiten und Hygiene, I Abteilung Originale A* 226: 405–417.
- LUNA, L. 1968. *Manual of histological staining methods of the Armed Forces Institute of Pathology*, 3rd ed. McGraw-Hill Book Company, New York, New York, 258 pp.
- MUNDAY, B. L., AND B. F. PEEL. 1983. Severe ulcerative dermatitis in platypus (*Ornithorhynchus anatinus*). *Journal of Wildlife Diseases* 19: 363–365.
- OBENDORF, D. L., B. F. PEEL, AND B. L. MUNDAY. 1993. *Mucor amphibiorum* infection in platypus (*Ornithorhynchus anatinus*) from Tasmania. *Journal of Wildlife Diseases* 29: 485–487.
- SCHIPPER, M. A. A. 1978. On certain species of *Mucor* with a key to all accepted species. *Studies in Mycology* 17: 1–52.
- SLOCOMBE, R., H. MC CRACKEN, R. BOOTH, J. SLOCOMBE, AND C. BIRCH. 1995. Infectious skin diseases of captive frogs. In *Australian Society for Veterinary Pathology—Annual proceedings*, J. Taylor (ed.), Australian Society for Veterinary Pathology, Melbourne, Australia, p. 14.
- SPEARE, R., L. BERGER, P. O'SHEA, P. W. LADDS, AND A. D. THOMAS. 1997. The pathology of mucormycosis of free-ranging cane toads (*Bufo marinus*) in Australia. *Journal of Wildlife Diseases* 33: 105–111.
- , A. D. THOMAS, P. O'SHEA, AND W. A. SHIPTON. 1994. *Mucor amphibiorum* in the toad, *Bufo marinus* in Australia. *Journal of Wildlife Diseases* 30: 399–407.
- VAN BEURDEN, E. K., AND G. C. GRIGG. 1980. An isolated and expanding population of the introduced toad *Bufo marinus* in New South Wales. *Australian Wildlife Research* 7: 305–310.

Received for publication 2 December 1996.