



Salmonella arizonae Sepsis in a Lynx

Authors: Macri, Nicholas P., Stevenson, Gregory W., and Wu, Ching Ching

Source: Journal of Wildlife Diseases, 33(4) : 908-911

Published By: Wildlife Disease Association

URL: <https://doi.org/10.7589/0090-3558-33.4.908>

BioOne Complete (complete.BioOne.org) is a full-text database of 200 subscribed and open-access titles in the biological, ecological, and environmental sciences published by nonprofit societies, associations, museums, institutions, and presses.

Your use of this PDF, the BioOne Complete website, and all posted and associated content indicates your acceptance of BioOne's Terms of Use, available at www.bioone.org/terms-of-use.

Usage of BioOne Complete content is strictly limited to personal, educational, and non - commercial use. Commercial inquiries or rights and permissions requests should be directed to the individual publisher as copyright holder.

BioOne sees sustainable scholarly publishing as an inherently collaborative enterprise connecting authors, nonprofit publishers, academic institutions, research libraries, and research funders in the common goal of maximizing access to critical research.

***Salmonella arizonae* Sepsis in a Lynx**

Nicholas P. Macri, Gregory W. Stevenson, and Ching Ching Wu, Animal Disease Diagnostic Laboratory, 1175 ADDL, Purdue University, West Lafayette, Indiana 47907-1175, USA

ABSTRACT: A 4.5-wk-old lynx (*Felis lynx*) was presented for necropsy with a history of poor growth, mild diarrhea, anemia, and lethargy. The liver was enlarged and had a 7 mm long fracture that resulted in severe intraabdominal hemorrhage and death. Microscopic lesions were indicative of severe ulcerative cystitis and septicemia. Pure cultures of *Salmonella arizonae* were isolated from the liver, kidney, and spleen. Based on differences in the chronicity of inflammation in the urinary bladder versus other organs, we speculate that chronic cystitis caused by *S arizonae* lead to septicemic infection.

Key words: Bacterial sepsis, case report, *Felis lynx*, lynx, *Salmonella arizonae*.

Salmonella spp. are ubiquitous gram-negative facultatively anaerobic bacteria that can be isolated from the gastrointestinal tract of a wide variety of domestic and wild animals (Timoney et al., 1988). In surveys of captive wildlife populations, various serotypes of *Salmonella* spp. have been isolated from the feces of reptiles, carnivores, primates, and birds, usually without clinical disease (Sethi et al., 1980; Schroder, 1970a, b). In wild felids there are few documented cases of clinical salmonellosis. A single case report by Kahn and Fawi (1963) described salmonellosis, due to *Salmonella muenster*, as the probable cause of fatal enterocolitis in a lion cub (*Felis leo*). We report a case of septicemia in a lynx (*Felis lynx*) that was caused by *Salmonella arizonae* and was associated with severe chronic ulcerative cystitis.

A 595 g female lynx, reportedly 4.5-wk-old, was presented for necropsy with a history of poor growth, mild diarrhea, anemia, and lethargy. The skinned carcass appeared anemic and emaciated. Upon dissection, the abdominal cavity had 15 ml of coagulated blood caudal to the right hepatic lobe, 10 ml of serosanguinous fluid distributed throughout the abdomen and small blood clots within the greater omen-

tum. The visceral surface of the right lobe of the liver had a 7 mm long fracture (Fig. 1). There was no evidence of vascular rupture and no other potential sources of hemorrhage were identified within the abdominal cavity. The hepatic parenchyma was mottled tan and red, friable and had gross changes suggestive of hepatomegaly (Fig. 1). The margins of the left medial lobe were rounded and the weight of the liver, 26 g, was 6% of total body weight. In healthy domestic cats the liver is approximately 3% of total body weight (Getty, 1975). No other gross lesions were observed.

Tissues were fixed in 10% formalin for 24 hr, embedded in paraffin, sectioned at 7 μ m and stained with hematoxylin and eosin. Microscopic lesions were indicative of severe chronic ulcerative cystitis and septicemia. The urinary bladder had severe diffuse chronic ulcerative and transmural cystitis characterized by a diffusely ulcerated transitional epithelium and infiltration of the propria-submucosa, muscularis and serosa by large numbers of neutrophils, lymphocytes and fibroblasts (Fig. 2). Inflammation was associated with low numbers of rod-shaped bacteria. The brain had segmental vasculitis and mild diffuse meningitis. The walls of several blood vessels were infiltrated by lymphocytes, neutrophils and small numbers of rod-shaped bacteria, similar to those described in the urinary bladder. In some areas of the brain inflammation was peracute and characterized by monomorphic colonies of rod-shaped bacteria that were not associated with inflammation. In one area of the cerebrum, the white matter had a large abscess associated with low numbers of rod-shaped bacteria. The leptomeninges were expanded by fibrin, lymphocytes and neutrophils. The liver had multifocal necrotiz-

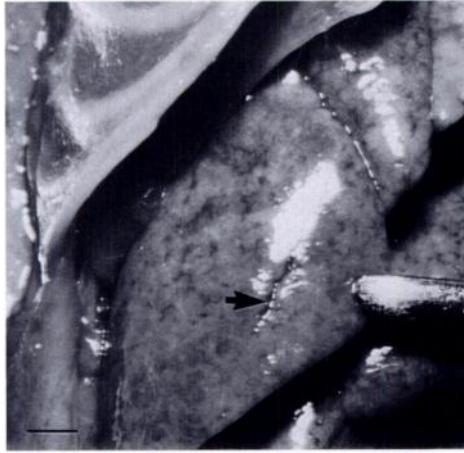


FIGURE 1. Visceral surface of the liver of a lynx cub. The parenchyma is diffusely mottled and contains a 7 mm long fracture (arrow). Bar = 4 mm.

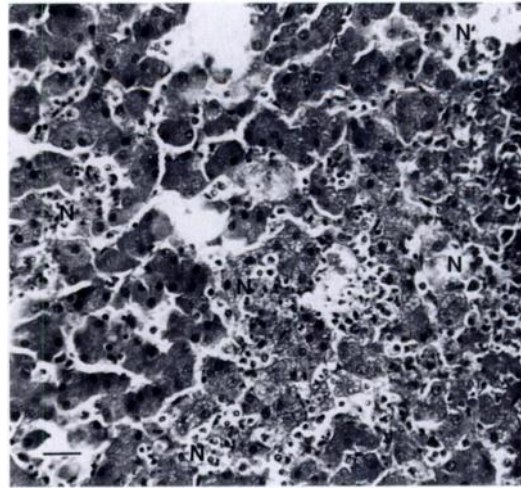


FIGURE 3. Liver of a lynx cub with bacterial sepsis. The parenchyma has areas of hepatocellular necrosis (N) containing lymphocytes and plasma cells (arrows). H&E stain. Bar = 6 μ m.

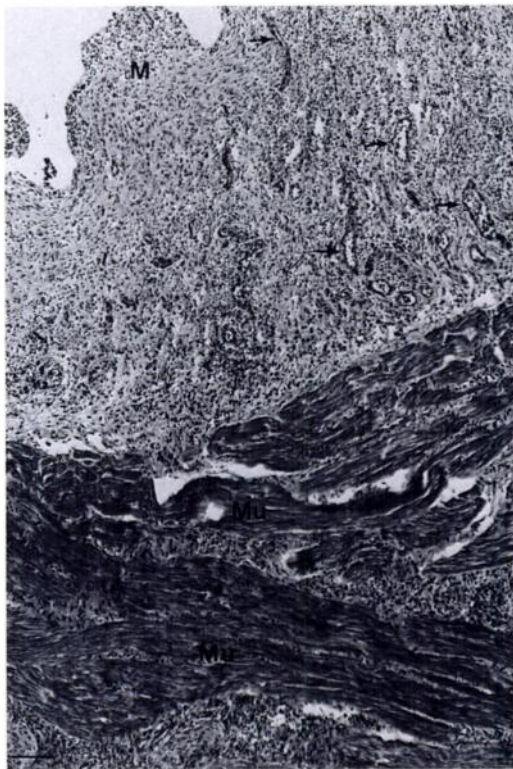


FIGURE 2. Urinary bladder of a lynx cub with bacterial sepsis. The mucosa (M) is denuded of epithelium (ulcerated) and expanded by large numbers of inflammatory cells. Blood vessels (arrows) within the mucosa are prominent as a result of endothelial swelling. The muscularis (Mu) also is infiltrated by large numbers of inflammatory cells. H&E stain. Bar = 7 μ m.

ing hepatitis with variably-sized areas of hepatocellular necrosis surrounded by lymphocytes and plasma cells (Fig. 3). Sinusoids contained low numbers of neutrophils. The lungs had mild interstitial pneumonia characterized by expansion of alveolar septa by low numbers of macrophages. The kidney, small intestine, and large intestine were microscopically normal.

Fresh samples of liver, kidney and spleen were homogenized and streaked onto blood, MacConkey, brilliant green and XLT4 agar plates respectively (Difco Laboratories, Detroit, Michigan, USA). All plates were incubated at 37 C for 24 to 48 hr. Pure cultures of a Gram-negative bacteria were isolated from each tissue. The isolate was identified as *Salmonella* sp. and further identified as *S. arizonae* by a Vitek automatic identification system (bioMerieux Vitek Inc., Hazelwood, Missouri, USA). The isolate was serotyped as *S. arizonae* 18:Z24, Z32 by the National Veterinary Services Laboratory (Ames, Iowa, USA) using a method described by Ewing (Ewing, 1986). Fluorescent antibody testing (American Bioresearch Laboratories, Seymour, Tennessee, USA) of the intestine

for feline panleukopenia and corona virus were negative. Fluorescent antibody testing (American Bioresearch Laboratories) of the liver for corona virus also was negative. No viruses were isolated from the intestine, spleen, liver, kidney, lung, or abdominal fluid.

Microscopic lesions in the liver, lung, and brain along with the isolation of pure cultures of *S. arizonae* from multiple organs were indicative of septicemia caused by *S. arizonae*. The extremely friable nature of the hepatic parenchyma probably resulted from *S. arizonae* induced necrosis and we speculate that hepatic fracture and subsequent hemorrhage could have occurred from routine movement or handling.

Salmonella arizonae is an enteric bacteria closely related to other *Salmonella* spp. and has been isolated from a variety of vertebrate species with and without clinical salmonellosis (Izadjoo et al., 1987; Jortner and Larsen, 1984; Meehan et al., 1992; Weiss et al., 1986). However, there are few reports of clinically significant *S. arizonae* infections in wild or domestic felids. In a single case report, *S. arizonae* was the cause of fatal bacteremia in an adult domestic long-haired cat (Krum et al., 1977). The paucity of reported clinical *S. arizonae* infections in cats may reflect the relatively low frequency of isolation of *Salmonella* spp. from cats in general. In one survey, *Salmonella* spp. was isolated from approximately 0.1% of samples from domestic cats submitted to a diagnostic laboratory over a 10-yr-period (Ikeda et al., 1986). In another study, *Salmonella* spp. was isolated from 2% of fecal samples from domestic cats (Ball, 1951).

The isolation of *Salmonella* spp. from fecal samples of domestic cats usually has not been associated with clinical disease (Borland, 1975). When clinical salmonellosis has been reported in cats, it was most commonly caused by *Salmonella typhimurium* and was associated with gastroenteritis, fever, and occasionally septicemia (Dow et al., 1989; Timoney et al., 1978).

In the case reported here, septicemia was caused by *S. arizonae* and although clinical signs included mild diarrhea, there was no microscopic evidence of intestinal inflammation. Chronic febrile illness without specific gastrointestinal signs has been reported in cats with *S. arizonae* and *Salmonella newport* infections (Dow et al., 1989). In man and dogs, salmonellosis is associated with immunosuppression caused by human immunodeficiency virus infection, neoplasia and chemotherapy, and hospitalization (Aserkoff and Bennett, 1969; Calvert and Leifer, 1982; Casner and Zuckerman, 1990). Reports of feline salmonellosis also have implicated hospitalization, immunosuppression by feline leukemia virus or diabetes mellitus, and lymphosarcoma in the pathogenesis of infection (Hohenhaus et al., 1990; Dow et al., 1989; Timoney et al., 1978). In the case reported here, a cause of immunosuppression leading to salmonellosis was not apparent. Viruses were not isolated from the intestine, spleen, liver, kidney, lung, or abdominal fluid and fluorescent antibody testing for feline panleukopenia, which may be immunosuppressive, was negative. Inflammation in the urinary bladder was extremely severe and more chronic than in other organs. Although it is possible that the urinary bladder was the initial site of *S. arizonae* infection, it was not cultured. Bacteremia has been associated with urinary tract infection in humans and dogs (Kornegay and Barber, 1980; Siroky et al., 1976). Bacterial infection in the bladder causes inflammation which can traumatize the transitional epithelium. Damaged transitional epithelium loses its ability to resist bacterial invasion and bacteria can then infiltrate blood vessels in the bladder wall and enter systemic circulation (Barsanti and Finco, 1986). Although the exact pathogenesis of infection could not be determined in the case reported here, severe cystitis may have resulted in systemic infection.

The authors thank the department of Bacteriology and Microbiology at the An-

imal Disease Diagnostic Laboratory at Purdue University for bacterial culture and identification. We also thank J. Samman for tissue processing for histopathology.

LITERATURE CITED

- ASERKOFF, B., AND J. V. BENNETT. 1969. Effect of antibiotic therapy in acute salmonellosis on the fecal excretion of *Salmonella*. *The New England Journal of Medicine* 281: 636-640.
- BALL, M. R. 1951. *Salmonella* in dogs and cats of the Los Angeles, Honolulu, and Bermuda areas. *Journal of the American Veterinary Medical Association* 118: 164-166.
- BARSANTI, J. A., AND D. R. FINCO. 1986. Bacteremia of urinary tract origin (urosepsis). In *Current veterinary therapy IX*, R. W. Kirk (ed.), W. B. Saunders Company, Philadelphia, Pennsylvania, pp. 1,150-1,152.
- BORLAND, E. D. 1975. *Salmonella* infection in dogs, cats, tortoises and terrapins. *The Veterinary Record* 96: 401-402.
- CALVERT, C. A., AND C. E. LEIFER. 1982. Salmonellosis in dogs with lymphosarcoma. *Journal of the American Veterinary Medical Association* 180: 56-58.
- CASNER, P. R., AND M. J. ZUCKERMAN. 1990. *Salmonella arizonae* in patients with AIDS along the U.S.-Mexican border. *The New England Journal of Medicine* 323: 198-199.
- DOW, S. W., R. L. JONES, R. A. HENIK, AND P. W. HUSTED. 1989. Clinical features of salmonellosis in cats: six cases (1981-1986). *Journal of the American Veterinary Medical Association* 194: 1,464-1,466.
- EWING, W. H. 1986. The Arizona group. In *Edwards and Ewing's, identification of Enterobacteriaceae*, Elsevier Science Publishing Company, New York, New York, pp. 319-340.
- GETTY, R. 1975. Carnivore. In *Sisson and Grossman's, the anatomy of domestic animals*, W. B. Saunders Company, Philadelphia, Pennsylvania, pp. 1,554-1,558.
- HOHENHAUS, A. E., M. P. ROSENBERG, AND S. D. MOROFF. 1990. Concurrent lymphoma and salmonellosis in a cat. *Canadian Veterinary Journal* 31: 38-40.
- IKEDA, J. S., D. C. HIRSH, S. S. JANG, AND E. L. BIBERSTEIN. 1986. Characteristics of *Salmonella* isolated from animals at a veterinary medical teaching hospital. *American Journal of Veterinary Research* 47: 232-235.
- IZADJOO, M. J., C. O. PANTOJA, AND R. J. SEIBELING. 1987. Acquisition of *Salmonella* flora by turtle hatchlings on commercial turtle farms. *Canadian Journal of Microbiology* 33: 718-724.
- JORTNER, B. S., AND C. LARSEN. 1984. Granulomatous ventriculitis of the brain in arizonosis of turkeys. *Veterinary Pathology* 21: 114-115.
- KAHN, A. Q., AND M. T. FAWI. 1963. *Salmonella muenster* as a probable cause of diarrhea in a lion cub. *The Veterinary Record* 75: 791-792.
- KORNEGAY, J. N., AND D. L. BARBER. 1980. Diskospondylitis in dogs. *Journal of the American Veterinary Medical Association* 177: 337-341.
- KRUM, S. H., D. R. STEVENS, AND D. C. HIRSH. 1977. *Salmonella arizonae* bacteremia in a cat. *Journal of the American Veterinary Medical Association* 170: 42-44.
- MEEHAN, J. T., K. A. BROGDEN, C. COURTNEY, R. C. CUTLIP, AND H. D. LEHMKUHL. 1992. Chronic proliferative rhinitis associated with *Salmonella arizonae* in sheep. *Veterinary Pathology* 29: 556-559.
- SCHROEDER, H. D. 1970a. Distribution of *Salmonellae* in captive wild animals. 1. Occurrence in mammals and birds. *Veterinary Bulletin* 41: 95.
- . 1970b. Distribution of *Salmonellae* in captive wild animals. 2. In reptiles. *Veterinary Bulletin* 41: 263.
- SETHI, M. F., V. D. SHARMA, AND S. P. SINGH. 1980. The occurrence of *Salmonellae* in zoo animals in Uttar Pradesh and Delhi (India). *International Journal of Zoonoses* 7: 15-18.
- SIROKY, M. B., R. A. MOYLAN, G. AUSTIN, AND C. A. OLLSON. 1976. Metastatic infection secondary to genitourinary tract sepsis. *American Journal of Medicine* 61: 351-360.
- TIMONEY, J. F., H. C. NEIBERT, AND F. W. SCOTT. 1978. Feline salmonellosis a nosocomial outbreak and experimental studies. *Cornell Veterinarian* 68: 211-219.
- , J. F., J. H. GILLESPIE, F. W. SCOTT, AND J. E. BARLOUGH. 1988. The enterobacteriaceae-The non-lactose fermenters. In *Hagan and Bruner's Microbiology and infectious diseases of domestic animals*, Cornell University Press, Ithaca, New York, pp. 74-88.
- WEISS, S. H., M. J. BLASER, F. P. PALEOLOGO, R. E. BLACK, A. C. MCWHORTER, M. A. ASBURY, G. P. CARTER, R. A. FELDMAN, AND D. J. BRENNER. 1986. Occurrence and distribution of serotypes of the Arizona subgroup of *Salmonella* strains in the United States from 1967 to 1976. *Journal of Clinical Microbiology* 23: 1,056-1,064.

Received for publication 14 July 1996.