

Pseudorabies in Captive Coyotes

Authors: James T. Raymond, Robert G. Gillespie, Mary Woodruff, and Evan B. Janovitz

Source: Journal of Wildlife Diseases, 33(4) : 916-918

Published By: Wildlife Disease Association

URL: <https://doi.org/10.7589/0090-3558-33.4.916>

BioOne Complete (complete.BioOne.org) is a full-text database of 200 subscribed and open-access titles in the biological, ecological, and environmental sciences published by nonprofit societies, associations, museums, institutions, and presses.

Your use of this PDF, the BioOne Complete website, and all posted and associated content indicates your acceptance of BioOne's Terms of Use, available at www.bioone.org/terms-o-use.

Usage of BioOne Complete content is strictly limited to personal, educational, and non - commercial use. Commercial inquiries or rights and permissions requests should be directed to the individual publisher as copyright holder.

BioOne sees sustainable scholarly publishing as an inherently collaborative enterprise connecting authors, nonprofit publishers, academic institutions, research libraries, and research funders in the common goal of maximizing access to critical research.

Pseudorabies in Captive Coyotes

James T. Raymond,¹ Robert G. Gillespie,² Mary Woodruff,¹ and Evan B. Janovitz,¹ ¹Animal Disease Diagnostic Laboratory, Purdue University, West Lafayette, Indiana 47907, USA and ²Gillespie Veterinary Clinic, Brownstown, Indiana 47220, USA

ABSTRACT: Pseudorabies (Aujeszky's disease) was diagnosed in three adult captive coyotes (*Canis latrans*) from southern Indiana (USA). The coyotes died in their outdoor enclosure within a 48 hr period. Histopathology revealed multifocal, nonsuppurative meningoencephalitis and eosinophilic intranuclear inclusion bodies within neurons. Samples of brain were positive for pseudorabies virus by fluorescent antibody testing and virus isolation. Source of infection was the probable consumption of pseudorabies virus-infected pig carcasses.

Key words: Aujeszky's disease, *Canis latrans*, case report, coyotes, pseudorabies.

In March 1996, three adult male captive coyotes (*Canis latrans*) were submitted dead to the Animal Disease Diagnostic Laboratory (Purdue University, West Lafayette, Indiana, USA) for routine necropsy. The coyotes were part of a group of 11 coyotes that had been trapped in southern Indiana (centered at 38°50'W, 86°00'N, Jackson County, USA). They were housed in outdoor wire-fenced kennels for a period of 3 wks during which time urine was collected and sold to private individuals. The coyotes were fed ad libitum well water, generic dry dog food, and meat scraps including pig carcasses. Within a 48 hr period, two coyotes were found dead, and a third exhibited anorexia and abnormal vocalization for several hours prior to death.

At necropsy, an area (approximately 120 mm in diameter) of alopecia and hyperemia was found in the submandibular skin of two coyotes. The soft tissues beneath the submandibular skin and extending ventrally along the neck were edematous and hemorrhagic. The small intestinal serosa of all coyotes was red and finely granular, and the intestinal contents consisted of varying amounts of dark red to black semi-formed fecal material.

Sections of submandibular skin, brain, lung, heart, adrenal gland, spleen, small

intestine, large intestine, tongue, liver, stomach, kidney, urinary bladder, pancreas, and bone marrow from all coyotes were fixed in 10% neutral buffered formalin, embedded in paraffin, sectioned at 5.0 μ m, and stained with hematoxylin and eosin (H&E). Histologically, multifocal, nonsuppurative meningoencephalitis was found in all coyotes. This lesion was characterized by multifocal hemorrhage, necrosis, gliosis, and mononuclear cellular infiltrates around blood vessels and in the neuropil (Fig. 1). Most neurons appeared unaffected, although a few had a swollen eosinophilic cytoplasm and rare acidophilic intranuclear inclusion bodies. The leptomeninges and subarachnoid space were multifocally infiltrated and expanded by angiocentric accumulations of mononuclear cells, red blood cells and proteinaceous edema fluid (Fig. 2). Other histologic findings were submandibular dermatitis and enteric nematodiasis.

Samples of fresh brain, lung, small intestine, liver, spleen, tongue, and urinary bladder from two coyotes were submitted for virologic testing. Suspensions of 10% brain tissue were centrifuged at 3,000 rpm, passed through a 0.45 μ m filter, inoculated onto four Leighton tubes (Bellco Glass Company, Vineland, New Jersey, USA), and cultured on Dog-9 cells which consisted of a mixture of laboratory derived DogK-553 and A72-180 cells with B5-c-1 and MV-ILU cells (American Type Culture Collection, Rockville, Maryland, USA). Both samples of brain tissue showed cytopathic effects at post-inoculation day four. To confirm the diagnosis, infected cell cultures stained positive with a pseudorabies conjugate (National Veterinary Services Laboratory, Ames, Iowa, USA).

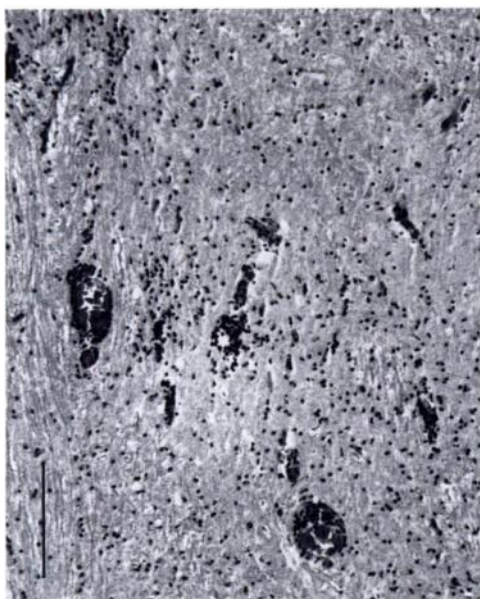


FIGURE 1. Cerebrum from a coyote with pseudorabies. Mononuclear cells circumscribed cerebral blood vessels and extended into the adjacent neuropil. H&E stain. Bar = 300 μ m.

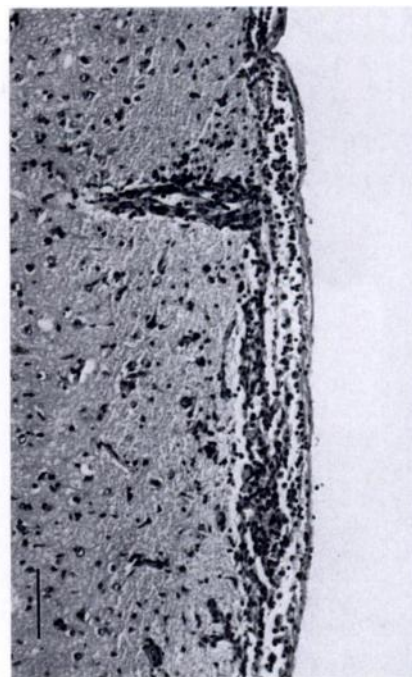


FIGURE 2. Cerebrum from a coyote with pseudorabies. Leptomeninges and subarachnoid space were infiltrated by mononuclear cells. H&E stain. Bar = 200 μ m.

The diagnosis of pseudorabies in these coyotes was based upon histopathologic lesions within the brain and the isolation of pseudorabies virus from two brains. Pseudorabies is caused by an alpha herpesvirus that primarily infects swine, but it also can infect naturally other domestic and wildlife species (Trainer, 1981; Kluge et al., 1992). In dogs, pseudorabies is a sporadic disease that tends to occur where it is enzootic in swine (Vandeveldt, 1984). A 1 yr epidemiological survey of pseudorabies cases from Illinois reported a diagnosis of pseudorabies in two coyotes (Woods et al., 1980).

Clinical signs of pseudorabies in dogs are anorexia, ptialism, restlessness, vocalization, tachypnea, dyspnea, emesis, diarrhea, and pruritis (Monroe, 1989). Approximately 50% of dogs infected with pseudorabies exhibit vocalization, which was observed in one of the coyotes prior to death. Although sometimes referred to as mad itch, only about 50% of dogs with pseudorabies exhibit pruritis (Monroe, 1989). An intense cutaneous irritation can

develop at the point of inoculation or at the terminal distribution of an infected nerve trunk (Jubb and Huxtable, 1992). The skin becomes denuded of hair and the subcutaneous tissue of the region often is edematous and hemorrhagic (Trainer, 1981). Although pruritis was not reported in any of these coyotes, the areas of alopecia and submandibular inflammation and edema were most likely due to unnoticed traumatic rubbing or scratching.

Pseudorabies has a rapidly fatal course in dogs with an incubation period of 2 to 10 days (Whitley and Nelson, 1980). Death usually follows within 48 hrs from onset of clinical signs (Monroe, 1989), and many dogs are found dead without any evidence of clinical disease. In this case, two coyotes were found dead without any signs of disease, and all three coyotes died within a 48 hr period.

Histopathologic lesions within the brain of all coyotes were similar to those report-

ed in dogs infected with pseudorabies virus (Whitley and Nelson, 1980; Shell et al., 1981). The centripetal movement of the virus along or in sensory nerves from the site of inoculation to the brainstem results in the localization of histopathologic lesions within the brainstem, nerves, and ganglia at the site of inoculation (Jubb and Huxtable, 1992).

The source of pseudorabies virus infection in dogs is commonly through the ingestion of virus-contaminated tissues (Whitley and Nelson, 1980; Jubb and Huxtable, 1992). Direct spread of virus from infected to noninfected dogs probably does not occur (Pensaert et al., 1980), but direct transmission from wild hogs to hunting dogs has been recorded (Nettles and Erickson, 1984). In some cases, the development of pseudorabies in mammals other than swine often is the first indication of disease presence on a swine farm. These coyotes were fed pig offal from a swine herd (Decatur County, Indiana, USA) that was believed to be pseudorabies negative. However, subsequent to this case, the herd tested positive for pseudorabies.

The authors thank J. Samman for preparation of histopathology specimens and S. Royer for technical assistance with photography. This report was submitted as journal paper no. 15125 of the Purdue Agricultural Experiment Station (West Lafayette, Indiana, USA).

LITERATURE CITED

- JUBB, K. F., AND C. R. HUXTABLE. 1993. Nervous system. *In* Pathology of domestic animals. 4th ed., K. F. Jubb, P. C. Kennedy, and N. Palmar (eds.). Academic Press, Inc., San Diego, California, pp. 406–409.
- KLUGE, J. P., G. W. BERAN, H. T. HILL, AND K. B. PLATT. 1992. Pseudorabies (Aujeszky's disease). *In* Diseases of swine, 7th ed., A. D. Leman and B. E. Straw (eds.). The Iowa State University Press, Ames, Iowa, pp. 312–323.
- MONROE, W. E. 1989. Clinical signs associated with pseudorabies in dogs. *Journal of American Veterinary Medical Association* 195: 599–602.
- NETTLES, Y. F., AND G. A. ERICKSON. 1984. Pseudorabies in wild swine. *In* Proceedings of the 88th Annual Meeting of the United States Animal Health Association. Carter Printing Co., Richmond, Virginia, pp. 505–506.
- PENSAERT, M. B., S. COMMEYNE, AND K. ANDRIES. 1980. Vaccination of dogs against pseudorabies (Aujeszky's Disease), using an inactivated-virus vaccine. *American Journal of Veterinary Research* 41: 2016–2019.
- SHELL, L. G., R. W. ELY, AND R. A. CRANDELL. 1981. Pseudorabies in a dog. *Journal of the American Veterinary Medical Association* 178: 1159–1161.
- TRAINER, D. O. 1981. Pseudorabies. *In* Infectious diseases of wild mammals, 2nd ed., J. W. Davis, L. H. Karstad, and D. O. Trainer (eds.). The Iowa State University Press, Ames, Iowa, pp. 102–107.
- VANDEVELDE, M. 1984. Pseudorabies. *In* Clinical microbiology and infectious diseases of the dog and cat, C. E. Greene (ed.). W. B. Saunders Company, Philadelphia, Pennsylvania, pp. 381–385.
- WHITLEY, R. D., AND S. L. NELSON. 1980. Pseudorabies (Aujeszky's Disease) in the canine: Two atypical cases. *Journal of the American Animal Hospital Association* 16: 69–72.
- WOODS, G. T., A. L. STARKEY, AND P. L. SPENCER. 1980. Epidemiology of pseudorabies in Illinois swine herds. Results of a serologic survey and reported virus isolations in 1976 and 1977. *Bovine Practice* 1: 33–42.

Received for publication 23 August 1996.