



RESPONSES OF RED FOXES TO FIRST AND SECOND INFECTION WITH *SARCOPTES SCABIEI*

Authors: Little, Susan E., Davidson, William R., Rakich, Pauline M., Nixon, Tammy L., Bounous, Denise I., et al.

Source: Journal of Wildlife Diseases, 34(3) : 600-611

Published By: Wildlife Disease Association

URL: <https://doi.org/10.7589/0090-3558-34.3.600>

BioOne Complete (complete.BioOne.org) is a full-text database of 200 subscribed and open-access titles in the biological, ecological, and environmental sciences published by nonprofit societies, associations, museums, institutions, and presses.

Your use of this PDF, the BioOne Complete website, and all posted and associated content indicates your acceptance of BioOne's Terms of Use, available at www.bioone.org/terms-of-use.

Usage of BioOne Complete content is strictly limited to personal, educational, and non - commercial use. Commercial inquiries or rights and permissions requests should be directed to the individual publisher as copyright holder.

BioOne sees sustainable scholarly publishing as an inherently collaborative enterprise connecting authors, nonprofit publishers, academic institutions, research libraries, and research funders in the common goal of maximizing access to critical research.

RESPONSES OF RED FOXES TO FIRST AND SECOND INFECTION WITH *SARCOPTES SCABIEI*

Susan E. Little,^{1,5} William R. Davidson,^{1,2} Pauline M. Rakich,³ Tammy L. Nixon,¹
Denise I. Bounous,⁴ and Victor F. Nettles¹

¹ Southeastern Cooperative Wildlife Disease Study, College of Veterinary Medicine, The University of Georgia, Athens, Georgia 30602, USA

² School of Forest Resources and Southeastern Cooperative Wildlife Disease Study, College of Veterinary Medicine, The University of Georgia, Athens, Georgia 30602, USA

³ Athens Diagnostic Laboratory, College of Veterinary Medicine, The University of Georgia, Athens, Georgia 30602, USA

⁴ Department of Pathology, College of Veterinary Medicine, The University of Georgia, Athens, Georgia 30602, USA

⁵ Corresponding author (e-mail: slittle@calc.vet.uga.edu)

ABSTRACT: The clinical response of red foxes (*Vulpes vulpes*) to the mange mite, *Sarcoptes scabiei*, was characterized by infection of five, 4-mo-old red foxes with *S. scabiei* originally isolated from a wild red fox. The infected foxes and three uninfected control foxes were monitored with weekly complete blood counts and biweekly serum chemistry profiles, hypersensitivity tests, and evaluation of skin biopsies. After 7 wk, the foxes were treated and held free of infection for 2 mo. Six foxes, three previously infected and three with no history of exposure, were then infected with the same isolate of *S. scabiei* and followed for another 7 wk; two additional previously infected foxes were held as treatment controls, and two foxes with no history of exposure as naive controls. All infected foxes developed significant immediate (Type I) hypersensitivity reactions to a *S. scabiei* mite extract within 2 wk of exposure and maintained this reaction as long as 4 mo after clearance of mites. Pronounced mast cell hyperplasia and infiltration with eosinophils were the earliest inflammatory cell responses noted in biopsy samples from infected foxes and were maintained throughout infection. Infected foxes also showed significant increases in white blood cell counts, due primarily to increases in numbers of circulating neutrophils and eosinophils. Clinical response, severity of disease, and relative numbers of mites per cm² of skin of previously infected foxes and foxes undergoing their first infection did not differ. These results show that red foxes develop strong immediate hypersensitivity reactions to *S. scabiei* but, under our experimental conditions, did not exhibit resistance to reinfection.

Key words: Hypersensitivity, immune response, red fox, *Sarcoptes scabiei*, sarcoptic mange, *Vulpes vulpes*.

INTRODUCTION

Sarcoptic mange caused by the mite *Sarcoptes scabiei* is the most frequently diagnosed disease in wild red foxes (*Vulpes vulpes*) in the southeastern United States (Little et al., 1998). Outbreaks of mange in wild red foxes in other areas are well documented (Olive and Riley, 1948; Pryor, 1956; Trainer and Hale, 1969; Stone et al., 1974; Gier et al., 1978; Todd et al., 1981). Experimental infection studies have shown that red foxes are highly susceptible to developing sarcoptic mange and that, in the absence of treatment, infected foxes become extremely debilitated and die within 2 to 3 mo (Stone et al., 1972; Mörner and Christensson, 1984).

Despite the importance of this disease to red foxes, characterization of the clinical

response of red foxes infected with *S. scabiei* has not been reported. Furthermore, descriptions of the histologic changes associated with infection in red foxes are limited (Mörner and Christensson, 1984) and changes over time were not evaluated. Treatment and release of individual foxes has been undertaken occasionally during epizootics of sarcoptic mange in wild canid populations, as was done during an outbreak in Arctic foxes (*Alopex lagopus*) in Sweden in 1986 (Mörner, 1992). However, no studies have been reported that evaluated the ability of red foxes or other wild canids to develop immunity to this disease following treatment. In order to better understand the effects of sarcoptic mange on red foxes, a series of experimental infection trials was conducted in which foxes

were infected with *S. scabiei*, treated and cleared of infection, and then reinfected with the same strain of mites. A variety of clinical parameters and skin biopsies were evaluated periodically from all animals.

MATERIALS AND METHODS

Research animals

Three litters of red fox pups 6 to 8 wk of age were obtained through state wildlife agencies. The foxes were housed individually in the laboratory animal facility at the College of Veterinary Medicine (The University of Georgia, Athens, Georgia, USA) in stainless steel dog kennels, fed free-choice dry and/or canned commercial kitten food, and provided with free-choice water for the duration of the study. All foxes were dewormed with oral fenbendazole (Panacur,[®] Hoescht-Roussel, Somerville, New Jersey, USA) and parenteral praziquantel (Droncit,[®] Mobay Corporation, Shawnee, Kansas, USA), and vaccinated against canine distemper virus (Fervac[®]-D, United Vaccines, Madison, Wisconsin, USA) and canine parvovirus (Canine Parvo, Rhone Merieux, Inc., Athens, Georgia, USA) prior to initiation of the study.

Maintenance of mite strain

A red fox housed in the laboratory animal facility at The University of Georgia was infected with *S. scabiei* from a wild red fox submitted as a clinical case from Hall County (Georgia, USA; 34°20'N, 83°50'W) by rubbing sections of mangy skin on the dorsum of the live donor fox. Mites were identified as *S. scabiei* based on Fain's (1968) description and representative specimens are deposited in the U.S. National Parasite Collection, (Beltsville, Maryland, USA; USNPC No. 87064).

Preparation of *S. scabiei* extract

A sterile *S. scabiei* extract was prepared following a protocol modified from Davis and Moon (1990) for use in hypersensitivity tests on foxes. Skin sections from the clinical case used to infect the donor fox were used in a large-scale mite collection. Several sections of mangy skin were placed in one side of a glass dish. The other half of the dish was placed on a slide warmer at 37 C, which encouraged large numbers of mites to migrate out of the crusts over a period of 24 hr. Freed mites were then collected by pipetting into sterile phosphate buffered saline (PBS), the mixture was inverted several times to rinse the mites, and the mites were collected by centrifugation at 1500 × g.

Mites were washed twice more in fresh PBS, passaged through a dounce homogenizer, and then sonicated. The resultant solution was passaged through a 0.45 µ filter and stored in aliquots at -20 C. Protein concentration was estimated by spectrometric absorptivity (Warburg and Christian, 1942), and the solution was diluted to 50 µg/mL with sterile saline.

Hypersensitivity testing

Hypersensitivity tests were performed as previously described (Muller et al., 1989) using the prepared mite extract and commercially available sterile saline as a negative control and histamine as a positive control (Greer Laboratories, Lenoir, North Carolina, USA). Commercially available house dust mite antigen (Greer Laboratories) also was used due to shared antigens between *S. scabiei* and dust mites (Arlian et al., 1988, 1991). All foxes were sedated with 2 mg/kg ketamine and 10 mg/kg xylazine delivered by intramuscular injection prior to injection of test solutions. The fur was clipped closely from an approximately 6 by 12-cm area of skin over the right thorax, and four injection sites 2.5 cm apart were marked with an indelible marker. Intradermal injections (0.05 ml) of either saline, histamine, house dust mite antigen, or sterile mite extract were made below each mark. Injection sites were examined at 15 min after antigen administration for immediate hypersensitivity reactions, and at 24, 48, and 72 hr for delayed hypersensitivity reactions. Reactions were measured with a ruler to the nearest mm. To minimize variability, the same individual performed all injections and measurements of resultant reactions.

Experimental design

The donor fox with sarcoptic mange was euthanatized and 1.5 cm² pieces of skin containing mites in hyperkeratotic crusts were excised. Thirty-two skin sections were combined and randomly assorted into groups of four pieces each. Three groups of four pieces were completely digested by gently heating in 10% potassium hydroxide (KOH). The digested material was suspended in 1 L of water with 0.1% Triton-X, and the number of mites present in a 20-mL aliquot was determined by calculating the average of three counts performed with the aid of a dissecting microscope. Remaining skin sections were held in groups of four on 5.08-cm² gauze sponges overnight at 4 C. Foxes were infected by applying the gauze sponge with adherent skin sections to a shaved area on the dorsum for approximately 3 hr. After application, skin sections were collected and frozen at -20 C. Sections were later thawed, di-

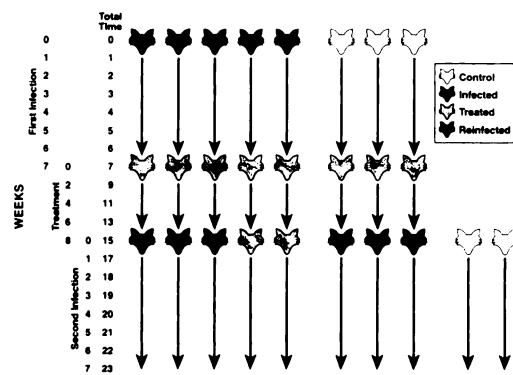


FIGURE 1. Schematic of experimental design used in infection trial. In the first phase of the experimental trial, five foxes were infected with *S. scabiei* and three were monitored as uninfected controls. After 7 wk, all foxes were treated. Eight wk later, six foxes, three previously infected and three naive, were infected with the same strain of mite. Two previously infected were held as treatment controls, and an additional two foxes were added to the study as naive controls. After 7 wk, all foxes were killed and complete necropsy performed.

gested in 10% KOH, diluted and aliquoted as described above, and the number of mites remaining determined. Approximate inoculum size was calculated as the difference between the mean number of mites present pre- and post-application of skin sections.

Experimental design is summarized in Figure 1. In the first trial, five, 4-mo-old foxes were infected as described above, and three cohort foxes were held as naive controls. An additional fox also was infected with mites to serve as a donor for the reinfection trial. Presence of mites was confirmed by skin scrapings every 2 wk during infection. After 7 wk of infection, both infected and control foxes were treated with 400 µg/kg subcutaneous ivermectin (Ivomec® 1% Injection for Cattle, MSD-AgVet, Rahway, New Jersey, USA); treatment was repeated in 2 wk. The foxes were held for 8 wk free of infection as determined by complete resolution of skin lesions and repeated negative skin scrapings. Six foxes, three previously-infected and three naive animals, were then infected with the original strain of mites from the second donor fox using the same protocol as described for initial infection. Two previously-infected foxes were held and monitored as treatment controls, and two additional cohort foxes were included as naive controls. All foxes were clinically monitored for another 7 wk of infection and then killed.

Clinical monitoring of foxes

Physical examination was performed on each fox prior to infection and once weekly thereafter. Data recorded on each fox included rectal temperature, body weight, extent of lesion development, and result of microscopic examination of skin scrapings. Blood samples were collected by jugular venipuncture once weekly into vacutainer tubes containing either EDTA or no preservative. Whole blood samples were submitted each week to the Clinical Pathology Laboratory (College of Veterinary Medicine, The University of Georgia, Athens, Georgia, USA) for complete blood counts. Serum samples were submitted biweekly to the same laboratory for serum chemistry profile. Complete blood counts included determination of the following parameters: hematocrit, red blood cell count, hemoglobin concentration, mean corpuscular volume, mean corpuscular hemoglobin, mean corpuscular hemoglobin concentration, platelet count, total white blood cell count, and leukocyte differential. Serum chemistry profile included determination of the following analytes: urea nitrogen, creatinine, total protein, albumin, alkaline phosphatase, alanine aminotransferase, glucose, sodium, potassium, chloride, bicarbonate, anion gap, calcium, and phosphorus. Serum globulin levels were calculated by subtracting albumin from total protein. Reference ranges for complete blood count and serum chemistry profile analytes were determined by repeated testing of blood samples from eight normal red foxes previously housed in the laboratory animal facility at The University of Georgia. The range was established at two standard deviations (SD) above or below the mean value for each analyte or cell type considered.

Hypersensitivity tests were performed biweekly as described above. One, 6-mm skin biopsy was collected from affected skin of each fox every two weeks. Each biopsy was halved and placed in 10% buffered formalin. After overnight fixation, biopsy specimens were embedded in paraffin, sectioned at 3 µm, mounted on microscope slides, and sections of each biopsy stained with either hematoxylin and eosin or Giemsa. Sections were examined for changes in histologic appearance of skin and presence of inflammatory cells.

Complete necropsy examination was performed on each fox. A 1.5-cm square of skin from the site of inoculation was excised and stored frozen at -20 C. Skin sections were later thawed, completely digested by heating with 10% KOH, and the total number of mites present in each section determined as described above, except that digested material was dilut-

ed in a total volume of 250 ml of water with 0.1% Triton-X. Sections of tissue collected into 10% buffered formalin for histologic examination included brain, lung, trachea, heart, tongue, esophagus, stomach, duodenum, jejunum, ileum, large intestine, pancreas, liver, spleen, prescapular lymph node, inguinal lymph node, sublumbar lymph node, kidney, adrenal gland, gonad, and multiple sections of skin. Tissues were processed routinely, stained with hematoxylin and eosin or Giemsa and examined microscopically.

Analyses of data

Mean and standard error (SE) for body weight, rectal temperature, hypersensitivity reactions, each serum chemistry analyte, and each complete blood count parameter were calculated for the control group and the infected group during the first infection, and for the control group, the infected group, the reinfected group, and the treated group during the second infection. Differences in these values among control, infected, reinfected, and treated groups were evaluated with the univariate repeated-measures analysis using the repeated statement for SAS (SAS Institute, Inc., Cary, North Carolina; Sokal and Rohlf, 1981). Mean and standard deviation were calculated for mite numbers for sections of skin from each donor fox, from previously naive foxes, and from previously infected foxes. Differences in mite numbers between groups were evaluated using a *t*-test (SigmaStat for Windows Version 1.0, Jandel Corporation, Chicago, Illinois, USA). For all tests, significance was considered at $P < 0.05$.

RESULTS

The inoculum of *S. scabiei*, as determined by examination of sections of skin from the donor fox, contained an average of $8,292 \pm 818$ (SD) mites in all life stages, and did not differ significantly between first- and second-infection trials. After 1 to 3 hr of application, skin samples contained $2,763 \pm 301$ mites during the first infection, and $2,781 \pm 225$ mites during the second. By inference, approximately 5,500 mites transferred to each fox during infection and reinfection. Adult mites were found in scrapings from affected skin of all exposed foxes from 1 to 3 wk after exposure until treatment or euthanasia in both first- and second-infection trials, respectively. Progressive lesions developed in all

foxes, with crusting and alopecia gradually spreading from the site of inoculation to involve most of the body by 4 wk after infection. Mites were not present in skin scrapings of any foxes 2 wk after the first treatment with ivermectin, in any foxes prior to reinfection, or in naive control foxes or treatment control foxes at any time in the study. Body temperature in infected foxes was not different from control foxes at any point during infection, although two infected foxes developed generalized dermal hyperemia in the fifth week of their first infection. Infected foxes did not differ in body weight compared to control foxes during first or second infection.

After 7 wk of infection and reinfection, extensive lesions covered much of the body of both previously infected and previously naive foxes. The lesions consisted of severe hyperkeratosis and lichenification. Relative infection levels ranged from 178 to 4,578 mites per cm^2 skin, and mean infection intensities did not differ significantly between previously infected ($1,982 \pm 1331$) and previously naive (404 ± 118) foxes.

Red blood cell parameters were not significantly different between infected and uninfected foxes (Fig. 2). Total white blood cell count increased significantly in infected foxes ($P < 0.05$) but not in reinfected foxes ($P = 0.07$), and remained within the reference range for both naive control and treatment control animals (Fig. 3). The increase in white blood cell count was due to increases in both circulating neutrophils and eosinophils, with eosinophils increasing earlier in infection than neutrophils (Fig. 3). Serum chemistry analytes did not differ significantly among groups.

Foxes developed positive immediate hypersensitivity reactions to *S. scabiei* extract within 2 wk of infection and maintained this reaction as long as 4 mo after treatment (Fig. 4). Repeated measures analysis showed that the immediate hypersensitivity reaction to *S. scabiei* extract was significantly larger than in naive control foxes in

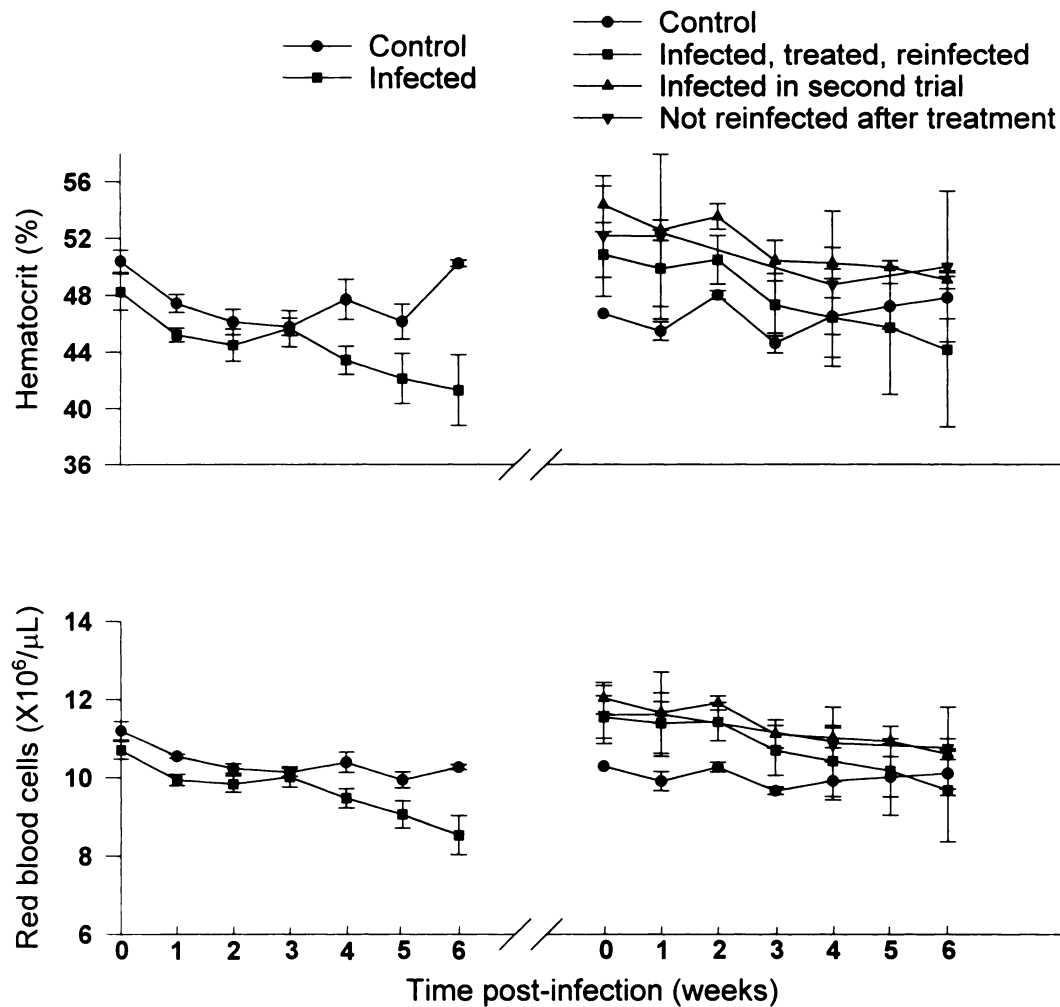


FIGURE 2. Hematocrit and numbers of circulating red blood cells in control, infected, treated, and reinfected red foxes. Brackets about values represent 2 SE.

the infected group during the first trial, and in the infected, reinfected, and treated groups during the second trial. This reaction progressively increased with duration of infection (time-treatment interaction $P = 0.025$). Immediate hypersensitivity reactions to dust mite antigen was not significantly larger in infected foxes during the first ($P = 0.08$) or second ($P = 0.07$) infections. Foxes did not develop delayed hypersensitivity reactions to any of the antigens at the 24, 48, or 72 hr time points examined at any time during the study.

Skin biopsies collected 2 wk after infection showed parakeratotic and orthokera-

totic hyperkeratosis, acanthosis, mast cell hyperplasia, and infiltration of the superficial dermis with eosinophils and neutrophils. Lymphocytes and plasma cells were occasionally noted in most sections and in some biopsies were the dominant cell type. Hyperkeratosis and epidermal hyperplasia intensified as infections progressed leading to the formation of epidermal pegs extending deep into the dermis by the fourth week of infection. Hyperplasia of mast cells in the superficial dermis also became more pronounced, and focally intense areas of eosinophil infiltrations were present in the superficial dermis. The epi-

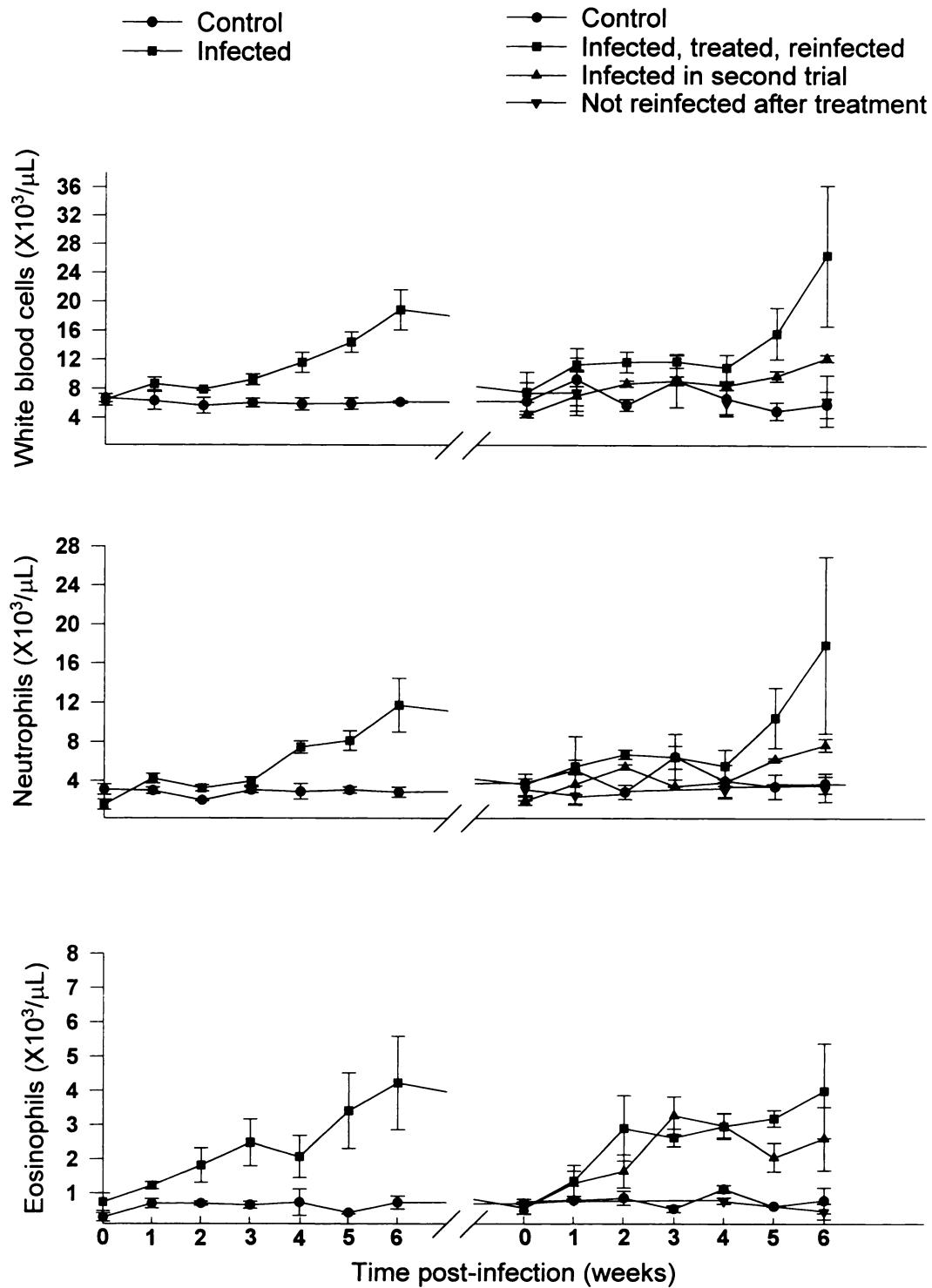


FIGURE 3. Numbers of circulating white blood cells, neutrophils, and eosinophils in control, infected, treated, and reinfected red foxes. Brackets about values represent 2 SE.

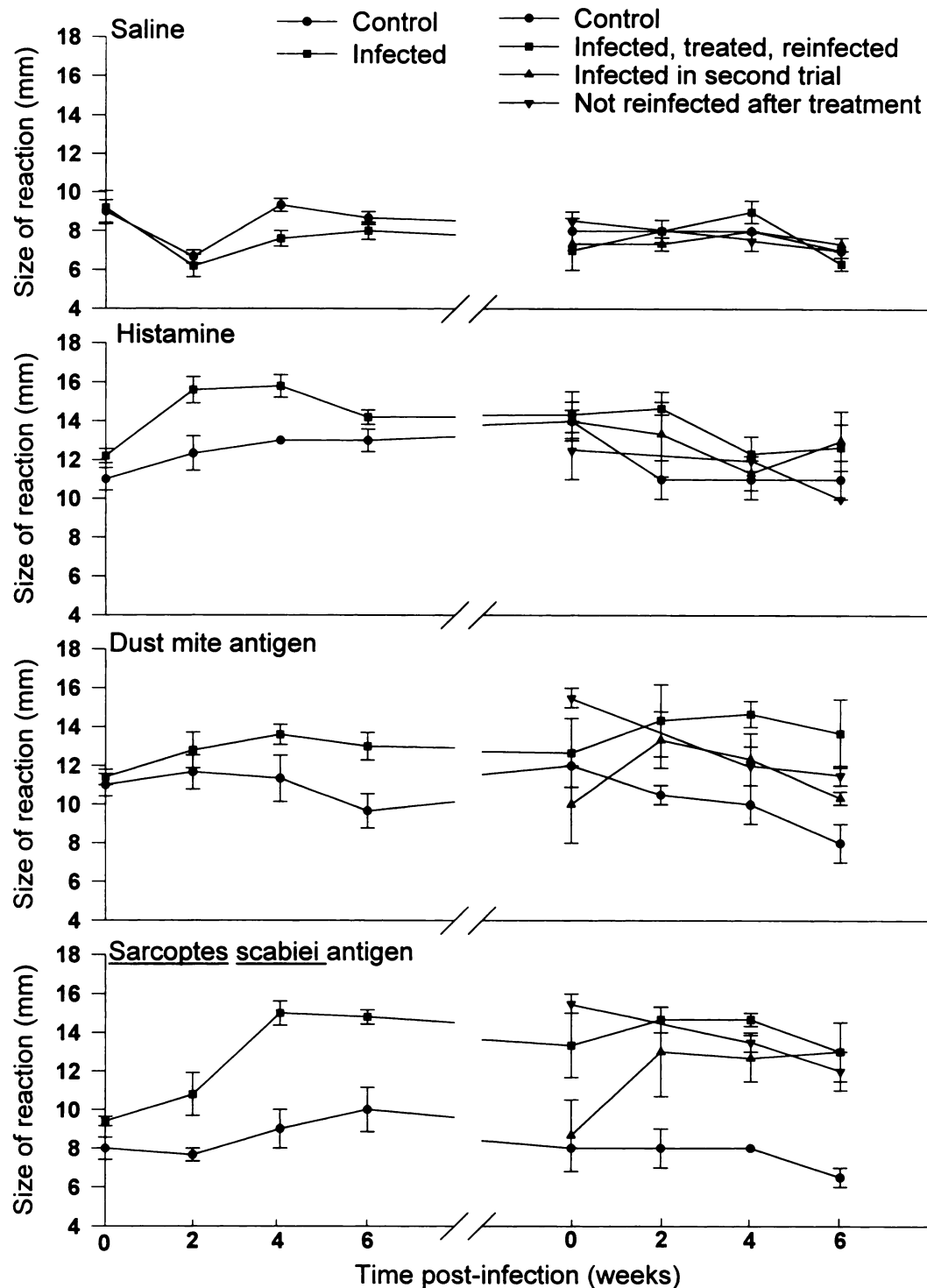


FIGURE 4. Development of the responses of control, infected, treated, and reinfected red foxes to intra-dermal injections of saline, histamine, dust mite antigen, and *Sarcoptes scabiei* extract. Brackets about values represent 2 SE.




FIGURE 5. Photomicrograph of skin section of a red fox after 6 wk of infection with *Sarcoptes scabiei* showing pronounced mast cell (arrows) hyperplasia. Giemsa stain. Bar = 40 μ m.

dermis had subcorneal and intraepidermal pustules filled with eosinophils and, occasionally, neutrophils. In the fourth and sixth weeks of both initial and reinfection exposures, marked hyperkeratosis, intense mast cell hyperplasia, and fibroplasia of the superficial dermis were the dominant changes (Fig. 5). Foci of lymphocytes and plasma cells were evident in the superficial dermis of some infected foxes but were not consistently found in skin samples from either the first or second infections. Cross-sections of mites were visible within the hyperkeratotic crust of most sections examined (Fig. 6). Both naive and treatment control foxes had normal, thin epidermis with occasional mast cells adjacent to superficial dermal vessels.

The lymph nodes of infected foxes were markedly hyperplastic with numerous prominent reactive follicles. Large numbers of eosinophils and neutrophils were present in sinuses of the lymph nodes and

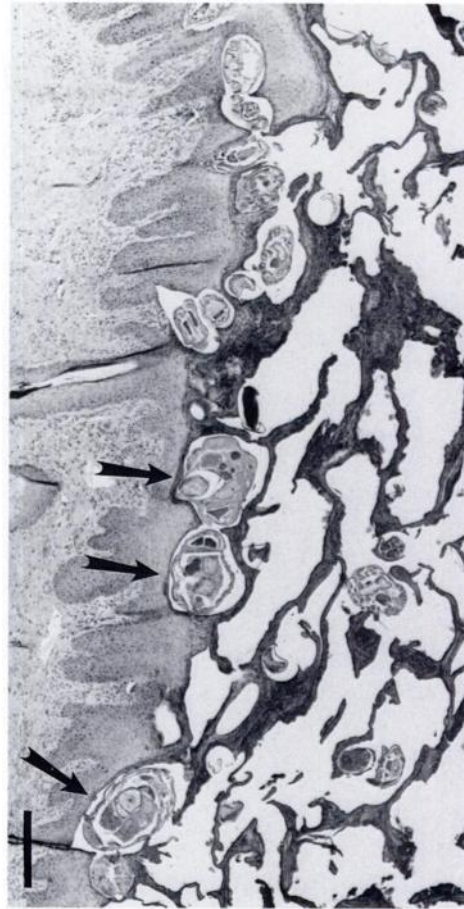


FIGURE 6. Photomicrograph of skin section of a red fox after 4 wk of infection with *Sarcoptes scabiei* showing acanthotic epidermis and cross-sections of mites (arrows) within hyperkeratotic crust. H&E. Bar = 100 μ m.

spleen. One fox had severe scrotal dermatitis and associated bilateral testicular atrophy characterized histologically as testicular degeneration with hyalinized tubules, depletion of germinal and Sertoli cells, and complete absence of sperm from epididymal tubules. Endogenous lipid pneumonia characterized by multifocal aggregates of macrophages filled with foamy lipid material was present in two infected foxes and one naive control fox. Mild encephalitis with glial nodules and mononuclear perivascular cuffing was noted in three infected foxes and one treatment control fox.

DISCUSSION

The red foxes in this study failed to develop resistance to reinfection by *S. scabiei* and remained fully susceptible to recurrence of sarcoptic mange. These findings stand in contrast to work done with *S. scabiei* in other species. Experimental work on human subjects found that 40% developed immunity to reinfection with *S. scabiei*; in those persons who were reinfected, mite numbers were much reduced from initial infection (Mellanby, 1944). Sixty-five percent of rabbits cleared of initial infection developed significantly reduced levels of infection upon subsequent exposure to mites, a difference attributed to cell-mediated immunity (Arlian et al., 1994). Seven of eight dogs (88%) previously infected with sarcoptic mange spontaneously cleared a subsequent infection (Arlian et al., 1996).

The results of this study indicate that these red foxes did not establish an effective immune response against *S. scabiei* under our experimental conditions. Although the low number of foxes included in the reinfection trial may have prevented the detection of significant development of resistance, the discrepancy between the two treatment groups in mean numbers of mites per cm² skin at the end of the study, even with the high degree of variation, suggests that resistance to reinfection was not exhibited in these animals. Failure to detect resistance to reinfection in this study also may be due to the dose of mites used to challenge previously infected foxes. In similar work with dogs, more than 3,000 mites were used for initial infection, but only 1,000 mites for the reinfection trial in which immunity was demonstrated (Arlian et al., 1996). Rabbits that exhibited immunity were infected and challenged with approximately 1,000 mites (Arlian et al., 1994), and humans with an unspecified, but apparently low, number of mites (Mellanby, 1944). Our study challenged previously infected foxes with approximately 5,500 mites, an exposure level po-

tentially high enough to overwhelm any acquired defense mechanisms.

During both first and second infections with *S. scabiei*, foxes developed an inflammatory leukogram characteristic of chronic suppurative disease with a marked eosinophilia. These changes in white blood cell profile, as well as the decreasing trend in packed cell volume and red blood cell count, are in agreement with results seen in dogs infected with sarcoptic mange (Arlian et al., 1995b). Although wild, *S. scabiei*-infected coyotes had no measurable shift in white blood cell differential when compared to uninfected coyotes from the same area (Pence et al., 1983), confounding factors inherent to wild populations may have prevented detection of significant differences. Significant differences were not apparent in serum biochemistry values of infected foxes in our study, a finding in agreement with work done in dogs (Arlian et al., 1995b).

All foxes infected in this study developed strong immediate hypersensitivity reactions to *S. scabiei* mite extract and maintained this reaction as long as 4 mo after treatment and complete resolution of clinical signs. These results resemble those found in pigs (Davis and Moon, 1990), with the exception that no delayed hypersensitivity reactions were detected in any foxes at any point during first or second infection. Our findings of only immediate hypersensitivity reactions are in agreement with the histopathologic appearance of skin lesions, which demonstrated that although mixed inflammatory cells were present in the lesions, mast cells and eosinophils indicative of immediate hypersensitivity reactions predominated throughout infection as compared to lymphocytes and macrophages of delayed hypersensitivity (Tizard, 1992).

The use of *S. scabiei* extract produced more reliable immediate hypersensitivity results than that of the antigenically-related dust mite preparation. *Sarcoptes scabiei* and the house dust mites, *Dermatophagoides farinae* and *D. pteronyssinus*, share

antigenic epitopes (Falk et al., 1981; Arlian et al., 1988, 1991), and 71% of rabbits immunized with *Dermatophagoides* spp. exhibited resistance to infection with *S. scabiei* (Arlian et al., 1995a). However, the equivocal responses of infected and previously infected red foxes to dust mite antigen in this study are similar to reports that dust mite antigen is not reliable in testing dogs for exposure to *S. scabiei* (Schwartzman, 1977).

The marked mast cell hyperplasia and infiltration with eosinophils and neutrophils seen in these foxes parallels the dermal changes reported from wild foxes with sarcoptic mange (Little et al., 1998). This study also revealed that lesions associated with sarcoptic mange in red foxes are not limited to the skin. The lymphoid hyperplasia in all foxes, and the testicular degeneration seen in one fox, were considered to be results of severe *S. scabiei* infection. Wild red foxes with sarcoptic mange almost invariably have generalized lymphadenopathy (Little et al., 1998). In other studies, lymphadenopathy occurred in more than 27% of dogs with scabies (Folz, 1984) and was reported in a dog with severe, crusted scabies (Anderson, 1981). Testicular degeneration due to scrotal acariasis has been reported in a ram with chorioptic mange (Rhodes, 1976) and presumably is caused by increased scrotal temperature due to acanthosis of the overlying epidermis. The development of testicular degeneration indicates that sarcoptic mange may be able to hinder reproduction of red foxes directly as well as indirectly by affecting behavior (Overskaug, 1994).

Recrudescence of sarcoptic mange was not detected in treated foxes at any point during the 4-mo period evaluated. Both gross and histologic appearance of skin of treated foxes returned to normal, as did levels of circulating white blood cells. These results confirm that, in the absence of subsequent exposure, ivermectin treatments as suggested by others (Berge and Smeds, 1984; Scheidt et al., 1984) are ef-

fective at eliminating both the infection and the lesions produced in red foxes with sarcoptic mange. Nevertheless, a strong immediate hypersensitivity reaction to *S. scabiei* mite extract persists as long as 4 mo after resolution of clinical disease.

The severity of disease produced in experimentally infected red foxes in this study and others (Stone et al., 1972; Mörner and Christensson, 1984), together with the demonstrated predominance of immediate hypersensitivity reactions and the failure of red foxes to exhibit resistance to reinfection, suggest that red foxes may not be able to mount an appropriate immune response to infection as compared to other experimentally infected species. This inability to develop immunity may explain the apparent devastating effect of infection on individual wild red foxes and on red fox populations (Mörner, 1992). However, these findings do not preclude the ability of wild red foxes in a natural setting to spontaneously clear low-grade infections as reported by Storm et al. (1976) or to develop protective immunity.

ACKNOWLEDGMENTS

The authors thank L. Fox and W. Vanscoy for providing study animals; C. Waters for submitting the mite-source clinical case; C. Sewell, A. Meadows, D. Kavanaugh, and M. Hensley for valued technical assistance; Z. Ristic for instruction on intradermal skin testing; and the staff of The University of Georgia College of Veterinary Medicine Laboratory Animal Resources facility. This study was supported through sponsorship from the fish and wildlife agencies of Alabama, Arkansas, Florida, Georgia, Kansas, Kentucky, Louisiana, Maryland, Mississippi, Missouri, North Carolina, Puerto Rico, South Carolina, Tennessee, Virginia, and West Virginia. Funds were provided by the Federal Aid to Wildlife Restoration Act (50 Stat. 917) and through Grant Agreement 14-45-0009-94-906, National Biological Service, U.S. Department of the Interior.

LITERATURE CITED

- ANDERSON, R. K. 1981. Norwegian scabies in a dog: a case report. *Journal of the American Animal Hospital Association* 17: 101-104.
- ARLIAN, L. G., D. L. VYSZENSKI-MOHER, AND A. M. GILMORE. 1988. Cross-antigenicity between

- Sarcoptes scabiei* and the house dust mite, *Dermatophagoides farinae* (Acari: Sarcoptidae and Pyroglyphidae). *Journal of Medical Entomology* 25: 240–247.
- , D. L. VYSZENSKI-MOHER, S. G. AHMED, AND S. A. ESTES. 1991. Cross-antigenicity between the scabies mite, *Sarcoptes scabiei*, and the house dust mite, *Dermatophagoides pteronyssinus*. *Journal of Investigative Dermatology* 96: 349–354.
- , C. M. RAPP, D. L. VYSZENSKI-MOHER, AND M. S. MORGAN. 1994. *Sarcoptes scabiei*: Histopathological changes associated with acquisition and expression of host immunity to scabies. *Experimental Parasitology* 78: 51–63.
- , C. M. RAPP, AND M. S. MORGAN. 1995a. Resistance and immune response in scabies-infected hosts immunized with *Dermatophagoides* mites. *American Journal of Tropical Medicine and Hygiene* 52: 539–545.
- , M. S. MORGAN, C. M. RAPP, AND D. L. VYSZENSKI-MOHER. 1995b. Some effects of sarcoptic mange on dogs. *The Journal of Parasitology* 81: 698–702.
- , M. S. MORGAN, C. M. RAPP, AND D. L. VYSZENSKI-MOHER. 1996. The development of protective immunity in canine scabies. *Veterinary Parasitology* 62: 133–142.
- BERGE, G. N., AND E. SMEDS. 1984. Efficacy of ivermectin against *Sarcoptes scabiei* var. *canis* infections of foxes. *Nordisk Veterinarmedicin* 36: 156–161.
- DAVIS, D. P., AND R. D. MOON. 1990. Density of itch mite, *Sarcoptes scabiei* (Acari: Sarcoptidae) and temporal development of cutaneous hypersensitivity in swine mange. *Veterinary Parasitology* 36: 285–293.
- FAIN, A. 1968. Study of the variability of *Sarcoptes scabiei* with a revision of the Sarcoptidae. *Acta Zoologica et Pathologica Antverpiensia* 47: 1–196.
- FALK, E. S., S. DALE, R. BOLLE, AND B. HANEBERG. 1981. Antigens common to scabies and house dust mites. *Allergy* 36: 233–238.
- FOLZ, S. D. 1984. Canine scabies (*Sarcoptes scabiei* infection). *The Compendium on Continuing Education for the Practicing Veterinarian* 176: 176–184.
- GIER, H. T., S. M. KRUCKENBERG, AND R. J. MARLER. 1978. Parasites and diseases of coyotes. In *Coyotes: Biology, behavior, and management*, M. Bekoff (ed.). Academic Press, Inc., New York, New York, pp. 37–71.
- LITTLE, S. E., W. R. DAVIDSON, ELIZABETH W. HOWERTH, PAULINE M. RAKICH, AND VICTOR F. NETTLES. 1998. Diseases diagnosed in red foxes from the southeastern United States *Journal of Wildlife Diseases* 34: 620–624.
- MELLANBY, K. 1944. The development of symptoms, parasitic infections, and immunity in human scabies. *Parasitology* 35: 197–206.
- MÖRNER, T., AND D. CHRISTENSSON. 1984. Experimental infection of red foxes (*Vulpes vulpes*) with *Sarcoptes scabiei* var. *vulpes*. *Veterinary Parasitology* 15: 159–164.
- . 1992. Sarcoptic mange in Swedish wildlife. *Revue Scientifique et Technique Office International Des Epizooties* 11: 1115–1121.
- MULLER, G. H., R. W. KIRK, AND D. W. SCOTT. 1989. *Small animal dermatology*. W. B. Saunders Company, Philadelphia, Pennsylvania, 1007 pp.
- OLIVE, J. R., AND C. V. RILEY. 1948. Sarcoptic mange in the red fox in Ohio. *Journal of Mammalogy* 29: 73–74.
- OVERSKAUG, K. 1994. Behavioural changes in free-ranging red foxes (*Vulpes vulpes*) due to sarcoptic mange. *Acta Veterinaria Scandinavica* 35: 457–459.
- PENCE, D. B., L. A. WINDBERG, B. C. PENCE, AND R. SPROWLS. 1983. The epizootiology and pathology of sarcoptic mange in coyotes, *Canis latrans*, from south Texas. *The Journal of Parasitology* 69: 1100–1115.
- PRYOR, L. B. 1956. Sarcoptic mange in wild foxes in Pennsylvania. *Journal of Mammalogy* 37: 90–93.
- RHODES, A. P. 1976. The effect of extensive chorioptic mange of the scrotum on reproductive function of the ram. *Australian Veterinary Journal* 52: 250–257.
- SCHEIDT, V. J., L. MEDLEAU, R. L. SEWARD, AND R. M. SCHWARTZMAN. 1984. An evaluation of ivermectin in the treatment of sarcoptic mange in dogs. *American Journal of Veterinary Research* 45: 1201–1202.
- SCHWARTZMAN, R. M. 1977. Scabies in animals. In *Scabies and pediculosis*, M. Orkin (ed.). J. B. Lippincott, Philadelphia, Pennsylvania, pp. 96–98.
- SOKAL, R. R., AND F. J. ROHLF. 1981. *Biometry: The principles and practice of statistics in biological research*, 2nd ed. W. H. Freeman and Company, New York, New York, 859 pp.
- STONE, W. B., E. PARKS, B. L. WEBER, AND F. J. PARKS. 1972. Experimental transfer of sarcoptic mange from red foxes and wild canids to captive wildlife and domestic animals. *New York Fish and Game Journal* 19: 1–11.
- , B. F. TULLAR, J. B. ZEH, AND B. L. WEBER. 1974. Incidence and distribution of mange mites in foxes in New York. *New York Fish and Game Journal* 21: 163–166.
- STORM, G. L., R. D. ANDREWS, R. L. PHILLIPS, R. A. BISHOP, D. B. SINIFF, AND J. R. TESTER. 1976. Morphology, reproduction, dispersal, and mortality of midwestern red fox populations. *Wildlife Monographs* 49: 1–74.
- TIZARD, I. 1992. *Veterinary immunology: An introduction*, 4th ed. W. B. Saunders Company, Philadelphia, Pennsylvania, 498 pp.

- TRAINER, D. O., AND J. B. HALE. 1969. Sarcoptic mange in red foxes and coyotes of Wisconsin. *Bulletin of the Wildlife Disease Association* 5: 387–391.
- TODD, A. W., J. R. GUNSON, AND W. M. SAMUEL. 1981. Sarcoptic mange: An important disease of coyotes and wolves in Alberta, Canada. *In* Worldwide Furbearer Conference Proceedings, J. A. Chapman and D. Pursley (eds.). R. R. Donnelly and Sons, Falls Church, Virginia, pp. 706–729.
- WARBURG, O., AND W. CHRISTIAN. 1942. Isolierung und kristallisation des gärungsferments enolase. *Biochemische Zeitschrift* 310: 384–421.

Received for publication 27 March 1997.