

Synovial Chondromatosis in Raptors

Authors: Stone, Elizabeth G., Walser, Mary M., Redig, Patrick T., Rings, Bret, and Howard, David J.

Source: Journal of Wildlife Diseases, 35(1) : 137-140

Published By: Wildlife Disease Association

URL: <https://doi.org/10.7589/0090-3558-35.1.137>

BioOne Complete (complete.BioOne.org) is a full-text database of 200 subscribed and open-access titles in the biological, ecological, and environmental sciences published by nonprofit societies, associations, museums, institutions, and presses.

Your use of this PDF, the BioOne Complete website, and all posted and associated content indicates your acceptance of BioOne's Terms of Use, available at www.bioone.org/terms-of-use.

Usage of BioOne Complete content is strictly limited to personal, educational, and non - commercial use. Commercial inquiries or rights and permissions requests should be directed to the individual publisher as copyright holder.

BioOne sees sustainable scholarly publishing as an inherently collaborative enterprise connecting authors, nonprofit publishers, academic institutions, research libraries, and research funders in the common goal of maximizing access to critical research.

Synovial Chondromatosis in Raptors

Elizabeth G. Stone,^{1,6} Mary M. Walser,² Patrick T. Redig,³ Bret Rings,⁴ and David J. Howard^{5,1,3} The Raptor Center, University of Minnesota, St. Paul, Minnesota 55108, USA; ² Department of Veterinary Pathobiology, University of Minnesota, St. Paul, ⁴ Lilly Research Laboratories, Fayetteville, Arizona 72704, USA; ⁵ Savage Tower Animal Hospital, Savage, Minnesota 55378, USA; ⁶ Corresponding author (e-mail: merrill@fallsnet.com).

ABSTRACT: Fourteen raptors, consisting of 13 great horned owls (*Bubo virginianus*) and one red-tailed hawk (*Buteo jamaicensis*), from central and north central Minnesota, western Wisconsin, and eastern South Dakota (USA) were admitted to a raptor rehabilitation center between June 1992 and June 1995, with perisynovial and synovial chondromatosis affecting multiple joints. Birds were severely debilitated primarily due to loss of shoulder motion. The etiology of these lesions in raptors is unknown.

Key words: *Bubo virginianus*, *Buteo jamaicensis*, case report, great horned owl, red-tailed hawk, synovial chondromatosis.

Thirteen great horned owls (*Bubo virginianus*) and one red-tailed hawk (*Buteo jamaicensis*) were admitted to The Raptor Center (University of Minnesota, St. Paul, Minnesota, USA) between June 1992 and June 1995, with radiographically detected mineralized nodules surrounding single or multiple joints (Fig. 1). Lesions involved the scapulo-humeral joint, sterno-coracoid joint, femoro-acetabular joint, femoro-tibiotarsal joint, tibiotarso-tarsometatarsal joint, tarsometatarso-phalangeal joint, and metacarpo-phalangeal joint, as determined by radiography and post-mortem dissection (Table 1). No evidence of degenerative joint disease was present.

Upon admission, most birds were thin and unable to fly due to severely restricted mobility of one or both shoulders. Based on examination of plumage, all birds were adult of undetermined age. Birds were admitted throughout the year (Table 1), and were found within a 150 km radius of the Minneapolis/St. Paul city limits (45°00'N, 93°25'W) with four exceptions. These four birds were found within a 300 km radius of the above locality at (46°30'N, 93°45'W (owl), 47°10'N, 93°40'W (owl), 47°15'N, 93°50'W (hawk), and 45°40'N, 96°55'W (owl). Follow-up radiographs done of one

bird at 4 wk showed slight progression of mineralization.

Clinical chemistry profiles were measured in eight birds (Cobras Mira Analyzer, Roche Manufacturer, Branchburg, New Jersey, USA) to assess for evidence of a hypercalcemic etiology for dystrophic mineralization. Heparinized blood was collected from the brachial vein and centrifuged at approximately 1,200 rpm for 5 min. Plasma was aspirated within 30 min of blood collection and stored at -5 C. Average values of seven blood chemistries deviated from normal values at this lab (P.T. Redig, unpubl. data) (Table 2). Abnormal findings included hyperkalemia, hyperphosphatemia, hyperchloremia, hypocalcemia, uremia, hyperuricemia acidemia, and hypoalbuminemia. Blood from three affected and one unaffected great horned owls was submitted to the Animal Health Diagnostic Laboratory (Lansing, Michigan, USA) for analysis of fluoride and vitamin A levels to rule out these known toxic causes of exostoses in animals (Botha et al., 1993, Christiansen and Wiig, 1991, Araya et al., 1990). Values were considered normal, and ranged from 0.045 µg/ml to 0.053 µg/ml for fluoride (control 0.041 µg/ml) and 1,146 ng/ml to 2,105 ng/ml for total vitamin A (control 1,853 ng/ml).

All birds were killed after admission, with an intravenous bolus of 1 ml pentobarbital (Beuthanasia-D Special, Sherring-Plough Animal Health Corp, Kenilworth, New Jersey, USA). Necropsy was performed immediately on 10 birds including the red-tailed hawk. Of the eight birds for which sex was recorded, two were male and six were female. On gross necropsy, mineralized nodules were closely adhered to connective tissues of associated joints

TABLE 1. Distribution of lesions in great horned owls and a red-tailed hawk with synovial chondromatosis in Minnesota.

Date admitted	Species	Number of affected joints						
		Scapulo-humeral	Sterno-coracoid	Femoro-acetabular	Femoro-tibiotarsal	Tibiotarso-tarsometatarsal	Tarsometatarsophalangeal	Metacarpophalangeal
6/5/92	GHOW ^a	2	0	1	0	0	0	2
4/1/93	GHOW	2	0	2	0	0	0	0
7/19/93	GHOW	2	2	0	1	0	0	0
9/22/93	GHOW	2	0	0	0	0	0	1
10/26/93	RTHA ^b	2	0	0	0	2	2	0
12/27/93	GHOW	2	2	0	0	0	0	0
6/9/94	GHOW	2	2	0	0	0	0	0
6/13/94	GHOW	2	2	0	0	0	0	0
8/17/94	GHOW	2	0	0	0	0	0	0
9/5/94	GHOW	2	2	1	0	0	0	0
12/18/94	GHOW	2	0	0	0	0	0	0
3/27/95	GHOW	2	2	0	0	0	0	0
6/10/95	GHOW	2	2	0	0	0	0	0
7/8/95	GHOW	2	2	2	2	0	0	0
Total		28	16	6	3	2	2	3

^a Great horned owl.

^b Red-tailed hawk.

and contained serosanguinous fluid-filled cysts. Articular cartilage appeared normal. Fluid from one bird was plated on sheep blood agar, MacConkey agar, and colistin nalidixic acid agar, (CNA) and inoculated on tryptic soy broth (all media, DIFCO Laboratories, Detroit Michigan, USA), for aerobic culture. Plates were incubated at 37 C for 48 hr with 5% CO₂. Broth was plated at 24 hr and incubated for 48 hr. No growth was observed.

Samples of lesions involving multiple joints from eight birds were submitted for histopathology. Tissues were fixed in 10% neutral buffered formalin, routinely processed, paraffin embedded, sectioned at four µm and stained by Harris' hematoxylin and eosin. Histopathologic findings were consistent among birds. The nodules included several connective tissue types. Typical nodules were composed of a core of trabecular bone, and these commonly contained active marrow spaces. Surrounding or admixed with the osseous core was a combination of hyaline cartilage and/or dense fibrous connective tissue. Transition zones between cartilage and bone

were common. Some nodules were attached to or continuous with the synovial lining of joints or bursae (Fig. 2). In these, there was marked fibrovascular proliferation of the synovium. Gram ($n = 2$) and acid fast ($n = 2$) stains (Campbell, 1994) of tissues revealed no bacteria or fungi.

Lesions were consistent with synovial chondromatosis, a poorly defined disease recognized in humans and domestic animals (Pool, 1990). Synovial chondromatosis is characterized by the formation of chondral or osteochondral nodules in synovial tissue of joint, tendon sheath, or bursa. The nodules may become pedunculated and break off, forming loose bodies in the joint (Flo et al., 1987). In humans and animals, two forms of synovial chondromatosis are recognized. Primary, or idiopathic, synovial chondromatosis is the spontaneous formation, usually in one joint, of intrasynovial nodules in an otherwise normal joint. This condition is rarely found in animals (Flo et al., 1987). In humans, males are affected twice as commonly as are females (Pool, 1990). Secondary synovial chondromatosis follows

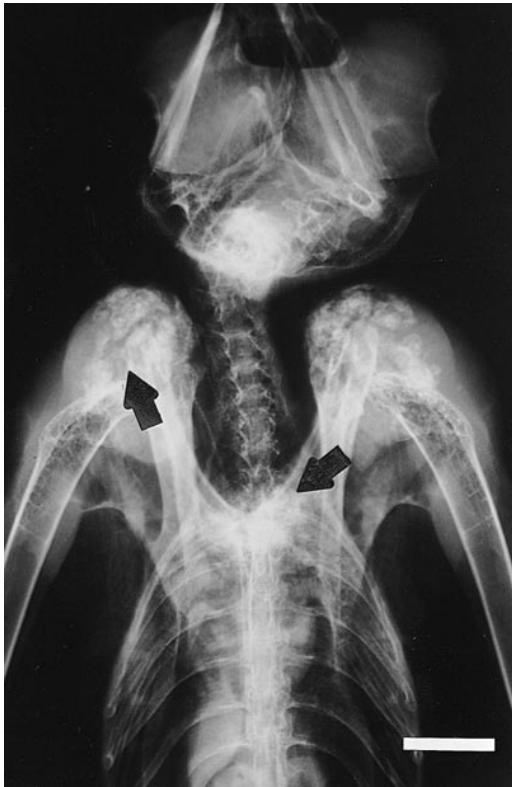

FIGURE 1. Ventrodorsal radiographic view of a great horned owl showing bilateral mineralized foci affecting the scapulo-humeral and sterno-coracoid joints (arrows). Bar = 2 cm

traumatic, degenerative, or inflammatory joint disease and has no sex predisposition (Flo et al., 1987; Pool, 1990). Recently, synovial chondromatosis of unknown etiology was described in a great-horned owl in Iowa (Howard et al., 1996).

The predominantly bilateral distribution and absence of osteoarthritis argue against a traumatic or degenerative etiology in the raptors we observed. Possibly, chronic inflammation from joint strain led to the observed lesions. As might be expected, the joints of the wings were most commonly affected. Abnormalities noted in the clinical chemistries do not reveal an underlying metabolic etiology. Hypocalcemia was most likely due to concurrent hypoalbuminemia observed in five of the eight hypocalcemic birds, although for the remaining three birds hypocalcemia was of undetermined

TABLE 2. Mean (range) values for clinical chemistry parameters for raptors with synovial chondromatosis versus normal values of unaffected birds in Minnesota.

	Study birds mean (range)	Normal reference ^a
Sodium (mmol/L)	153 (144–161)	148–164
Potassium (mmol/L)	3.6 (2.5–4.5)	0.0–3.0
Chloride (mmol/L)	129 (123–137)	115–127
Phosphorus (mg/dl)	5.13 (2.95–6.74)	2.14–3.66
Calcium (mg/dl)	6.5 (4.99–8.73)	8.97–10.83
AST (mmol/L)	274.5 (66–618)	117–281
Total protein (g/dl)	2.2 (1.2–4.4)	2.0–5.0
Uric acid (mg/dl)	16.57 (2.45–32.64)	0.68–7.52
BUN (mg/dl)	8.7 (1.1–19.1)	0.1–3.0
Creatinine (mg/dl)	0.38 (0.17–0.41)	0.21–1.25
Albumin (g/dl)	0.67 (0.37–1.53)	0.72–1.48
CPK (IU/L)	122 (6–337)	0–1018

^a P. T. Redig, unpublished data.

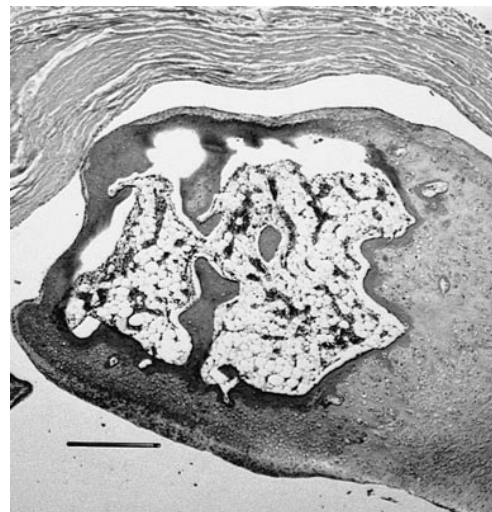


FIGURE 2. There is a chondro-osseous mass within a synovial sheath. The osseous portion (center) is surrounded by cartilage. H&E stain, scapulo-humeral joint. Bar = 0.5 mm.

etiology. The observed hyperchloremia, hyperphosphatemia, hyperkalemia, hyperuricemia, uremia, and hypoalbuminemia were consistent with starvation, dehydration, and prerenal azotemia (Hochleithner, 1994; Duncan et al., 1994). There was no suspicion of gout, based on normal kidney histopathology in the eight birds examined.

Two great horned owls with similar lesions were observed at this clinic in 1992, but the details of their cases were incomplete. No confirmed cases were observed previous to 1992, however during the first 12 yr of this clinic's operation (1980–1992), fewer birds were admitted or routinely radiographed than at present. The finding of only one affected red-tailed hawk is surprising, as equal numbers of each species are admitted to the clinic yearly.

We owe a special thanks to D. A. Carr, J. E. Collins, T. P. O'Leary, and D. P. Shaw for their histopathologic interpretations, K. D. Russow for assistance with photomicrographs, and L. Degernes for her thoughtful critique of the original manuscript.

LITERATURE CITED

- ARAYA, O., F. WITTWER, A. VILLA, AND C. DUCOM. 1990. Bovine fluorosis following volcanic activity in the southern Andes. *Veterinary Record* 126: 641–642.
- BOTHA, C. J., T. W. NAUDE, P. P. MINNAAR, S. R. VANAMSTEL, AND S. D. J. VANRENSBURG. 1993. Two outbreaks of fluorosis in cattle and sheep. *Journal of the South African Veterinary Association* 64: 165–168.
- CAMPBELL, T. W. 1994. Hematology. *In Avian medicine: Principles and application*, B. W. Ritchie and G. J. Harrison (eds.). Wingers Publications, Inc., Lake Worth, Florida, pp. 176–198.
- CHRISTIANSEN, W. G., AND WIIG, H. 1991. What is the diagnosis? Exostoses with ankylosis in the cervical vertebrae and shoulder of a cat: Hypervitaminosis A. *Norsk Veterinaertidsskrift* 103: 49–50.
- DUNCAN, J. R., K. W. PRASSE, AND E. A. MAHAFFEY. 1994. *Veterinary laboratory medicine: Clinical pathology*. Iowa State University Press, Ames, Iowa, 300 pp.
- FLO, G. L., R. L. STICKLE, AND R. W. DUNSTAN. 1987. Synovial chondrometaplasia in five dogs. *Journal of the American Veterinary Medical Association* 191: 1417–1422.
- HOCHLEITHNER, M. 1994. Biochemistries. *In Avian medicine: Principles and application*, B. W. Ritchie and G. J. Harrison (eds.). Wingers Publications, Inc., Lake Worth, Florida, pp. 224–245.
- HOWARD, M. O., M. A. NIEVES, AND K. G. MILES. 1996. Synovial chondromatosis in a great horned owl (*Bubo virginianus*). *Journal of Wildlife Diseases* 32: 370–372.
- POOL, R. 1990. Joints and adjacent soft tissues. *In Tumors in domestic animals*, 3rd Edition. J. E. Moulton (ed.). University of California Press, Berkeley, California, pp. 102–156.

Received for publication 22 April 1998.