



## **Peritoneal Coccidioidomycosis in a Mountain Lion in California**

Author: Adaska, John M.

Source: Journal of Wildlife Diseases, 35(1) : 75-77

Published By: Wildlife Disease Association

URL: <https://doi.org/10.7589/0090-3558-35.1.75>

---

BioOne Complete ([complete.BioOne.org](https://complete.BioOne.org)) is a full-text database of 200 subscribed and open-access titles in the biological, ecological, and environmental sciences published by nonprofit societies, associations, museums, institutions, and presses.

Your use of this PDF, the BioOne Complete website, and all posted and associated content indicates your acceptance of BioOne's Terms of Use, available at [www.bioone.org/terms-of-use](https://www.bioone.org/terms-of-use).

Usage of BioOne Complete content is strictly limited to personal, educational, and non - commercial use. Commercial inquiries or rights and permissions requests should be directed to the individual publisher as copyright holder.

---

BioOne sees sustainable scholarly publishing as an inherently collaborative enterprise connecting authors, nonprofit publishers, academic institutions, research libraries, and research funders in the common goal of maximizing access to critical research.

## Peritoneal Coccidioidomycosis in a Mountain Lion in California

John M. Adaska, California Veterinary Diagnostic Laboratory System-Tulare, 18830 Road 112, Tulare, California 93274, USA

**ABSTRACT:** An adult mountain lion (*Felis concolor*) from the vicinity of Weldon, California (USA) was necropsied following euthanasia due to emaciation and proximity to semi-rural housing. There were spherules consistent with *Coccidioides immitis* within peritoneal surfaces with granulomatous inflammation and fungi consistent with *C. immitis* were cultured from abdominal fluid. This is the first reported case of coccidioidomycosis in a wild mountain lion.

**Key words:** Case report, *Coccidioides immitis*, coccidioidomycosis, *Felis concolor*, mountain lion.

*Coccidioides immitis* is a dimorphic fungus which inhabits the lower Sonoran life zone, prominently including Kern and Tulare counties in the San Joaquin Valley (California, USA) (Rippon, 1988). While the fungus normally inhabits the soil, under proper conditions it produces and releases arthrospores (Rippon, 1988). If these arthrospores are inhaled by a susceptible individual, infection and disease known as Valley Fever or coccidioidomycosis may result (Rippon, 1988). Coccidioidomycosis can have a variety of clinical presentations which range from asymptomatic to the much less common extreme of disseminated disease with fungal organisms found in several organs (Rippon, 1988). Factors which lead to dissemination of the infection are not entirely defined, but they are likely to include concurrent disease (Pappagianis, 1988) and genetically-based variation in cell-mediated immunity (Magee and Cox, 1996). The life-stage occurring in tissues is the spherule within which there are endospores (Davis, 1981). The type of immunologic response directed against the organism is largely related to the phase of *C. immitis* involved. In tissues, inhaled arthrospores incite a response which consists primarily of neutrophils with fewer macrophages and lymphocytes. If this initial response does not clear the infection, the organisms trans-

form to spherules with an associated granulomatous response. The organism multiplies when individual spherules release endospores into the surrounding tissues and the endospores then mature into spherules. The released endospores prompt a polymorphonuclear cell response similar to that seen in the initial infection (Dungworth, 1993, Rippon, 1988). The organs most commonly involved in cases of disseminated disease in humans and dogs include the lung, lymph nodes, spleen, kidney and bone (Pappagianis, 1988, Timoney et al., 1988). Coccidioidomycosis has been diagnosed in a variety of non-domestic species including but not limited to several species of non-human primates, armadillo (*Oryzomys afer*), badger (*Meles meles*), cheetah (*Acinonyx jubatus*), coyote (*Canis latrans*), kit fox (*Vulpes macrotis mutica*), and tiger (*Panthera tigris*) (Pappagianis, 1988; Reed, 1985). Most cases reported in non-domestic species have occurred in animals housed in zoological collections (Pappagianis, 1988). This report describes a case of coccidioidomycosis in a free-ranging mountain lion (*Felis concolor*).

In July 1997 an adult male mountain lion was submitted to the Tulare branch of the California Veterinary Diagnostic Laboratory System (Tulare, California). The animal had originally been seen sleeping under a tree in the yard of a private home in a semi-rural river valley (Kern County, California; 35°42'N, 118°19'W). The district office of the California Department of Fish and Game (Fresno, California) was called by private citizens due to concern for humans and pets in the area. When fish and game officers arrived they noted that the animal was reluctant to move even when approached to within a few feet by a truck. In addition the animal was markedly thin and weak. The animal rose only

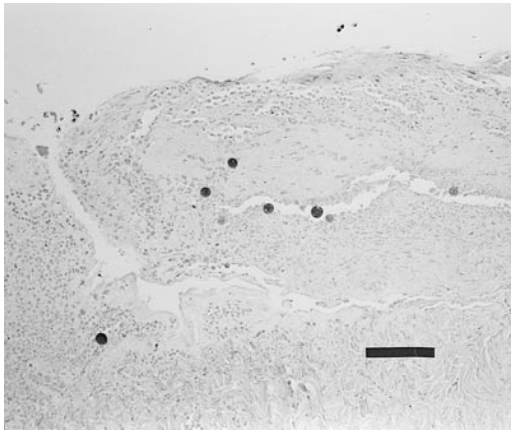


FIGURE 1. Several *Coccidioides immitis* spherules entrapped in the granulomatous connective tissue on the posterior surface of the diaphragm of a mountain lion from California. Note the good visualization of the spherules despite the autolyzed state of the tissue. H&E stain. Bar = 120  $\mu$ m.

with marked coxing and had rear limb instability. There had been recent cases of plague (*Yersinia pestis*) in coyotes in the area. Because the mountain lion was in poor condition and concerns that it might be infected with *Y. pestis*, it was shot in the thorax at close range with a shotgun. The carcass was taken to a fish hatchery where it was kept in a walk in refrigerated cooler overnight and then transported to the diagnostic lab the next day.

On post-mortem examination, the carcass weighed 37.2 kg, had a body length of 1.38 m, and was estimated to be 4-yr-old based on body length, interdental measurements and tooth wear patterns (P. Swift, pers. comm.). The carcass was markedly thin with marked prominence of the scapulae, the spinous processes of the vertebrae, the pelvic tuberosities, and the femurs. There also was moderate dehydration as evidenced by moderately sunken eyes and diminished skin turgor.

There was no evident perirenal or epicardial adipose tissue and the bone marrow had serous atrophy of fat. The left kidney had a single approximately 3 cm long and 2 cm wide irregular area of chronic infarction characterized by a depressed cortical surface and a pale wedge shaped

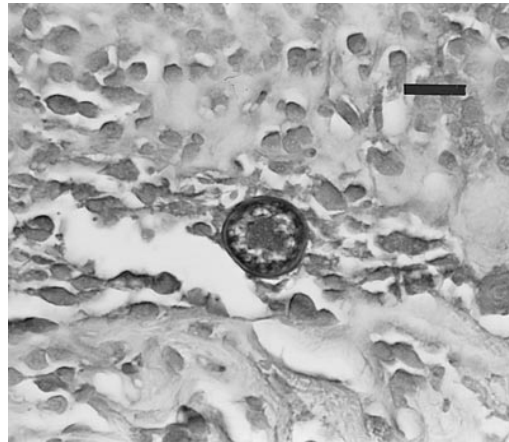


FIGURE 2. Single *Coccidioides immitis* spherule within the spleen of a mountain lion from California. Periodic Acid Schiff stain. Bar = 20  $\mu$ m.

area on cut section with its base at the sunken cortical surface and its apex at the corticomedullary junction. The peritoneal cavity contained approximately 1 l of red/brown cloudy fluid. The peritoneal surface of the diaphragm and the serosal surface of the stomach and spleen had a dull, slightly rough or fine granular appearance. There were numerous gun shot related injuries. The carcass had marked autolysis which was attributed to long periods of transportation at high ambient temperatures (approximately 38 C).

The marked autolysis of the carcass complicated the histological examination of the tissues but important findings included an irregular layer of granulomatous connective tissue on the peritoneal surface of the diaphragm and the serosal surface of the stomach and spleen within which there were scattered fungal spherules which were consistent with *C. immitis* (Fig. 1). Small numbers of spherules also were noted within abdominal lymph nodes. The spherules were 20 to 50  $\mu$ m in diameter, had a thick, double-layered, PAS (Sheehan and Hrapchak, 1980) positive wall and often contained endospores which were 3 to 5  $\mu$ m in diameter (Fig. 2). Bacterial culture of the peritoneal fluid on blood agar (Remel, Lenexa, Kansas, USA) resulted in the rapid growth of ir-

regular cottony colonies with a dull surface which were considered consistent with *C. immitis*. Because the histologic appearance of the organisms described within tissues was considered definitive, and given the highly infectious nature of the fungal phase of *C. immitis* (Walsh et al., 1995), and concerns over exposure and safety of laboratory personnel, the cultured fungi were not examined microscopically.

This report appears to be the first case of coccidioidomycosis in a free-ranging mountain lion. The overall poor condition of the animal as indicated by the emaciated state is consistent with a chronic disease course. In humans, underlying or co-occurring diseases and conditions, such as HIV infection, diabetes and pregnancy may promote the dissemination of the fungus (Pappagianis, 1988). In this case there was no indication of an underlying or associated disease but the condition of the carcass and the tissues would have made all but the most severe disease process difficult to diagnose. Fortunately, the fungal spherules noted within the tissues were still intact and were characteristic and diagnostic and the fungi grown from the peritoneal fluid also were consistent with *Coccidioides immitis*. Although there is a very high prevalence of infection with *C. immitis* in wild rodents in endemic areas, predation on these animals is not a typical route of infection (Rippon, 1988). Therefore, the route of initial infection of the mountain lion in this report was almost certainly by inhalation of arthrospores. The tissue spherules are generally considered to be of minimal infectivity due to the low likelihood of aerosolization and inhalation of the spherules. Therefore, working with an infected animal is not considered to pose a significant zoonotic threat, this is

provided the animal has not been dead long enough to allow the spherules to grow mycelia and arthrospores to form. Under laboratory conditions, this process takes 3 to 4 days from spherule stage to the formation of a typical mold (Davis, 1981).

#### LITERATURE CITED

- DAVIS, J. W. 1981. Coccidioidomycosis. In *Infectious disease of wild mammals*. 2nd ed., J. W. Davis, L. H. Karstad, and D. O. Trainer (eds.). The Iowa State University Press. Ames, Iowa, pp. 361–365.
- DUNGWORTH, D. L. 1993. The respiratory system. In *Pathology of domestic animals*, Vol. 2, 4th Edition. K. V. F. Jubb, P. C. Kennedy and N. Palmer (eds.). Academic Press, San Diego, California, pp. 668–672.
- MAGEE, D. M., AND R. A. COX. 1996. Interleukin-12 regulation of host defenses against *Coccidioides immitis*. *Infection and Immunity* 64: 3609–3613.
- PAPPAGIANIS, D. 1988. Epidemiology of Coccidioidomycosis. *Current Topics in Medical Mycology* 2: 199–238.
- REED, R. E., E. J. BICKNELL, AND H. B. HOOD. 1985. A thirty year record of coccidioidomycosis in exotic pets and zoo animals in Arizona. In *Coccidioidomycosis*. H. E. Einstein and A. Cantanzaro (eds.). National Institute for Infectious Diseases, Washington D.C., pp. 275–281.
- RIPPON, J. W. 1988. *Medical mycology*. 3rd ed., WB Saunders company, Philadelphia, Pennsylvania, 797 pp.
- SHEEHAN, D. C., AND B. B. HRAPCHAK. 1980. Theory and practice of histotechnology. 2nd Edition. Battelle Press, Columbus, Ohio, 481 pp.
- TIMONEY, J. F., J. H. GILLESPIE, F. W. SCOTT, AND J. E. BARLOUGH. 1988. The systemic mycoses. In *Hagan and Bruner's microbiology and infectious diseases of domestic animals*. 8th Edition. J. F. Timoney, J. H. Gillespie, F. W. Scott, and J. E. Barlough (eds.). Comstock Publishing Associates. Ithaca, New York, pp. 397–403.
- WALSH, T. J., T. G. MITCHELL, AND D. H. LARONE. 1995. Histoplasma, Blastomyces, Coccidioides and other dimorphic fungi causing systemic mycoses. In *Manual of clinical microbiology*. 6th ed., P. R. Murray (ed.). ASM Press. Washington, D.C., pp. 749–764.

*Received for publication 14 January 1998.*