A Possible New Piroplasm in Lions from the Republic of South Africa

Authors: Lopez-Rebollar, L. M., Penzhorn, B. L., de Waal, D. T., and Lewis, B. D.

Source: Journal of Wildlife Diseases, 35(1) : 82-85

Published By: Wildlife Disease Association

URL: https://doi.org/10.7589/0090-3558-35.1.82

Journal of Wildlife Diseases, 35(1), 1999, pp. 82–85

A Possible New Piroplasm in Lions from the Republic of South Africa

L. M. Lopez-Rebollar,[1,3] B. L. Penzhorn,[2] D. T. de Waal,[1] and B. D. Lewis,[2] [1] Parasitology Division, Onderstepoort Veterinary Institute, Private Bag X05, 0110 Onderstepoort, Republic of South Africa; [2] Department of Veterinary Tropical Diseases, Faculty of Veterinary Science, University of Pretoria, Private Bag X04, 0110 Onderstepoort, Republic of South Africa; [3] Corresponding author (e-mail: laura@moon.ovi.ac.za)

ABSTRACT: A small piroplasm was detected in blood smears from lions (*Panthera leo*) in the Kruger National Park (KNP; Republic of South Africa) during 1991/1992. The parasite was identified provisionally as *Babesia felis,* but sera from these lions tested negative to *B. felis* antigen in the indirect immunofluorescent antibody test (IFAT). Blood from an infected lion was subsequently subinoculated into a domestic cat and two leopards in an attempt to identify the parasite. A lion also was infected with *B. felis* (from a cat). Serum samples collected from these animals were tested against *B. felis,* the KNP small piroplasm, and *Cytauxzoon felis* antigen in the IFAT. The serological results indicate that the KNP small piroplasm isolated from the lion is probably a distinct species from *B. felis* and *C. felis.*

Key words: *Babesia* sp., lion, new species, *Panthera leo.*

The occurrence of babesiosis in wild and domestic felids was first reported by Lingard and Jennings in 1904 (as cited by Mangrulkar, 1937). These piroplasms are *Babesia cati* (Mudaliar et al., 1950) from a wild cat (*Felis silvestris*), *Babesia felis* (Davis, 1929; Jackson and Dunning, 1937; Robinson, 1963; Dennig, 1969) from a wild (*Felis ocreata*) and domestic cat (*Felis silvestris*), *Babesia herpailuri* (Dennig, 1967) from a jaguarundi (*Herpailurus yaguarondi*), and *Babesia pantherae* (Dennig and Brocklesby, 1972) from the leopard (*Panthera pardus*). Other undescribed *Babesia* spp. have been reported in "bay lynx" (probably the bobcat *Lynx rufus*) (Wenyon and Hamerton, 1930), mountain lion *Felis concolor* (Futter and Belonje, 1980), cheetah *Acinonyx jubatus* (Averbeck et al., 1990) and domestic cat (Stewart et al., 1980). *Cytauxzoon felis* was described from domestic cats (Wagner, 1975, 1976; Glenn and Stair, 1984) and bobcat (Glenn et al., 1982, 1983), and *Cytauxzoon*-like organisms also have been reported from two cheetahs (Zinkl et al., 1981). Except for *B. herpailuri,* the intraerythrocytic piroplasms of these *Babesia* spp. and *Cytauxzoon* spp. are small (1–1.2 × 2.2–2.5 μm), pleomorphic, and difficult to differentiate morphologically.

Recently, small piroplasms were observed in all blood smears made from 47 lions (*Panthera leo*) in the Kruger National Park (KNP; Republic of South Africa, between 22°31′ to 25°31′S, 30°45′ to 32°00′E). Initially, this parasite was identified morphologically as *Babesia felis.* However, subsequent immunofluorescent antibody (IFA) testing of serum from other lions in the KNP using *B. felis* and *C. felis* antigen all gave negative results.

Blood from 16 lions in the KNP collected in 20% acid citrate dextrose (ACD) was used to prepare stabilates and it was cryopreserved with 20% DMSO in phosphate buffered saline (PBS). Blood smears and serum were collected from the same lions. Serum was stored at −20 C until tested.

A domestic cat (bred and kept under strict tick-free conditions) and splenectomized after infection, one lion, and two leopards were used in this experiment and kept at the Onderstepoort Veterinary Institute (OVI, Onderstepoort, Republic of South Africa). Two ml of the thawed blood stabilate from KNP lions was injected intravenously (i.v.) to infect the cat and the two leopards. The lion was infected i.v. with two ml of OVI *B. felis* blood stabilate (Potgieter, 1981).

Thick and thin blood smears were made daily from the cat, and at monthly intervals from the lion and leopards. Thin blood smears were fixed in methanol, stained

with Giemsa's stain and examined with a 100× oil immersion lens. Rectal temperatures were taken daily between 08:00 and 10:00 a.m. Serum samples were collected at monthly intervals.

Antigen slides were prepared as described by Morzaria et al. (1977) from blood from the infected cat. *C. felis* antigen slides and positive control sera were obtained from F. Jongejan (Department of Infectious Diseases and Immunology, University of Utrecht, Utrecht, The Netherlands). *Babesia felis* antigen slides, and positive control serums were obtained from the Protozoology Division (OVI). Negative control serum was obtained from a cat bred under tick-free conditions.

Two-fold dilutions of the test serum were done in PBS. Commercial rabbit anti-cat immunoglobulin G conjugated with fluorescein isothiocyanate (BioMakor bm, Rehovot, Israel) was used at a 1:80 dilution. Slides were examined under a fluorescent microscope (Orthoplan, Leitz, Wetzlar, Germany) using a 50× water objective. A Videoplan semi-automatic image analyzer (Kontron Bildanalyse GmbH, Munich, Germany), was used to measure 30 parasites (length and width) from the experimentally infected cat.

None of the 16 KNP lions had antibody titres to *B. felis* or *C. felis.* Seven had small piroplasms in the blood smears, as well as antibody titres to the KNP small piroplasm; four and three had reciprocal titres of 40 and 80 respectively. The cat blood smears remained negative for 42 days after infection, at which time the cat was splenectomized. Parasites appeared in blood smears 8 days later. The parasitaemia fluctuated over a period of 1,094 days with the highest, 45%, recorded 30 days after splenectomy. The only clinical sign observed in the cat during this period was a slight anemia, indicated by the large number of immature red blood cells in the blood smear. Habitus, appetite, and temperature remained within normal limits. On Day 17 after splenectomy, when the parasitaemia was 2%, blood was collected for the preparation of IFA slides and blood stabilate. No *B. felis* were observed in blood smears of the experimentally-infected lion during the period of observation. However, antibodies against *B. felis* were demonstrated in the IFA test; reciprocal titres were 80, 160, 320 and 160 on each month after infection respectively. KNP small piroplasms were observed in blood smears prepared from one leopard, only on Day 60 after infection; serological titres against this parasite were demonstrated from Day 60 onwards. Titres were 160, 320 and 160, respectively in subsequent months. No clinical signs of disease were observed. Inexplicably, the other leopard remained blood smear and serologically negative throughout the observation period.

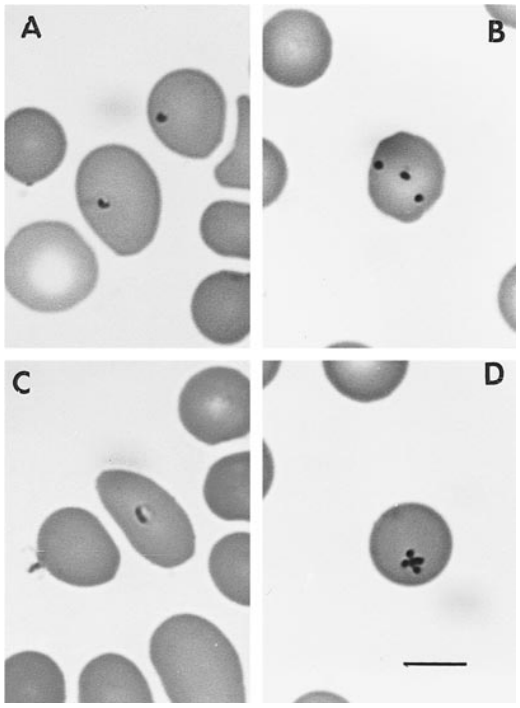

FIGURE 1. Giemsa-stained blood smears of the small Kruger National Park piroplasm from an experimentally infected domestic cat. Shown are single forms (A, C), three parasites in one erythrocyte (B), and a maltese cross (D). Bar = 10 μm.

The morphology of the piroplasms appeared to be the same in the naturally infected lions and experimentally infected cat and leopards. The piroplasms mostly

TABLE 1. Comparison of the Kruger National Park small piroplasm from lions and other *Babesia* spp. of felids.

	KNP small piroplasm[a]	*Babesia herpailuri*[b]	*B. pantherae*[c]	*B. cati*[d]	*B. felis*[b]	*C. felis*[e]
Length μm (mean)	1.05	2.7	2.0	2.5–0.5	0.9	1–1.2
Width μm (mean)	1.0	2.2	1.8	ND[f]	0.7	ND
Position[g]	Central	Central	Periphery	ND	Central	Central

[a] KNP = Kruger National Park.
[b] Dennig (1967).
[c] Dennig and Blocklesby (1972).
[d] Mudaliar et al. (1950).
[e] Wagner (1976).
[f] ND = Not done.
[g] Within erythrocyte.

appeared to be round, with the nucleus situated on the periphery. Single forms were usually situated at the center of the erythrocyte. Extra-cellular forms were rarely seen. Dividing forms (Maltese crosses) also were sometimes observed (Fig. 1). Single forms varied from 0.63 μm to 1.73 μm ($\bar{x} \pm SD = 1.05 \pm 0.22$ μm) in length and from 0.62 μm to 1.30 μm ($\bar{x} \pm SD = 1.0 \pm 0.14$ μm) wide (Table 1).

An original lion blood smear (from KNP) (PS-OVI 6162) and a representative cat blood smear (PS-OVI 6163) were deposited in the Protozoology Division of the Onderstepoort Veterinary Institute (Onderstepoort, Republic of South Africa.).

Based on these observations, we believe this piroplasm which is infective for lion, leopards, and cats may be a new species. The parasite is morphologically similar to *B. felis* and *C. felis,* but antigenically distinct. DNA sequencing of *B. felis* and the KNP isolate are under way.

We thank L. M. Booth for field collection of some of the material and assistance during the trials, D. G. A. Meltzer for immobilizing the large cats, the photography section at the O. V. I. for the photographs, and J. B. Walker and P. A. Conrad for their comments on the manuscript. The lion and leopards used in the trials were kept by the late A. Verster for cestode research.

LITERATURE CITED

AVERBECK, G. A., K. E. BJORK, C. PACKER, AND L. HERBST. 1990. Prevalence of hematozoans in lions (*Panthera leo*) and cheetah (*Acinonyx jubatus*) in Serengeti National Park and Ngorongoro Crater, Tanzania. Journal of Wildlife Diseases 26: 392–394.

DAVIS, L. J. 1929. On a piroplasm of the Sudanese wild cat (*Felis ocreata*). Transactions of the Royal Society of Tropical Medicine and Hygiene 22: 523–534.

DENNIG, H. K. 1967. Eine unbekannte Babesienart beim Jaguarundi (*Herpailurus yaguarondi*). Kleintierpraxis 12: 146–152.

———. 1969. Babesieninfektionen bei exotischen Katzen und die Bedeutung dieser Blutparasiten für die tierärztliche Forschung. Acta Zologica et Pathologica Antverpiensia 48: 361–367.

———, AND D. W. BROCKLESBY. 1972. *Babesia pantherae* sp. nov., a piroplasm of the leopard (*Panthera pardus*). Parasitology 64: 525–532.

FUTTER, G. J., AND P. C. BELONJE. 1980. Studies on feline babesiosis 1. Historial review. Journal of the South African Veterinary Association 50: 105–106.

GLENN, B. L., R. E. ROLLEY, AND A. A. KOCAN. 1982. *Cytauxzoon*-like piroplasms in erythrocytes of wild-trapped bobcats in Oklahoma. Journal of the American Veterinary Medical Association 181: 1251–1253.

———, A. A. KOCAN, AND E. F. BLOUIN. 1983. Cytauxzoonosis in bobcats. Journal of the American Veterinary Medical Association 183: 1155–1158.

———, AND E. L. STAIR. 1984. Cytauxzoonosis in domestic cats: Report of two cases in Oklahoma, with a review and discussion of the disease. Journal of the American Veterinary Medical Association 184: 822–825.

JACKSON, C., AND F. J. DUNNING. 1937. Biliary fever (Nuttalliosis) of the cat: A case in the Stellenbosch District. Journal of the South African Veterinary Medical Association 8: 83–88.

MANGRULKAR, M. Y. 1937. On a piroplasm of the Indian cat (*Felis domesticus*). The Indian Journal of Veterinary Research and Animal Husbandry 7: 243–246.

MORZARIA, S. P., D. W. BROCKLESBY, AND D. F. HARRADINE. 1977. Evaluation of the indirect fluorescent antibody test for *Babesia major* and *Theileria mutans* in Britain. The Veterinary Record 100: 484–487.

MUDALIAR, S. V., G. R. ACHARY, AND V. S. ALWAR. 1950. On a species of *Babesia* in an Indian wild cat (*Felis catus*). The Indian Veterinary Journal 26: 391–395.

POTGIETER, F. T. 1981. Chemotherapy of *Babesia felis* infection: Efficacy of certain drugs. Journal of the South African Veterinary Association 52: 289–293.

ROBINSON, E. M. 1963. Biliary fever (nuttaliosis) in the cat. Journal of the South African Veterinary Medical Association 34: 45–47.

STEWART, C. G., K. J. W. HACKETT, AND M. G. COLLET. 1980. An unidentified *Babesia* of the domestic cat (*Felis domesticus*). Journal of the South African Veterinary Association 51: 219–221.

WAGNER, J. E. 1975. Cytauxzonosis in domestic cats (*Felis domesticus*) in Missouri. Journal of the American Veterinary Medical Association 167: 874.

———. 1976. A fatal Cytauxzoonosis-like disease in cats. Journal of the American Veterinary Medical Association 168: 585–588.

WENYON, C. M., AND A. E. HAMERTON. 1930. Piroplasms of the West African civet cat (*Viverra civetta*) and the Bay Lynx (*Felis rufa*) of North America. Transactions of the Royal Society of Tropical Medicine and Hygiene 24: 7–8.

ZINKL, J. G., S. E. MCDONALD, A. W. KIER, S. CIPPA, AND P. J. SMALL. 1981. *Cytauxzoon*-like organisms in erythrocytes of two cheetahs. Journal of the American Veterinary Medical Association 179: 1261–1262.

Received for publication 16 October 1997.