

DEVELOPMENT OF A MODEL OF NATURAL INFECTION WITH MYCOBACTERIUM BOVIS IN WHITE-TAILED DEER

Authors: Mitchell V. Palmer, Diana L. Whipple, and Steven C. Olsen

Source: Journal of Wildlife Diseases, 35(3) : 450-457

Published By: Wildlife Disease Association

URL: <https://doi.org/10.7589/0090-3558-35.3.450>

BioOne Complete (complete.BioOne.org) is a full-text database of 200 subscribed and open-access titles in the biological, ecological, and environmental sciences published by nonprofit societies, associations, museums, institutions, and presses.

Your use of this PDF, the BioOne Complete website, and all posted and associated content indicates your acceptance of BioOne's Terms of Use, available at www.bioone.org/terms-of-use.

Usage of BioOne Complete content is strictly limited to personal, educational, and non-commercial use. Commercial inquiries or rights and permissions requests should be directed to the individual publisher as copyright holder.

BioOne sees sustainable scholarly publishing as an inherently collaborative enterprise connecting authors, nonprofit publishers, academic institutions, research libraries, and research funders in the common goal of maximizing access to critical research.

DEVELOPMENT OF A MODEL OF NATURAL INFECTION WITH *MYCOBACTERIUM BOVIS* IN WHITE-TAILED DEER

Mitchell V. Palmer,^{1,2} Diana L. Whipple,¹ and Steven C. Olsen¹

¹ Zoonotic Diseases Research Unit, National Animal Disease Center, Agricultural Research Service, USDA, 2300 Dayton Rd., Ames, Iowa 50010

² Corresponding author (e-mail: mpalmer@nadc.ars.usda.gov)

ABSTRACT: The objective of this study was to develop a suitable experimental model of natural *Mycobacterium bovis* infection in white-tailed deer (*Odocoileus virginianus*), describe the distribution and character of tuberculous lesions, and to examine possible routes of disease transmission. In October 1997, 10 mature female white-tailed deer were inoculated by intratonsillar instillation of 2×10^3 (low dose) or 2×10^5 (high dose) colony forming units (CFU) of *M. bovis*. In January 1998, deer were euthanatized, examined, and tissues were collected 84 to 87 days post inoculation. Possible routes of disease transmission were evaluated by culture of nasal, oral, tonsillar, and rectal swabs at various times during the study. Gross and microscopic lesions consistent with tuberculosis were most commonly seen in medial retropharyngeal lymph nodes and lung in both dosage groups. Other tissues containing tuberculous lesions included tonsil, trachea, liver, and kidney as well as lateral retropharyngeal, mandibular, parotid, tracheobronchial, mediastinal, hepatic, mesenteric, superficial cervical, and iliac lymph nodes. *Mycobacterium bovis* was isolated from tonsillar swabs from 8 of 9 deer from both dosage groups at least once 14 to 87 days after inoculation. *Mycobacterium bovis* was isolated from oral swabs 63 and 80 days after inoculation from one of three deer in the low dose group and none of four deer in the high dose group. Similarly, *M. bovis* was isolated from nasal swabs 80 and 85 days after inoculation in one of three deer from the low dose group and 63 and 80 days after inoculation from two of four deer in the high dose group. Intratonsillar inoculation with *M. bovis* results in lesions similar to those seen in naturally infected white-tailed deer; therefore, it represents a suitable model of natural infection. These results also indicate that *M. bovis* persists in tonsillar crypts for prolonged periods and can be shed in saliva and nasal secretions. These infected fluids represent a likely route of disease transmission to other animals or humans.

Key words: *Mycobacterium bovis*, *Odocoileus virginianus*, pathology, transmission, tuberculosis, white-tailed deer.

INTRODUCTION

Tuberculosis in free-ranging white-tailed deer (*Odocoileus virginianus*) was first recognized in the United States in 1934 when two wild white-tailed deer infected with *Mycobacterium bovis* were described as having pulmonary and thoracic lymph node lesions indistinguishable from those seen in cattle (Levine, 1934). It was suggested that cattle were the source of infection for these two wild deer, and that no reservoir of *M. bovis* infection existed in free-ranging white-tailed deer.

In 1994, a white-tailed deer in Alpena County (Michigan, USA) killed by a hunter, was found to have gross and microscopic lesions consistent with *M. bovis* (Schmitt et al., 1997). This prompted a survey in Michigan in 1995 and 1996 which resulted in isolation of *M. bovis* from 12 of 354 deer. As of 1 October 1998,

over 8,800 deer from the affected area of Michigan have been tested and 151 (1.7%) have been diagnosed as positive for *M. bovis*. With over 19 million white-tailed deer, 5 million mule and black-tailed deer (*Odocoileus hemionus*), and 750,000 wapiti (*Cervus elaphus*) in the continental United States (Hunter, 1996), a wild Cervidae reservoir of *M. bovis* would jeopardize the bovine tuberculosis eradication effort. Countries with wild animal reservoirs of *M. bovis*, such as New Zealand and Great Britain have been forced to adopt a bovine tuberculosis control effort rather than disease eradication.

To control or eradicate tuberculosis in cervids, a better understanding of the pathogenesis, transmission, and epidemiology will be critical. This study was designed to develop a suitable experimental model of natural *M. bovis* infection in

white-tailed deer, describe the distribution and character of tuberculous lesions, and to examine possible routes of disease transmission to other deer, domestic livestock, and humans.

MATERIALS AND METHODS

Ten, mature, female, white-tailed deer were obtained from a private whitetail breeder in Alpena County (Michigan, USA; 44°52'N, 83°51'W) and moved to the National Animal Disease Center in Ames (Iowa, USA; 42°03'N, 93°63'W) in September 1997. Throughout the experiment (October 1997 to January 1998), deer were housed according to dosage group in pens separated by concrete walls in a biosecurity level III building. Direct contact was not possible between deer in different dosage groups. Negative control deer ($n = 2$) were maintained in a single pen in a separate building. Prior to inoculation, and 81 days after inoculation, all deer were tested for exposure to *M. bovis* by the comparative cervical test (CCT) for Cervidae as described in USDA, APHIS, VS guidelines (United States Department of Agriculture, 1997). Briefly, hair was clipped from two sites on the right side of the midcervical region and the skin thickness of each site was measured. One-tenth ml of *M. avium* purified protein derivative (PPD) (0.4 mg/ml) was injected intradermally in the uppermost site and 0.1 ml of *M. bovis* PPD (1 mg/ml) was injected into the lower site. Injection sites were observed, palpated, and measured approximately 72 hours after injection. Results were interpreted by plotting measurements on a scattergram developed by USDA for interpretation of the CCT for Cervidae (United States Department of Agriculture, 1997). Results of the CCT were used to classify deer as negative, suspect, or reactor.

Deer were randomly assigned to one of three groups. The low dose group ($n = 4$) received 1×10^3 colony forming units (CFU) of *M. bovis* in 0.15 ml sterile saline solution (0.9% NaCl) instilled in each tonsillar crypt as described previously (Palmer et al., 1999), for a total dose of 2×10^3 CFU of *M. bovis* per deer. The high dose group ($n = 4$) received 1×10^5 CFU of *M. bovis* in sterile saline in each tonsillar crypt for a total dose of 2×10^5 CFU of *M. bovis*. Control deer received 0.15 ml of sterile saline in each tonsillar crypt.

For inoculation and sampling, deer were anesthetized with a combination of xylazine (Mobay Corporation, Shawnee, Kansas, USA) (2 mg/kg of body weight) and ketamine (Fort Dodge Laboratories, Fort Dodge, Iowa, USA)

(6 mg/kg) injected intramuscularly. After sampling, the effects of xylazine were reversed with tolazoline (Lloyd Laboratories, Shanandoah, Iowa, USA) (4 mg/kg) injected IV.

The strain of *M. bovis* used was strain 95-11328-1315, originally isolated from a free-ranging tuberculous white-tailed deer killed by a hunter in Alpena County, Michigan in 1994. The isolate was incubated at 37 C for 6 wk on Middlebrook's 7H9 liquid media with 10% oleic albumin dextrose citrate enrichment (Bacto Middlebrook OADC Enrichment, DIFCO Laboratories, Detroit, Michigan, USA). After incubation, the bacteria were harvested by centrifugation, and washed twice with 0.01 M phosphate buffered saline (PBS) solution, pH 7.4. After resuspension in PBS solution, serial 10-fold dilutions were inoculated on Middlebrook 7H10 agar slants supplemented with OADC to determine the number of CFU. Inoculum was then frozen at -80 C for future use.

Tonsillar, nasal, oral, and rectal swabs were collected for bacteriologic culture before inoculation and 7, 14, 21, 35, 50, 63, 80, and 84-87 days after inoculation. Nasal, oral, and rectal swabs for bacteriologic culture were collected using a 15 cm sterile cotton swab. Nasal swabs were obtained by inserting a separate swab in each nasal cavity to a depth of approximately 10 cm. Oral swabs were collected by passing the cotton swab over the sublingual oral cavity. Tonsillar swabs for bacteriologic culture were obtained with the aid of a laryngoscope and a sterile 18 cm cytology brush (Puritan Medical Products, Guilford, Maine, USA.) attached to the end of a 53 cm insemination pipette. Swabs were rinsed thoroughly in 1.0 ml PBS. One half of the sample (0.5 ml) was added to 0.2% benzalkonium chloride solution (Zephiran chloride, concentrate 17%, Sterling Drug Inc., New York, New York, USA) and let sit at room temperature for 15 min. After decontamination with benzalkonium chloride, samples were centrifuged for 20 min at 2,000 rpm and the supernatant decanted. To the sediment was added 0.5 ml of Bacto egg yolk enrichment 50% (DIFCO Laboratories, Detroit, Michigan, USA). Samples of the sediment-egg yolk combination were inoculated onto separate agar slants containing Stonebrinks, Harrold's egg yolk media, M7H10, or M7H11 media. Inoculated agar slants were incubated at 37 C for 8 wk.

Deer were euthanatized by IV injection of sodium pentobarbital (Sleepaway, Fort Dodge Laboratories, Fort Dodge, Iowa, USA). Specimens collected for bacteriologic culture included; tonsil, lung, liver, spleen, kidney, brain, mammary gland; and mandibular, parotid, me-

TABLE 1. Isolation of *Mycobacterium bovis* from nasal, oral, and tonsilar swabs collected from experimentally infected white-tailed deer.

Days after inoculation	Deer number							
	Low dose				High dose			
	3	7	8	10	1	2	5	6
7								
14	NA ^a						T	T
21	NA						T	
35	NA	T ^b	T			T	T	
50	NA	T	T			T	T	
63	NA	O ^c			N ^d		T	
80	NA	N, T, O			T	T	N, T	
84-87	NA	N, T				T	T	

^a NA = not available, deer died of aspiration pneumonia associated with anesthesia 14 days after inoculation.

^b T = *M. bovis* isolated from tonsilar swab.

^c O = *M. bovis* isolated from oral swab.

^d N = *M. bovis* isolated from nasal swab.

dial retropharyngeal, lateral retropharyngeal, superficial cervical, tracheobronchial, mediastinal, mesenteric, hepatic, iliac, supramammary, and prefemoral lymph nodes. Specimens for bacteriologic culture were placed individually in sterile bags and frozen at -80°C for approximately 2 wk before processing. Processing of specimens was done as described previously (Payeur et al., 1992). Results were considered positive if *M. bovis* was isolated.

Tissue samples for microscopic examination included those collected for bacteriologic culture and trachea and parietal pleura. Specimens were fixed in neutral buffered 10% formalin and processed by routine paraffin embedment techniques. Sections were cut 5- μm thick, stained with hematoxylin and eosin (H&E) and examined by light microscopy. Adjacent 5- μm sections were cut from specimens with tuberculous lesions and stained by the Ziehl-Neelsen technique for acid fast bacteria (Sheehan and Hrapchak, 1980) and the Brown and Brenn modified method of Gram staining for bacteria (Sheehan and Hrapchak, 1980).

RESULTS

Prior to inoculation with *M. bovis*, all but two deer had delayed type hypersensitivity (DTH) reactions which were considered negative for exposure to *M. bovis*. Deer 8 and 10, from the low dose group, had DTH reactions which plotted in the suspect zone using the scattergram for the CCT in Cervidae. Eighty-one days after inoculation, all *M. bovis*-inoculated deer had reactions which were considered pos-

itive for exposure to *M. bovis*. Additionally, control deer 9 had a reaction which was also considered positive for exposure to *M. bovis*. Control deer 4 remained negative for exposure to *M. bovis* as determined by the CCT.

Fourteen days after inoculation, deer 3 died of aspiration pneumonia associated with anesthesia. Therefore, results of swab specimens are not available beyond that point for deer 3 (Table 1). *Mycobacterium bovis* was isolated from tonsilar swabs as early as 14 days after inoculation in two deer from the high dose group, and 35 days after inoculation from two deer in the low dose group. In both groups, tonsilar swabs from at least one deer yielded *M. bovis* at the termination of the study. In addition to tonsilar swabs, oral swabs yielded *M. bovis* 63 and 80 days after inoculation from deer 7 of the low dose group. *Mycobacterium bovis* was not isolated from oral swabs from any deer in the high dose group. Swabs of the nasal cavity of deer 7 yielded *M. bovis* 80 and 87 days after inoculation, and from deer 1 and 5, in the high dose group, 63 and 80 days, respectively, after inoculation. At no time was *M. bovis* isolated from rectal swabs. *Mycobacterium bovis* was not isolated from nasal, oral, tonsilar or rectal swabs from control deer.

TABLE 2. Distribution of gross and microscopic lesions consistent with tuberculosis, and isolation of *M. bovis* from intratonsilarly infected white-tailed deer.

Tissue	Deer number							
	Low dose group				High dose group			
	3 ^a	7	8	10	1	2	5	6
Tonsil	B	M, B	M, B	B	—	M, G	M, G, B	M, G, B
Medial retropharyngeal LN ^b	B	M, G, B	M, G	M, G, B	—	M, G, B	M, G, B	M, G, B
Lateral retropharyngeal LN	—	M, G, B	—	—	—	—	M, B	M
Mandibular LN	—	M, B	—	—	—	—	M, B	—
Parotid LN	—	M, B	B	—	—	—	M, B	—
Tracheobronchial LN	—	M, G, B	—	—	—	—	M, G, B	—
Mediastinal LN	—	M, G, B	—	—	—	—	M, G, B	—
Lung	—	M, G, B	M, G, B	—	M, G, B	M, G	B	—
Parietal pleura ^c	—	M	—	—	—	—	—	—
Trachea ^c	—	M, G	—	—	—	—	M, G	—
Liver	—	M, G, B	—	—	—	—	M, G, B	—
Spleen	—	—	—	—	—	—	B	—
Hepatic LN	—	M, G, B	—	—	—	M	M, B	—
Mesenteric LN	—	M, G, B	M, B	—	—	M, G	M, G, B	—
Suprficial cervical LN	—	M, B	—	—	—	—	—	B
Iliac LN	—	M, B	—	—	—	M	—	—
Supramammary LN	—	—	—	—	—	M	—	—
Prefemoral LN	—	B	—	—	—	—	—	—
Kidney	—	M, G, B	—	—	—	—	—	—

^a Deer died of aspiration pneumonia associated with anesthesia 14 days after inoculation.

^b Lymph node.

^c Not processed for isolation of *M. bovis*. M = microscopic lesion(s) consistent with tuberculosis and acid fast bacteria seen. G = gross lesion(s) consistent with tuberculosis seen. B = isolation of *M. bovis*. — = no gross or microscopic lesion consistent with tuberculosis and *M. bovis* not isolated.

Mycobacterium bovis was isolated from at least one tissue from all *M. bovis*-inoculated deer (Table 2). Most commonly infected sites included the medial retropharyngeal lymph nodes and tonsils. Deer 1 from the high dose group had *M. bovis* only within the lung, while deer 2, also from the high dose group, had *M. bovis* only in the medial retropharyngeal lymph node. In contrast, deer 7, from the low dose group, had *M. bovis* in every tissue sampled except the spleen, brain, mammary gland and supramammary lymph nodes. Similarly, deer 5, from the high dose group, had *M. bovis* in all tissues examined except kidney, brain, mammary gland, and superficial cervical, iliac, supramammary, and prefemoral lymph nodes. *Mycobacterium bovis* was not isolated from any mammary glands, supramammary lymph nodes, or brain. A mycobacteria isolated from tracheobronchial lymph

nodes from control deer 9 was determined not be within the *M. tuberculosis* complex by DNA probe analysis (AccuProbe *Mycobacterium tuberculosis* complex, Gen-Probe Inc., San Diego, California, USA.). Biochemical tests identified this isolate as *M. gastri*. *Mycobacterium bovis* was not isolated from any tissue from control deer.

All *M. bovis*-inoculated deer developed lesions consistent with tuberculosis (Table 2). Although severity of lesions differed between individual animals, there was no difference in severity between low and high dose groups. Pulmonary lesions consisted of multifocal subpleural to deep, white, firm granulomas which ranged in size from 3 mm to 2 cm. Two patterns of pulmonary lesion distribution were noted. In deer 7, lesions were disseminated evenly throughout all lung lobes. In all other deer with pulmonary lesions, tuberculous

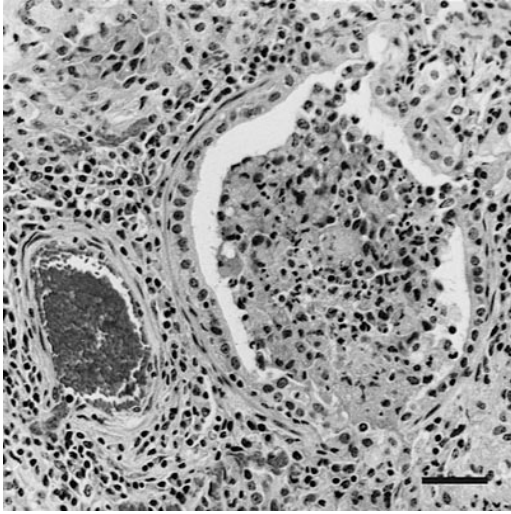


FIGURE 1. Section of lung from deer 7 inoculated intratonsillarly with 2×10^3 CFU of *M. bovis*. Macrophages and other inflammatory cells fill bronchiole lumen and surrounding alveolar spaces. H&E. Bar = 55 μ m.

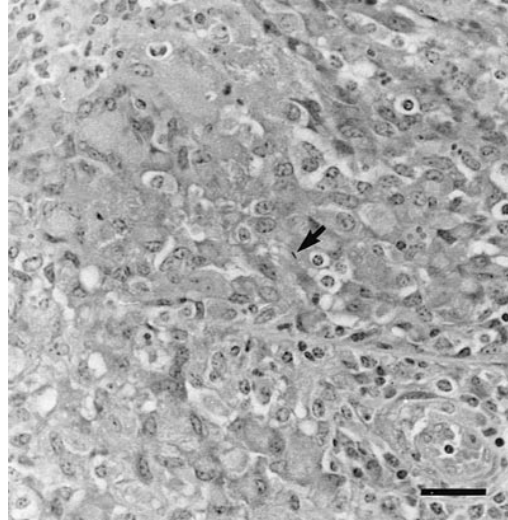


FIGURE 2. Section of lung from deer 7 inoculated intratonsillarly with 2×10^3 CFU of *M. bovis*. A single acid fast bacterium (arrow) is located within a macrophage. Macrophages and multinucleated giant cells fill bronchiolar lumen. Ziehl Neelsen. Bar = 35 μ m.

lesions were most numerous in the caudal lung lobes.

Lymphadenopathy of the medial retropharyngeal lymph nodes was seen in three of four deer in the low dose group and three of four deer in the high dose group. Enlarged retropharyngeal lymph nodes were firm, and on cut surface contained multifocal areas of purulent material as well as caseous necrosis. Medial retropharyngeal lymph nodes of deer 2 were severely enlarged and on cut surface contained abundant green, tenacious, purulent material, surrounded by a region of caseous necrosis. Grossly visible tonsillar lesions were seen in three of four deer in the high dose group. Affected tonsils were moderately enlarged and firm. On cut surface, tonsils contained multifocal areas of purulent exudate.

Lesions were seen in the proximal tracheas of deer 6 and 7. Posterior to the larynx, the proximal 4 to 5 cm of tracheal mucosa was covered with a fibrinopurulent exudate. Removal of the exudate revealed hyperemic and necrotic tracheal mucosa. Liver from deer 5, and liver and kidney

from deer 7 contained capsular, white, nodular lesions, 3 to 10 mm in size.

Microscopic lesions consistent with tuberculosis were seen in all organs in which grossly visible tuberculous lesions were noted. Additionally, microscopic tuberculous lesions were seen in supramammary, iliac, superficial cervical, parotid, and mandibular lymph nodes, and parietal pleura (Table 2). Microscopically, tuberculous lesions were similar regardless of location and were composed of central areas of caseous necrosis surrounded by numerous epithelioid and vacuolated macrophages, lymphocytes, and multinucleated giant cells. Few neutrophils were seen within granulomas. Ziehl-Neelsen staining of granulomas revealed low to moderate numbers of acid fast bacilli that were located within epithelioid macrophages, multinucleated giant cells, or free within the necrotic caseum.

In sections of lung from deer 7, alveolar and bronchiolar lumina were partially to completely filled with large vacuolated macrophages containing acid fast bacteria (Figs. 1, 2). Similarly, the proximal tracheal

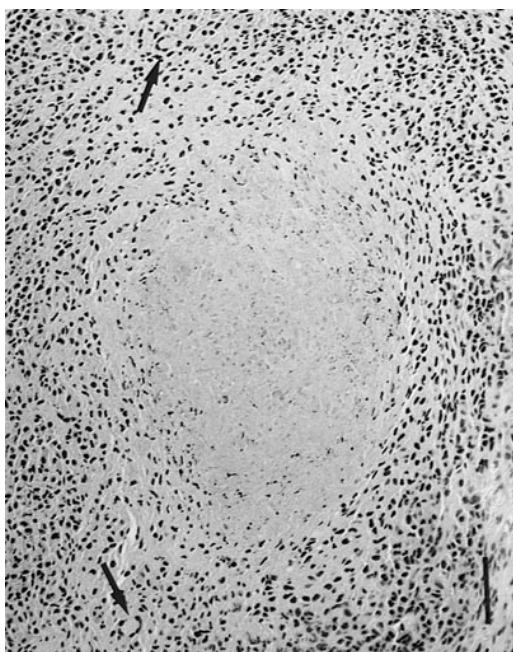


FIGURE 3. Section of trachea from deer 5 inoculated intratonsilarly with 2×10^5 CFU of *M. bovis*. Submucosal granuloma composed of epithelioid macrophages and multinucleated giant cells (arrows). H/E. Bar = 88 μ m.

lesions from deer 7 and 5 were composed of multifocal to coalescing caseonecrotic granulomas which expanded the tracheal submucosa. Necrotic mucosa was covered by a thick layer of caseous debris which contained numerous acid fast bacteria (Figs. 3, 4). Luminally, caseous debris was covered by a thin layer of purulent exudate and necrotic debris which contained a mixture of numerous gram positive cocci, coccobacilli, and bacilli. Lesions consistent with tuberculosis were not seen in brain or mammary gland from *M. bovis*-inoculated deer nor in any tissue examined from control deer.

DISCUSSION

Intratonsilar inoculation of white-tailed deer with *M. bovis* represents a suitable model of natural infection. The distribution and character of lesions are similar to those reported for naturally infected white-tailed deer with lymph nodes of the

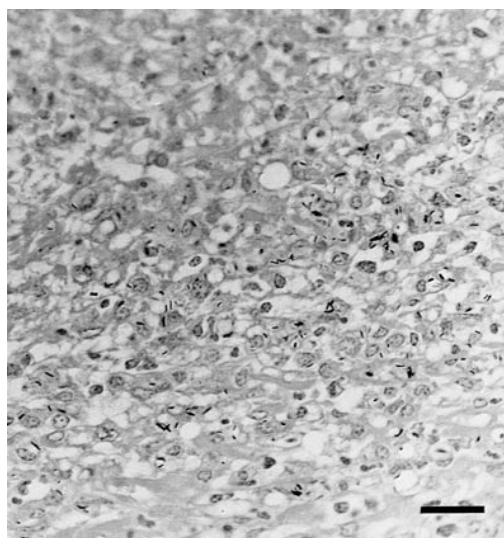


FIGURE 4. Section of trachea from deer 5 inoculated intratonsilarly with 2×10^5 CFU of *M. bovis*. Numerous acid fast bacteria in caseous exudate covering tracheal mucosa. Ziehl Neelsen. Bar = 35 μ m.

head, thoracic cavity, and lungs being most commonly affected (Schmitt et al., 1997). Similar to our findings, a previous study of naturally infected white-tailed deer found the medial retropharyngeal lymph node to be the most commonly involved of all lymph nodes of the head or thorax (Schmitt et al., 1997). Involvement of the medial retropharyngeal lymph node is likely the result of lymph drainage from the tonsil. In other ruminant species efferent lymphatics from the tonsil drain directly to the medial retropharyngeal lymph node (Saar and Getty, 1975). Mycobacteria present in the oropharynx or mouth through inhalation or ingestion would be processed by the tonsil and likely carried through lymphatic vessels to the medial retropharyngeal lymph node.

Intratonsilar inoculation has been used previously to create models of natural tuberculosis in red deer (*Cervus elaphus*) (Mackintosh et al., 1995), and cattle (Palmer et al., 1999). In all cases, lesion distribution and character have been similar to those seen in naturally infected animals. Microscopic lesions in our white-tailed deer were similar in character to

those seen in cattle. Variations seen in elk/red deer and fallow deer (*Dama dama*) such as increased neutrophils and scattered peripheral mineralization were not seen (Rhyan et al., 1995).

Pulmonary airways containing mycobacteria-laden inflammatory cells in deer 7, and tracheal exudate containing mycobacteria in deer 7 and 5 provide a likely source of *M. bovis* through aerosol as well as saliva and nasal secretions. The isolation of *M. bovis* from oral and nasal swabs from deer 7 is consistent with this route of transmission, moreover, contact with nasal mucus from infected animals has been shown to transmit *M. bovis* in cattle (Neill et al., 1989). Nose to nose contact or sharing of feeding sites may, therefore, facilitate deer to deer transmission. Supplemental feeding sites such as those described in northeastern Michigan (Schmitt et al., 1997) would serve to unnaturally increase deer density and increase the likelihood of contact with infected animals or feed contaminated with saliva or nasal mucus from infected animals. The results of this study suggest that in areas where *M. bovis* infection of white-tailed deer exist, management changes that decrease deer density or decrease contact between deer will decrease disease transmission.

Severe disseminated tuberculosis is not a prerequisite for the presence of *M. bovis* in saliva or nasal secretions. Deer 1 had only pulmonary lesions with no visible involvement of tonsils or lymph nodes of the head, and isolation of *M. bovis* from only the lung; however, *M. bovis* was isolated from a nasal swab 63 days after inoculation. In experimentally infected cattle, *M. bovis* has been isolated from nasal secretions of cattle with mild involvement of the lung and/or thoracic lymph nodes (Neill et al., 1988). In one case, *M. bovis* was isolated from nasal secretions in the absence of gross or microscopic disease (Neill et al., 1988).

In our study, persistence of mycobacteria in tonsillar crypts differs from similar studies in cattle. One study using cattle in-

oculated intratonsilarly with *M. bovis* failed to isolate *M. bovis* from tonsillar tissues as soon as 3 to 4 hr or as long as 8 wks after inoculation (Palmer et al., 1999). This difference may be due to different host species, different strains of *M. bovis*, different pathogeneses, or different methods of sample collection for bacteriologic isolation. The significance of persistent tonsillar infection in white-tailed deer is unclear, however, persistent colonization of tonsillar crypts could play a key role in transmission through aerosol, saliva, or nasal secretions.

This study demonstrates that tuberculosis in white-tailed deer can become a disseminated disease with involvement of organs other than oropharyngeal or thoracic lymph nodes and lung within 90 days. Involvement of liver, kidney; and mesenteric, hepatic, supramammary, and iliac lymph nodes suggests that hematogenous as well as lymphatic dissemination does occur.

Suspect status after pre-inoculation skin testing of deer 8 and 10 may suggest prior exposure to *M. bovis*. However, false positive skin test results due to infection with nonpathogenic or saprophytic strains of mycobacteria occur in Cervidae (Kollias et al., 1982). No mycobacteria other than *M. bovis* were isolated from deer 8 or 10. However, the positive skin test reaction of control deer 9 at the end of the study, and the isolation of *M. gastri* from tracheobronchial lymph nodes illustrate the problem of false positive intradermal skin test reactions in Cervidae. Other mycobacteria isolated from Cervidae that may confound skin test results include, *M. avium*, *M. paratuberculosis*, *M. nonchromogenicum*, *M. diernhoferi*, *M. gastri*, *M. chelonae*, *M. smegmatis*, *M. vaccae*, and other Runyon group III or IV mycobacteria (Kollias et al., 1982; de Lisle and Havill, 1985; Quigley et al., 1997).

ACKNOWLEDGMENTS

The authors thank R. Lyon for excellent technical assistance and K. Lies, J. Lies, L. Wright, D. Weuve, M. Knipper, and T. Krausman for outstanding animal care.

Names are necessary to report factually on available data, however, the USDA neither guarantees nor warrants the standard of the product, and the use of the name by USDA implies no approval of the product to the exclusion of others that may also be suitable.

LITERATURE CITED

- DE LISLE, G. W., AND P. F. HAVILL. 1985. Mycobacteria isolated from deer in New Zealand from 1970–1983. *New Zealand Veterinary Journal* 17: 138–140.
- HUNTER, D. L. 1996. Tuberculosis in free-ranging, semi free-ranging, and captive cervids. *Revue Scientifique et technique de L'Office International des Epizooties* 15: 171–181.
- KOLLIAS, G. V., C. O. THOEN, AND M. E. FOWLER. 1982. Evaluation of comparative cervical tuberculin skin testing in cervids naturally exposed to mycobacteria. *Journal of the American Veterinary Medical Association* 181: 1257–1262.
- LEVINE, P. P. 1934. A report on tuberculosis in wild deer. *Cornell Veterinarian* 24: 264–266.
- MACKINTOSH, C. J., K. WALDRUP, R. LABES, G. BUCHAN, AND F. GRIFFIN. 1995. Intra-tonsil inoculation: An experimental model for tuberculosis in deer. *In Otago Conference Series 3, Tuberculosis in wildlife and domestic animals*, F. Griffin, and G. de Lisle (eds.). University of Otago Press, Dunedin, New Zealand, pp. 121–122.
- NEILL, S. D., J. HANNA, J. J. O'BRIEN, AND R. M. MCCRACKEN. 1988. Excretion of *Mycobacterium bovis* by experimentally infected cattle. *Veterinary Record* 123: 340–343.
- NEILL, S. D., J. HANNA, J. J. O'BRIEN, AND R. M. MCCRACKEN. 1989. Transmission of tuberculosis from experimentally infected cattle to in-contact calves. *Veterinary Record* 124: 269–271.
- PALMER, M. V., D. L. WHIPPLE, J. C. RHYAN, C. A. BOLIN, AND D. A. SAARI. 1999. Granuloma development in cattle after intratonsillar inoculation with *Mycobacterium bovis*. *American Journal of Veterinary Research* 60: 310–315.
- PAYEUR, J. B., J. L. JARNAGIN, AND J. G. MARQUARDT. 1992. Laboratory methods in veterinary mycobacteriology for the isolation and identification of mycobacteria. United States Department of Agriculture, Animal and Plant Health Inspection Service, National Veterinary Services Laboratories, Ames, Iowa, 141 pp.
- QUIGLEY, F. C., E. COSTELLO, O. FLYNN, A. GOGARTY, J. MCGUIRK, A. MURPHY, AND J. EGAN. 1997. Isolation of mycobacteria from lymph node lesions in deer. *Veterinary Record* 141: 516–518.
- RHYAN, J. C., AND D. A. SAARI. 1995. A comparative study of the histopathologic features of bovine tuberculosis in cattle, fallow deer (*Dama dama*), Sika deer (*Cervus nippon*), and red deer and elk (*Cervus elaphus*). *Veterinary Pathology* 32: 215–220.
- SAAR, L. I., AND R. GETTY. 1975. Ruminant lymphatic system. *In The anatomy of the domestic animals*, 5th Edition, R. Getty (ed.). W. B. Saunders Company, Philadelphia, Pennsylvania, p. 1027.
- SCHMITT, S. M., S. D. FITZGERALD, T. M. COOLEY, C. S. BRUNING-FANN, L. SULLIVAN, D. BERRY, T. CARLSON, R. B. MINNIS, J. B. PAYEUR, AND J. SIKARSKIE. 1997. Bovine tuberculosis in free-ranging white-tailed deer from Michigan. *Journal of Wildlife Diseases* 33: 749–758.
- SHEEHAN, D. C., AND B. B. HRAPCHAK. 1980. Microorganisms. *In Theory and practice of histotechnology*. 2nd Edition. Mosby Publishing Co., St. Louis, Missouri, pp. 233–251.
- UNITED STATES DEPARTMENT OF AGRICULTURE. 1997. Animal and Plant Health Inspection Service, Veterinary Services. Bovine tuberculosis eradication uniform methods and rules. U.S. Government Printing Office, Washington, D.C., 21 pp.

Received for publication 22 September 1998.