



DISTRIBUTION OF LIFE CYCLE STAGES OF SARCOPTES SCABIEI VAR WOMBATI AND EFFECTS OF SEVERE MANGE ON COMMON WOMBATS IN VICTORIA

Authors: Skerratt, Lee F., Middleton, Deborah, and Beveridge, Ian

Source: Journal of Wildlife Diseases, 35(4) : 633-646

Published By: Wildlife Disease Association

URL: <https://doi.org/10.7589/0090-3558-35.4.633>

BioOne Complete (complete.BioOne.org) is a full-text database of 200 subscribed and open-access titles in the biological, ecological, and environmental sciences published by nonprofit societies, associations, museums, institutions, and presses.

Your use of this PDF, the BioOne Complete website, and all posted and associated content indicates your acceptance of BioOne's Terms of Use, available at www.bioone.org/terms-of-use.

Usage of BioOne Complete content is strictly limited to personal, educational, and non - commercial use. Commercial inquiries or rights and permissions requests should be directed to the individual publisher as copyright holder.

BioOne sees sustainable scholarly publishing as an inherently collaborative enterprise connecting authors, nonprofit publishers, academic institutions, research libraries, and research funders in the common goal of maximizing access to critical research.

DISTRIBUTION OF LIFE CYCLE STAGES OF *SARCOPTES SCABIEI* VAR *WOMBATI* AND EFFECTS OF SEVERE MANGE ON COMMON WOMBATS IN VICTORIA

Lee F. Skerratt,^{1,3} Deborah Middleton,² and Ian Beveridge¹

¹ School of Veterinary Science, University of Melbourne, 250 Princes Highway, Werribee, Victoria 3030, Australia

² Australian Animal Health Laboratory, Commonwealth Scientific and Industrial Research Organisation, Ryrie Street, Geelong, Victoria 3220, Australia

³ Corresponding author (e-mail: l.skerratt@pgrad.unimelb.edu.au)

ABSTRACT: Seven female and three male common wombats (*Vombatus ursinus*) collected from forested areas of Victoria (Australia) over a 10 mo period, 10 April 1997 to 22 February 1998 had at least 30% of their skin affected by severe hyperkeratotic sarcoptic mange. Many wombats were grazing during the day, could be readily approached, were in poor body condition, and lacked subcutaneous fat. The anterolateral surface of the body was most heavily parasitised with *Sarcoptes scabiei* var *wombati* followed by the posterolateral surface, the dorsal region between the ears, the ears, ventral abdomen, medial aspect of the legs, axillary and inguinal areas, and the dorsal midline. Larvae were the most prevalent life-cycle stage followed by eggs, nymphs, females, and males. Mite numbers and the severity of clinical signs, namely thickness of scale crust and the degree of alopecia, were correlated and were symmetrical on each side of the body. Fissuring of crust and skin only occurred when scale crust was present. Bacterial infections occurred in three of 10 wombats within lymph nodes or the pleural cavity. Lymphoid depletion did not occur in lymph nodes or spleens and prescapular lymph nodes contained a greater amount of nuclear debris in germinal centres than non-mangy wombats. Seven wombats had fatty change in their livers. Gonads of mature wombats were not active or had minimal activity. Significant histopathological changes were not seen in the gastrointestinal tract, kidney, brain, myocardium, spleen, thyroid, reproductive tract, and gonads. Hematocrit, mean corpuscular volume, mean corpuscular hemoglobin, and concentrations of hemoglobin, lymphocytes, calcium, glucose, creatinine, total solids, total protein, albumin determined both colorimetrically and electrophoretically, and globulins were significantly lower and concentrations of neutrophils, monocytes, phosphorus, urea, glutamate dehydrogenase, aspartate aminotransferase and creatine kinase were significantly higher in mangy versus captive wombats. Concentrations of erythrocytes, mean corpuscular hemoglobin, leucocytes, band neutrophils, eosinophils, nucleated erythrocytes, sodium, potassium, chloride, total bilirubin, alkaline phosphatase, and gamma glutamyltransferase for mangy wombats were not significantly different from that reported for captive wombats. Hematological and pathological changes in mangy wombats were consistent with anemia, inflammation, and changes seen with starvation.

Key words: Common wombat, life cycle stages, hematology, pathology, *Sarcoptes scabiei* var *wombati*, sarcoptic mange, *Vombatus ursinus*.

INTRODUCTION

The clinical pathological and histopathological changes induced by severe sarcoptic mange have been investigated in coyotes (*Canis latrans*), rabbits (*Oryctolagus cuniculus*), domestic dogs, and foxes (*Vulpes vulpes*) (Pence et al., 1983; Arlian et al., 1988a, 1990, 1995; Little et al., 1998). The distribution and number of some life cycle stages of *Sarcoptes scabiei* have been determined in pigs and humans with slight to moderate sarcoptic mange (Johnson and Mellanby, 1942; Bartley and Mellanby, 1944; Davis and Moon, 1990) but, there

have been no studies on distribution and number of *S. scabiei* on hosts with severe hyperkeratotic sarcoptic mange, nor have mite numbers been related to clinical signs (Arlian, 1989; Burgess, 1994).

The pathogenesis of severe sarcoptic mange in common wombats (*Vombatus ursinus*) is not well understood despite being widespread in wombat populations and considered to affect the abundance of wombats (Martin et al., 1998; Skerratt et al., 1998). The histopathological changes in the skin and internal organs of common wombats with severe hyperkeratotic sar-

coptic mange have been described (Skerratt, 1998), however the clinical pathological changes have not. Here, we investigate the systemic effects of severe sarcoptic mange on common wombats including clinical pathology, the distribution and number of each life cycle stage of *Sarcoptes scabiei* var *wombati* on common wombats with severe hyperkeratotic sarcoptic mange and how mite numbers relate to clinical signs of mange.

MATERIALS AND METHODS

Ten wombats with severe hyperkeratotic sarcoptic mange were collected from forested areas of the state of Victoria (Australia; 37°30' to 38°05'S, 144°29' to 145°47'E) over 10 consecutive months from 10 April 1997 to 22 February 1998. Seven female and three male common wombats, six of them adults and four sub-adults, were collected from Bullengarook (37°31'S, 144°29'E), Eden Park (37°30'S, 145°04'E), Christmas Hills (37°39'S, 145°19'E), Chum Creek (37°36'S, 145°29'E), Toolangi (37°32'S, 145°29'E), and Longwarry North (38°05'S, 145°47'E), Victoria, Australia. Wombats were found grazing during the day and could be readily approached. They were either hand caught or tranquillised with a blowdart containing tiletamine and zolazepam (3 mg/kg Zoletil; Virbac, Peakhurst, New South Wales, Australia). Two wombats were moribund and died soon after capture and the remaining eight were euthanased with pentobarbitone injected into the abdomen (325 mg/kg Lethabarb; Virbac). Blood was collected by cardiac puncture after euthanasia for hematology and serum biochemistry, and clotted blood was collected for serum biochemistry from wombats that died soon after capture. It is possible that some of these wombats were dehydrated when blood was collected and their hydration status affected hematological and biochemical values. The weight of the wombat and the length from the upper lip to the end of the tail were measured. The sex, maturity and body condition based on subcutaneous fat deposits, muscle mass, and the prominence of bones were recorded. Both lateral aspects of the wombat were photographed and the degree of crusting and alopecia and whether fissuring occurred were visually assessed at 35 sites including the regions around each site on the skin (Fig. 1). The degree of scale crust thickness and alopecia at a site were assigned to one of four categories. For scale crust thickness these were no scale, some thin scale, thin crust (1–5 mm thick), and

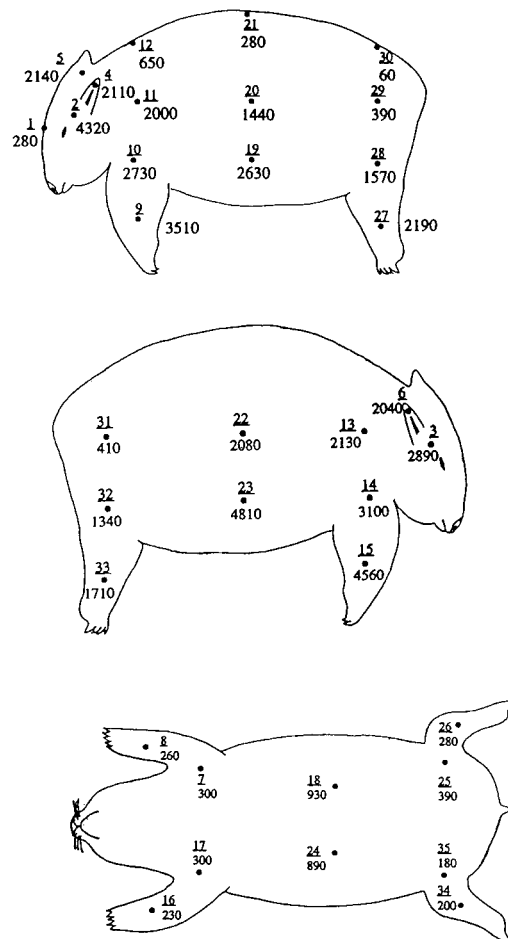


FIGURE 1. Mean number of mites, for 10 wombats with severe hyperkeratotic sarcoptic mange, at sites on lateral surfaces, along the dorsal midline and on the ventral surface. The number of a site is underlined and corresponds to the number in Table 1.

thick crust (>5 mm thick). For degree of alopecia these were no hair loss, slight hair loss, moderate hair loss, and severe hair loss.

The skin was removed and a 7 mm diameter skin biopsy punch attached to a drill was used to take cores of skin from 35 sites. The biopsies were macerated in 10% potassium hydroxide in test tubes placed in boiling water until the skin had dissolved. To determine the number of each life cycle stage of *S. scabiei* var *wombati* the solution was made up to 10 ml with water and an aliquot of between 1–5 ml, depending on the density of mites and the solution's opacity, was examined under a stereomicroscope. If the density of mites was very high, then a 1 ml aliquot was added to 9 ml of water and an aliquot of between 1–5 ml of this solution was

taken depending on the density of mites. Life cycle stages of *S. scabiei* var *wombati* were identified according to Fain (1968). Males, larvae, eggs, and egg shells could be easily identified based on their morphology. Females were differentiated from other life cycle stages based on their larger size (length >350 μm), measured with an eyepiece graticule in a stereomicroscope, and occasionally on the presence of an egg *in utero*. Tritonymphs could not be differentiated from protonymphs under the stereomicroscope and all were simply classed as nymphs. The distribution of life cycle stages in 10 ml of potassium hydroxide solution was assessed for normality by dividing the solution into ten 1 ml aliquots. A one-sample Kolmogorov-Smirnov exact test was performed with the null hypothesis being that the differences between the observed frequencies and the mean were normally distributed (Sokal and Rohlf, 1997). The distribution of mites in a region of skin with similar clinical signs was assessed for normality by taking five biopsies. A one-sample Kolmogorov-Smirnov exact test was again performed with the null hypothesis being that the differences between the observed frequencies and the mean were normally distributed (Sokal and Rohlf, 1997). Differences between sites were assessed for significance using a randomized block design with the blocking variable being wombats and the treatment variable being sites (Sokal and Rohlf, 1997). Biopsies were fixed in Bouin's fixative from 20 of the above 35 sites to measure the thickness of crust and skin. Sites were compared for significant differences using Wilcoxon's matched-pairs signed-ranks test (Sokal and Rohlf, 1997). Correlations between clinical signs and mite numbers were performed using either Spearman's coefficient of rank correlation or Pearson's coefficient of product moment correlation (Sokal and Rohlf, 1997).

Wombats were necropsied and samples of liver, lung, kidney, myocardium, brain, adrenal gland, thyroid gland, prescapular lymph node, mesenteric lymph node, spleen, stomach, duodenum, jejunum, ileum, colon, uterus, and gonads were fixed in 10% formalin and processed for histological examination. Culturing and identification of bacteria were attempted from internal tissues suspected of being infected with bacteria. The colonic contents were examined for nematodes and ticks were removed from skin for identification. The proportion of white pulp in histological sections of spleens of wombats with sarcoptic mange were measured using a Sigma Scan Scientific Measurement System 1.10 (Jandel Scientific, Corte Madera, California, USA) and compared with proportions from three normal wombats using the

Student's two sample *t*-test two tailed, assuming equal variances (Sokal and Rohlf, 1997).

Hematological parameters were measured using a Coulter Counter, Model S-Plus 4, impedance hematology analyser, calibrated with human blood (Coulter Electronics, Hialeah, Florida, USA), and by examination with a compound microscope of a blood smear stained by the May-Gruenwald-Giemsa method (Strumia, 1963). Electrolyte concentrations were determined by the ion-specific potentiometry method (Baker and Silverton, 1985) using a Vet Lyte electrolyte analyser (Idexx Laboratories, Zetland, New South Wales, Australia). Calcium, phosphate, urea nitrogen, creatinine, glutamate dehydrogenase, alkaline phosphatase, aspartate aminotransferase and creatine kinase concentrations were determined colorimetrically with a Cobas Mira spectrophotometer (Roche Diagnostics, Branchburg, New Jersey, USA) using reagents and methods from Trace Scientific (Baulkham Hills, New South Wales, Australia), and albumin and total protein concentrations were determined colorimetrically using methods and reagents from Randox Laboratories (Crumlin, Antrim County, United Kingdom). Values from five captive wombats collected from Glenburn (37°26'S, 145°25'E) (Victoria, Australia) and held in captivity for 2 mo and those reported by Presidente (1982) for captive wombats from Boolarra (38°23'S, 146°17'E) (Victoria, Australia) were used as a comparison. Differences were assessed for significance using the Student's two sample *t*-test two tailed, assuming either equal or unequal variances (Sokal and Rohlf, 1997). Electrophoretograms were carried out on Gelman super sephore mylar supported cellulose acetate strips in a Gelman semi-micro electrophoresis chamber. The strips were stained with Ponceau S and scanned with a Gelman ACD-18 densitometer (Gelman Sciences, Ann Arbor, Michigan, USA). All statistical calculations were performed by hand calculator or SPSS® for Windows 8.0 (SPSS Inc., Chicago, Illinois, USA). Differences were regarded as significant when $P \leq 0.05$.

RESULTS

Subcutaneous fat was not seen in any of the wombats and all were in poor body condition. The ranges and means \pm standard errors of the weights and lengths were 10–28 (21 ± 2) kg and 76–114 (100 ± 3) cm, respectively. All wombats had at least 30% of the skin surface affected with severe hyperkeratotic sarcoptic mange.

There was no evidence that life-cycle

TABLE 1. Mean numbers of *Sarcoptes scabiei* per square centimetre at 35 sites on 10 wombats with severe hyperkeratotic sarcoptic mange from Victoria, Australia. (See Fig. 1 for position of site on body)

Site	Males	Females	Nymphs	Larvae	Unknown	Total	Eggs	Egg shells
1	10	50	80	130	10	280	30	60
2	270	350	400	2,950	350	4,320	1,640	7,120
3 ^a	60	500	370	1,380	580	2,890	850	5,060
4	100	320	370	1,090	230	2,110	1,020	1,970
5	50	180	400	1,460	50	2,140	510	3,200
6 ^a	90	240	430	1,110	170	2,040	630	1,420
7	40	80	80	70	30	300	170	30
8	40	20	100	100	0	260	120	20
9	80	520	470	2,180	260	3,510	1,560	10,550
10	180	440	540	1,490	80	2,730	1,020	6,560
11	140	270	210	1,250	130	2,000	840	4,330
12	50	80	230	260	40	650	90	200
13	100	220	340	1,350	120	2,130	530	4,260
14	180	500	460	1,670	290	3,100	910	6,680
15	110	400	980	2,960	110	4,560	810	6,170
16	10	20	90	110	20	230	0	10
17	10	70	100	110	10	300	100	70
18	70	150	310	320	90	930	220	170
19	150	230	420	1,570	270	2,630	550	1,990
20	10	170	380	710	170	1,440	630	4,880
21	0	10	80	170	20	280	10	0
22	120	290	270	1,330	80	2,080	540	2,890
23	140	200	420	3,310	740	4,810	340	2,060
24	50	40	340	390	70	890	60	40
25	30	40	160	130	30	390	30	20
26	10	10	150	100	10	280	10	0
27	230	160	490	1,160	150	2,190	300	1,710
28	90	160	390	810	110	1,570	320	1,140
29	0	40	110	210	20	390	60	140
30	0	10	10	20	30	60	0	0
31	50	40	140	170	10	410	70	160
32	90	120	390	610	120	1,340	320	720
33	80	240	300	970	120	1,710	460	2,410
34	20	10	60	100	10	200	10	0
35	10	20	60	90	10	180	30	10
Mean	80	180	290	910	130	1,580	440	2,170

^a Mean numbers for sites 3 and 6 represent the number of mites from both the inner and outer surfaces of the pinna.

stages were not normally distributed in the potassium hydroxide solution (P exact two-tailed = 0.826). There was no evidence that mites were not distributed normally in a region of skin with similar clinical signs (P exact two-tailed = 0.949). When considering the mean or median number of each life cycle stage of *S. scabiei* for the 10 wombats, larvae were the most prevalent life-cycle stage followed by eggs, nymphs, females, and males (Table 1). The anterolateral part of the body was most heavily parasitized followed by the posterolateral, the dorsal region between the

ears, the ears, ventral abdomen, medial aspect of the legs, axillary and inguinal areas, and the dorsal midline (Fig. 1, Table 1). More than 1,000 mites per cm² were found at all sites on the lateral sides of the body except those near the rump which had fewer than 400 mites per cm². The ears had 1,000 mites per cm² on each side of the pinna. Sites along the dorsal midline varied greatly in intensity of infection. The site between the ears was heavily infected (2,140 per cm²) whereas the site on the rump was the least infected site on the body (60 mites per cm²). Mite numbers

TABLE 2. Percentage of wombats ($n = 10$) from Victoria, Australia that had a certain qualitative category of crust thickness and alopecia and that had fissuring of crust and skin at 35 sites on the body (See Fig. 1 for position of site).

Site	Percentage of wombats								Fissuring present
	Categories of crust thickness ^a				Categories of alopecia ^b				
	A	B increasing thickness →	C	D	A	B increasing hair loss →	C	D	
1	40	10	50	0	90	10	0	0	0
2	0	20	40	40	10	40	10	40	20
3	0	20	40	40	20	10	30	40	20
4	10	10	30	50	10	20	0	70	10
5	0	10	60	30	30	30	20	20	0
6	10	10	40	40	10	20	10	60	0
7	70	30	0	0	70	30	0	0	0
8	60	40	0	0	60	40	0	0	0
9	0	10	50	40	10	20	10	60	40
10	0	0	60	40	10	10	20	60	50
11	0	0	30	70	10	0	20	70	50
12	10	10	40	40	10	20	30	40	10
13	0	0	30	70	10	10	10	70	50
14	0	0	50	50	10	10	20	60	50
15	0	10	50	40	10	10	40	40	60
16	70	30	0	0	60	40	0	0	0
17	70	30	0	0	60	40	0	0	0
18	30	40	20	10	30	10	60	0	20
19	10	10	60	20	10	0	40	50	50
20	0	10	60	30	10	10	20	60	50
21	40	30	30	0	40	20	30	10	0
22	0	10	60	30	20	0	10	70	60
23	10	20	50	20	10	10	20	60	40
24	30	40	30	0	30	20	40	10	0
25	80	20	0	0	60	40	0	0	0
26	80	20	0	0	60	40	0	0	0
27	10	0	60	30	10	20	30	40	40
28	10	0	50	40	10	10	30	50	40
29	30	20	40	10	60	10	10	20	20
30	30	50	20	0	70	20	0	10	0
31	30	30	40	0	60	10	0	30	10
32	10	0	50	40	20	0	50	30	40
33	0	10	60	30	10	20	40	30	30
34	70	30	0	0	60	40	0	0	0
35	70	30	0	0	40	60	0	0	0

^a A = no crust, B = some thin scale, C = thin to moderate (1–5 mm) crust, D = moderate to thick (>5 mm) crust.

^b A = no alopecia, B = slight hair loss, C = moderate hair loss, D = severe to complete hair loss.

were just below 1,000 per cm² on the ventral abdomen. Mite numbers were low, below 400 per cm², on the medial aspect of legs and in the axillary and inguinal sites. The site on the dorsal midline between the ears and those on the ears and lateral surfaces, apart from those high on the hindlimb near the rump, were 5 to 100 times more heavily infected than sites on ventral surfaces and the dorsal midline ($P < 0.05$).

Mite numbers at any site did not differ significantly from those at the symmetrical site on the other side of the body ($P > 0.05$).

Scale crust thickness and severity of alopecia were correlated with mite numbers (Table 2). The r values for qualitative crust thickness, qualitative alopecia, and quantitative crust thickness versus numbers of mites were 0.69, 0.71 and 0.61, respective-

ly ($P < 0.001$). Crust thickness was also highly correlated with severity of alopecia ($r = 0.75$; $P < 0.001$) (Table 2). Fissuring in crust and skin only occurred in approximately one half of the wombats when scale crust was present (Table 2). There were no significant differences in scale crust thickness and degree of alopecia between sites and their symmetrical sites on the other side of the body ($P > 0.05$). Hence, the amount of scale crust and the degree of alopecia on each side of the body were symmetrical. Crust thickness was not correlated with skin thickness ($P = 0.247$).

Three wombats with low albumin concentrations had ascites. Two wombats had focal areas of mixed, but predominantly mononuclear, inflammatory infiltrate within lungs. The right lung and the extremities of the left lung of one of these wombats were dark red and firm and oozed blood when cut. In another wombat a light growth of gram negative organisms was obtained from fluid in the pleural cavity, although few leucocytes and no bacteria were seen in a smear of the fluid. Moderate multifocal mononuclear inflammation occurred in myocardium and mild interstitial mixed inflammatory infiltrates were seen in renal cortex. On gross examination this wombat had more than 10 ml of pink fluid in its left pleural cavity, a rough left pleural surface and left thoracic wall and adhesions between the pleura and thoracic wall. The mitral valve had irregular soft red material attached to its caudal margin. One wombat had abscesses containing gram negative coccoid bacteria in submandibular lymph nodes and fibrous lesions with mononuclear inflammation in the kidney consistent with chronic infarction. Another wombat had an abscess (5 mm diameter) containing gram negative cocci in a prescapular lymph node and a small, multifocal, mixed but predominantly mononuclear, inflammatory infiltrate in myocardium. One wombat had many small foci of mononuclear inflammation in the myocardium. One wombat had a cataract

in the right eye and the mucosa in the first 10 cm of the colon was thickened with gas and congested. Two wombats had focal endogenous lipid pneumonia at the periphery of lobes.

Seven wombats had vacuolation of hepatocytes consistent with fatty change of the liver. Eight wombats had multifocal areas of inflammation and necrosis of the liver consistent with bacteria entering the body, possibly from breaks in the integrity of the skin due to mange, and causing reactive hepatitis. Testes contained little or no sperm and ovaries had few or no follicles. One wombat had old corpora lutea. Prescapular lymph nodes, mesenteric lymph nodes and spleens from wombats with mange ($n = 10$) were similar to those from free living wombats without mange ($n = 3$) in terms of the frequency, size and cellular density of germinal centres and the density of parafollicular tissue. There was no significant difference in the proportion of white pulp in histological sections of spleens of wombats with mange compared to normal wombats, 12.2% and 11.5%, respectively ($P = 0.845$). There appeared to be more nuclear debris in germinal centres of the prescapular lymph nodes from wombats with mange. The histopathological changes present in the skin were similar to that described by Skerratt (1998) for wombats with hyperkeratotic sarcoptic mange. Histopathological lesions were not seen in the gastrointestinal tract, brain, spleen, thyroid, reproductive tract, and gonads of wombats.

The mean corpuscular volume, mean corpuscular hemoglobin and concentrations of lymphocytes, calcium, creatinine, total solids, total protein and albumin, determined electrophoretically and by the bromocresol method, of wombats with mange were significantly lower and concentrations of neutrophils, monocytes, phosphorus, urea, glutamate dehydrogenase, aspartate aminotransferase and creatine kinase were significantly higher than those of captive wombats without mange in this study ($P < 0.05$) (Tables 3, 4). He-

TABLE 3. Hematological values for healthy captive wombats in this study and that of Presidente (1982), compared with wombats exhibiting severe hyperkeratotic sarcoptic mange.

Parameter	Captive ^a (<i>n</i> = 5)		Captive (Presidente, 1982) ^b (<i>n</i> = 8–12)		Sarcoptic mange ^c (<i>n</i> = 8)	
	Mean ± SE	Range	Mean ± SE	Range	Mean ± SE	Range
Hemoglobin (g/dl)	11.9 ^{de} ± 0.7	10.1–14.2	13.7 ^d ± 0.3 (8) ^f	11.2–14.6	11.5 ^e ± 0.3	9.8–12.8
Hematocrit (%)	35.2 ^{de} ± 1.0	32.0–37.0	38.1 ^d ± 0.9 (8)	34.0–42.0	34.5 ^e ± 0.9	29.0–37.0
Erythrocytes (×10 ¹² /l)	5.1 ^d ± 0.3	4.4–6.0	5.7 ^d ± 0.2 (8)	4.4–6.6	5.5 ^d ± 0.2	4.9–6.2
MCV ^g (fl)	68.8 ^d ± 2.1	62.0–73.0	66.0 ^{de} ± 1.0 (12)	62.0–76.0	62.9 ^e ± 1.4	57.0–69.0
MCH ^h (pg)	23.2 ^d ± 0.2	23.0–24.0	22.5 ^d ± 0.5 (12)	20.0–25.8	20.9 ^e ± 0.5	18.0–23.0
MCHC ⁱ (g/dl)	33.6 ^d ± 1.2	32.0–38.0	34.1 ^d ± 0.5 (12)	32.3–36.8	33.5 ^d ± 0.3	32.0–34.0
Leucocytes (×10 ⁹ /l)	12.5 ^d ± 0.7	10.4–14.0	12.9 ^d ± 1.2 (12)	7.5–19.9	14.0 ^d ± 1.1	10.3–20.9
Bands (×10 ⁹ /l)	0.0 ^d ± 0.0	0.0–0.0	—	—	0.0 ^d ± 0.0	0.0–0.2
Neutrophils (×10 ⁹ /l)	4.0 ^d ± 0.5	3.1–5.5	5.3 ^d ± 0.8 (12)	2.4–10.8	9.7 ^e ± 1.2	5.4–16.1
Lymphocytes (×10 ⁹ /l)	8.3 ^d ± 0.7	6.5–10.5	6.5 ^d ± 0.9 (12)	1.9–12.8	3.8 ^e ± 0.5	1.5–6.5
Monocytes (×10 ⁹ /l)	0.0 ^d ± 0.0	0.0–0.0	0.6 ^e ± 0.1 (12)	0.1–1.0	0.4 ^e ± 0.1	0.0–1.3
Eosinophils (×10 ⁹ /l)	0.2 ^d ± 0.1	0.0–0.5	0.4 ^d ± 0.2 (12)	0.0–0.6	0.0 ^d ± 0.0	0.0–0.1
NRC ^j (/100 leucocytes)	0.2 ^d ± 0.2	0.0–1.0	—	—	0.5 ^d ± 0.4	0.0–3.0
Total solids (g/l)	69 ^d ± 2	64–76	—	—	61 ^e ± 1	55–66

^a Four female, one male, three mature and two immature wombats.

^b When (*n* = 8) eight female, five mature and three immature wombats. When (*n* = 12) eight female, four male, seven mature and five immature wombats.

^c Six female, two male, four mature and four immature wombats.

^d Means in a row not sharing an identical superscript letter were significantly different from each other (*P* < 0.05).

^e Number of wombats in parentheses.

^f MCV = mean corpuscular volume.

^g MCH = mean corpuscular hemoglobin.

^h MCHC = mean corpuscular hemoglobin concentration.

ⁱ NRC = nucleated red cell.

matocrit and concentrations of hemoglobin, erythrocytes, mean corpuscular hemoglobin, leucocytes, band neutrophils, eosinophils, nucleated erythrocytes, sodium, potassium, chloride, glucose, total bilirubin, alkaline phosphatase, gamma glutamyltransferase, and electrophoretically determined alpha 1 and 2, beta and gamma globulins of wombats with mange were not significantly different from those of captive wombats in this study (*P* > 0.05) (Tables 3, 4). Corpuscular hemoglobin, hematocrit and concentrations of hemoglobin, lymphocytes, calcium, glucose, total protein and electrophoretically determined albumin and globulins of wombats with mange were significantly lower and concentrations of neutrophils, phosphorus and aspartate aminotransferase were significantly higher than those reported by Presidente (1982) (*P* < 0.05) (Tables 3, 4). Mean corpuscular volume and concentrations of erythrocytes, mean corpuscular

hemoglobin, leucocytes, monocytes, eosinophils, sodium, potassium and chloride were not significantly different from those reported by Presidente (1982) (*P* > 0.05) (Tables 3, 4).

Seven of eight wombats had some hematology values outside the range of values reported by Presidente (1982). Two had lower concentrations of hemoglobin, two had lower hematocrits, three had lower mean red blood cell volumes, one had a lower mean red blood cell hemoglobin level and one had a lower mean red blood cell hemoglobin concentration. Two wombats had one to three nucleated red blood cells per 100 white blood cells. Three wombats had slight anisocytosis of red blood cells, three had polychromasia of a small to moderate number of red blood cells, one had hypochromasia of red blood cells and one had stomatocytes.

Six of eight wombats had blood leucocyte concentrations outside the range re-

TABLE 4. Biochemical values for healthy captive wombats in this study and that of Presidente (1982), compared with wombats exhibiting severe hyperkeratotic sarcoptic mange.

Parameter	Captive ^a (n = 5)		Captive (Presidente, 1982) ^b (n = 5–9)		Sarcoptic mange ^c (n = 5–10)	
	Mean ± SE	Range	Mean ± SE	Range	Mean ± SE	Range
Sodium (mmol/l)	145 ^d ± 3	141–155	139 ^d ± 2 (9) ^g	128–154	144 ^d ± 3 (10)	130–164
Potassium (mmol/l)	5.3 ^d ± 0.3	4.7–6.1	4.5 ^d ± 0.1 (9)	3.8–5.2	5.7 ^d ± 1.0 (10)	2.9–10.4
Chloride (mmol/l)	103 ^d ± 2	98–110	96 ^d ± 3 (9)	80–112	99 ^d ± 2.2 (10)	91–110
Calcium (mmol/l)	2.7 ^d ± 0.1	2.5–3.0	2.6 ^d ± 0.1 (9)	1.7–3.3	1.9 ^e ± 0.2 (10)	1.3–2.9
Phosphate (mmol/l)	1.0 ^d ± 0.2	0.6–1.4	1.7 ^e ± 0.2 (9)	0.8–2.6	3.4 ^f ± 0.6 (10)	2.0–8.6
Urea (mmol/l)	8.6 ^d ± 0.8	6.9–11.8	5.2 ^e ± 0.7 (9)	3.2–9.5	16.5 ^f ± 1.8 (10)	8.4–23.1
Creatinine (mmol/l)	0.07 ^d ± 0.00	0.06–0.09	—	—	0.05 ^e ± 0.00 (10)	0.03–0.07
Glucose (mmol/l)	3.8 ^d ± 0.1	3.5–4.1	5.1 ^e ± 0.4 (9)	2.6–6.3	2.8 ^d ± 1.1 (5)	0.6–6.4
Total Bilirubin (µmol/l)	3.6 ^d ± 1.1	1.0–7.0	—	—	3.8 ^d ± 0.7 (10)	0.0–7.0
Glutamate Dehydrogenase (U/l)	11 ^d ± 2	7–17	—	—	81 ^e ± 24 (10)	12–263
Alkaline Phosphatase (U/l)	227 ^d ± 37	142–320	—	—	160 ^d ± 21 (10)	60–270
γ-glutamyltransferase (U/l)	8.4 ^d ± 0.9	7.0–11.0	—	—	7.7 ^d ± 0.5 (10)	6.0–11.0
Aspartate Aminotransferase (U/l)	34 ^d ± 5	22–47	55 ^d ± 13 (5)	19–97	188 ^e ± 32 (10)	74–361
Creatine Kinase (U/l)	83 ^d ± 23	31–136	—	—	1,192 ^e ± 271 (10)	280–2,716
Total Protein (g/l) Biuret ^h	68 ^d ± 2	62–72	71 ^d ± 2 (9)	58–83	59 ^e ± 2 (10)	50–67
Albumin (g/l) Bromocresol ⁱ	32 ^d ± 1	28–35	—	—	26 ^e ± 1 (10)	20–33
Electrophoretic ^j	31 ^d ± 0.5	29–32	29 ^d ± 1 (9)	25–47	24 ^e ± 1 (10)	16–28
Total Globulins (g/l)	37 ^{de} ± 2	30–41	42 ^d ± 2 (9)	30–52	34 ^e ± 2 (10)	26–41
Alpha 1 (g/l)	2.4 ^d ± 0.2	1.7–2.9	—	—	3.3 ^d ± 0.4 (10)	1.9–5.2
Alpha 2 (g/l)	7.7 ^d ± 0.7	6.4–10	—	—	6.4 ^d ± 0.4 (10)	5.0–8.1
Beta (g/l)	23 ^d ± 1	21–28	—	—	23 ^d ± 2 (10)	11–30
Gamma (g/l)	3.4 ^d ± 0.7	1.7–5.3	—	—	2.3 ^d ± 0.4 (10)	0.9–4.4

^a Four female, one male, three mature and two immature wombats.

^b When (n = 9) five female and four male wombats. When (n = 5) three female and two male wombats.

^c When (n = 10) seven female, three male, six mature and four immature wombats. When (n = 5) three mature female and two mature males.

^{def} Means in a row sharing an identical superscript letter were not significantly different from each other ($P > 0.05$).

^g Number of wombats in parentheses.

^h Determined by the biuret method.

ⁱ Determined by the bromocresol green method.

^j Determined electrophoretically.

TABLE 5. Number of mangy wombats with or without elevated glutamate dehydrogenase concentrations, reactive hepatitis, and fatty change in the liver.

		Elevated glutamate dehydrogenase concentrations	
		Yes	No
Reactive Hepatitis	Yes	6	2
	No	2	0
Fatty Change	Yes	5	2
	No	3	0
Reactive Hepatitis and Fatty Change	Yes	3	2
	No	5	0

ported by Presidente (1982). Two wombats, one with pneumonia and another with abscesses in submandibular lymph nodes, had a neutrophilia and one also had a lymphopenia and the other had activated lymphocytes (increased amounts of basophilic intensity of cytoplasm). One wombat had a monocytosis, increased concentrations of band neutrophils and activated lymphocytes. This wombat had a small abscess in its axillary lymph node. Two wombats had either activated or very large lymphocytes; one of these had pneumonia and the other had endogenous lipid pneumonia and some renal tubular necrosis. One wombat had slight basophilic granulation of the cytoplasm of neutrophils indicating "toxic" change. This wombat had bacterial infection of the pleural cavity and inflammation of myocardium and kidneys. Three of six wombats with abnormal blood leucocyte values had bacterial infections in internal organs and all six had inflammation in organs other than skin. The two wombats with normal blood leucocyte values had no visible lesions other than sarcoptic mange.

All 10 wombats had some biochemical values outside the ranges reported by Presidente (1982) (Table 5). One wombat had an elevated sodium concentration, four wombats had higher potassium concentrations, four wombats had lower potassium concentrations, three wombats had lower calcium concentrations, four

wombats had higher phosphate concentrations, nine wombats had higher concentrations of urea, two wombats had lower concentrations of glucose, one wombat had a higher concentration of glucose, eight wombats had higher concentrations of glutamate dehydrogenase, eight wombats had higher concentrations of aspartate aminotransferase, five wombats had lower concentrations of total protein, and three wombats had lower concentrations of albumin. On electrophoresis five and three of ten wombats had lower concentrations of albumin and globulins, respectively, than the reference intervals reported by Presidente (1982). Presidente (1982) did not measure concentrations of glutamate dehydrogenase, alkaline phosphatase, and creatine kinase.

Seven of the 10 wombats had between 1 to 20 ticks attached to ventral areas without severe mange. These were the common wombat tick (*Aponomma auruginans*), *Ixodes tasmani*, and *Ixodes cornuatus*. *Strongyloides spearei* was seen in histological sections of the duodenum and jejunum of six wombats. *Eimeria arundeli* was seen in histological sections of the jejunum and ileum from five wombats. Ciliates were seen in histological sections of the colon from eight wombats. Seven of the 10 wombats had strongyloid nematodes in their colon. A minimal to moderate mixed inflammatory infiltrate was present in the small intestines and colons of wombats. No parasites were seen in stomachs nor was there evidence of infection with *Fasciola hepatica* in livers.

DISCUSSION

Wombats with severe sarcoptic mange which were found grazing during the day were used in this study. Wombats are generally nocturnal hence our selection of mange affected wombats was biased. Despite this biased selection of wombats, they provided valuable information.

The ratio of female to male *S. scabiei* var *wombati* (2:1) suggests that males may mate with several females or that females

live longer than males. Heilesen (1946) found that *S. scabiei* males seek females and Arlian et al. (1984, 1989) found that females survive longer than males off the host. The ratio of larvae and eggs to females (11:6:2) is lower than expected since *S. scabiei* var *hominis* females lay 2 to 4 eggs per day and *S. scabiei* var *canis* larvae and eggs last for 3 to 4 and 2 to 3 days, respectively (Neste and Lachapelle, 1981; Arlian et al., 1988b). The ratio of nymphs to females (3:2) is much lower than expected given that nymphs last 5 to 7 days according to Arlian et al. (1988b). This suggests that there is either a large mortality of nymphs and moulting larvae or that nymphs leave the host in search of new hosts. Alternatively, the nymphs of *S. scabiei* var. *wombati* could have a shorter life span. Misclassification of nymphs and females while counting was unlikely to account for such a large discrepancy between the expected ratio of nymphs to females and the ratio reported here, given the life cycle of the mite.

The consistent difference and symmetry in the degree of parasitism between sites on the body suggests that there is site predilection for the mite, namely the anterolateral surfaces of the wombat's body. Site predilection has been reported for *S. scabiei* in pigs and humans (Davis and Moon, 1990; Johnson and Mellanby, 1942; Bartley and Mellanby, 1944). Davis and Moon (1990) suggest that the faces and ears of pigs are more readily infected because pigs explore with their noses. They also suggest that the face and ears provide a more favorable environment because the creases in skin and coarse hair may prevent removal of mites by abrasion. In humans, the hands and feet are more frequently infected than other parts of the body (Johnson and Mellanby, 1942; Bartley and Mellanby, 1944). Johnson and Mellanby (1942) stated that the reaction to mites in these areas was comparatively slight. The factors affecting *S. scabiei* site predilection in wombats were not apparent. Skin thickness was not inversely correlated with par-

asitism although the thickest skin, the rump, had the lowest intensity. Severe hyperkeratotic *S. scabiei* infection should always be visible, even from a distance given that clinical signs of mange, namely thickness of scale crust and severity of alopecia, were highly correlated with each other and with the number of *S. scabiei*. Skerratt (1998) found that hair follicles were atrophic in common wombats with severe hyperkeratotic sarcoptic mange suggesting that the thick scale crust prevents hair regrowth. A view of one side of a wombat is sufficient to assess the severity of mange since clinical signs of severe sarcoptic mange were symmetrical. These findings are relevant to the interpretation of observations made in the field on wild wombats.

In contrast to this study, Skerratt (1998) did not report bacterial infections in nine common wombats with severe hyperkeratotic sarcoptic mange from the shire of Healesville (Victoria, Australia) in 1992 although one had *Pneumocystis carinii* infection concurrent with lymphosarcoma. It is probable that bacterial infections in the dermis, which occur following fissuring associated with scale crust, allow bacteria to infect internal organs. Secondary bacterial infections have been reported in rabbits and humans with scabies (Arlian et al., 1990; Burgess, 1994). While the immune response in the dermis towards severe *S. scabiei* infection in wombats is slight (Skerratt, 1998), there was no evidence of lymphoid depletion in lymph nodes or spleens in the wombats reported here. Lymphoid depletion has been reported in marsupials, seasonally in rainforest possums (Speare et al., 1984), following breeding in male antechinus (Barker et al., 1978) and in possums, in poor condition, held in captivity (Presidente and Correa, 1981). The greater quantity of nuclear debris in the prescapular lymph nodes is probably a consequence of the local immune response to severe *S. scabiei* infection.

Several pathological changes suggest that wombats were using their energy

stores to meet the imbalance between the energy requirements associated with severe hyperkeratotic sarcoptic mange and their nutritional supply. Wombats were in poor body condition, lacked subcutaneous fat, had low concentrations of protein, albumin and globulins in blood and had low concentrations of creatinine indicating a low muscle mass (Duncan et al., 1994). The high concentrations of urea in blood suggest increased protein catabolism and fatty change in the liver is consistent with wombats mobilizing their peripheral fat stores but lacking sufficient protein synthesis to generate lipoprotein (Jubb et al., 1993). The wombats with severe hyperkeratotic sarcoptic mange reported by Skerratt (1998) were generally emaciated. Similar changes were seen in coyotes and rabbits with severe hyperkeratotic sarcoptic mange, >50% and 10 to 30% of body affected, respectively, except rabbits had low blood urea nitrogen and high total serum protein while coyotes had normal total serum protein concentrations (Pence et al., 1983; Arlian et al., 1988a). The absence of these changes in dogs and foxes with short term advanced sarcoptic mange is attributed to the brief duration of the mange (Arlian et al., 1995; Little, 1998). The low concentrations of blood glucose in wombats have also been seen in coyotes but not in rabbits with severe hyperkeratotic sarcoptic mange nor dogs and foxes with short term advanced sarcoptic mange (Pence et al., 1983; Arlian et al., 1988a, 1995; Little, 1998). Presidente (1982) reported reduced glucose and albumin concentrations in a common wombat with severe hyperkeratotic sarcoptic mange.

Arlian et al. (1988a) demonstrated that severe mange can increase the energy demands of rabbits leading to weight loss but did not attribute these energy demands to mite consumption. However, the energy demands of scale crust production and exudation from fissures in skin must be large. Wombats are nocturnal but those with severe mange will graze during the day (Skerratt, 1998) possibly because of energy

demands or for thermoregulatory reasons. They may also be unable to compete with healthy wombats for resources at night. Presidente (1982) and Doube (1982) suggested that wombats with severe sarcoptic mange may have impaired powers of mastication and may starve. It is possible that wombats with severe sarcoptic mange eat less.

Wombats with severe mange are intent on grazing, take little heed of their surroundings, and therefore can be more readily approached. Alados et al. (1996) found that the complexity of exploratory behaviour was reduced in Spanish ibex (*Capra pyrenaica*) with *S. scabiei* infection. Vision and hearing may also be reduced in wombats with severe sarcoptic mange (Skerratt, 1998). Gonads of mature wombats were not active or had minimal activity suggesting that wombats with severe mange are unlikely to reproduce. It is unlikely that wombats were collected only during the non breeding season given the long duration of the wombat breeding season and the 10 month period of collection (McIlroy, 1973).

Wombats with severe sarcoptic mange had a lower hematocrit, mean corpuscular volume, mean corpuscular hemoglobin and concentrations of hemoglobin than captive wombats. This may have been due to sarcoptic mange as rabbits and dogs with severe and short term advanced sarcoptic mange respectively have developed anemia, and chronic disease can cause anemia (Arlian et al., 1988a, 1995; Duncan et al., 1994). However, the low mean corpuscular volume in some wombats suggests that the anemia may have been due to dietary insufficiency (Duncan et al., 1994). Arlian et al. (1988a) suggests that iron deficiency may be involved in some way. The presence of nucleated and polychromatic erythrocytes in the blood of a few wombats indicates that a regenerative response was possibly occurring in bone marrow (Duncan et al., 1994).

The immune system of wombats with severe mange was responding to either the

bacterial infections in internal organs and skin or the *S. scabiei* infestation given their higher concentration of neutrophils and monocytes, the presence of band neutrophils, transformed lymphocytes and neutrophils, and the lower concentration of lymphocytes in the blood compared with captive wombats (Skerratt, 1998; Duncan et al., 1994). Endogenous corticosteroid production and release by adrenals could also be contributing to these changes in the blood (Duncan et al., 1994). Similar leucocyte changes occurred in rabbits and dogs with severe and short term advanced sarcoptic mange but not in coyotes with severe mange (Arlian et al., 1988a, 1995; Pence et al., 1983). Foxes with short term, severe hyperkeratotic sarcoptic mange had a neutrophilia and eosinophilia (Little et al., 1998). Total globulins were low in wombats with severe mange although concentrations of each type of globulin; alpha 1 and 2, beta and gamma, were normal. Total globulins were high in rabbits and normal in coyotes, dogs and foxes with mange (Arlian et al., 1988a, 1995; Pence et al., 1983). Although globulin levels remained normal in coyotes, gamma globulins increased with severity of mange and alpha globulins decreased (Pence et al., 1983).

The hyperkalemia in some wombats may have been an artifact due to the delay between sample collection and measuring potassium concentrations as prolonged contact between serum and the blood clot can lead to mildly elevated potassium concentrations (Duncan et al., 1994). The hypokalemia in other wombats may have been due to anorexia (Duncan et al., 1994). Potassium concentrations did not deviate from normal in rabbits, dogs and foxes with sarcoptic mange (Arlian et al., 1988a, 1995; Little, 1998). The low calcium concentrations were sometimes associated with low albumin and protein concentrations and were probably partly due to less protein bound calcium (Duncan et al., 1994). Similar low calcium concentrations were reported in rabbits and coyotes

with severe sarcoptic mange but not in dogs or foxes with short term advanced sarcoptic mange (Pence et al., 1983; Arlian et al., 1988a, 1995; Little, 1998). Hypocalcemia was also often associated with hyperphosphatemia and may be partially due to hypoparathyroidism (Duncan et al., 1994). The higher concentrations of glutamate dehydrogenase were probably not due to the reactive hepatitis or fatty change seen in livers since the relative risk of elevated concentrations due to reactive hepatitis and fatty change or both were 0.75, 0.71, and 0.60, respectively (Table 5). Elevated concentrations of liver enzymes suggestive of liver damage occurred in rabbits with severe hyperkeratotic sarcoptic mange but not in dogs or foxes with short term advanced sarcoptic mange (Arlian et al., 1988a, 1995; Little, 1998). Arlian et al. (1990) found that rabbits with severe hyperkeratotic sarcoptic mange had amyloidosis, hepatocellular swelling and necrosis, and cholangitis of livers. Elevated lactate dehydrogenase concentrations in coyotes were attributed to skin and not liver damage (Pence et al., 1983). The high concentrations of aspartate aminotransferase in the blood of wombats may have been due to liver damage but also may have been associated with muscle damage indicated by the high creatine kinase concentrations (Duncan et al., 1994). Since healthy wombats which were captured and restrained had high concentrations of aspartate aminotransferase and creatine kinase (L. Skerratt, unpubl. obser.), the muscle damage may have been due to the capture, restraint and transport of wombats. Erythrocyte, mean corpuscular hemoglobin, sodium and alkaline phosphatase concentrations were similar in wombats whether or not they had sarcoptic mange, as is the case in rabbits, dogs and foxes (Arlian et al., 1988a, 1995; Little, 1998). Wombats with severe hyperkeratotic sarcoptic mange, reported by Skerratt (1998), had similar internal and external parasites to those reported here, although prevalences and intensities of infection differed. Sker-

ratt (1998) found that the number of species of internal parasites and intensity of infection did not differ between wombats with severe sarcoptic mange and healthy wombats. However, he did find that wombats with mange had fewer species of ectoparasites than healthy wombats. In summary, *S. scabiei* are more abundant in anterolateral areas of the wombat's skin, are highly correlated with thickness of scale crust and degree of alopecia, cause emaciation when numerous and predispose wombats to bacterial infection.

ACKNOWLEDGMENTS

L. Berger, D. Harms, K. Steinmann, L. Steinmann and M. Twaddle are especially thanked for their help with field work. R. Martin and K. Handasyde also are thanked for their help with field work and their enthusiastic support of this study. C. Andersen is thanked for her help with bleeding captive wombats. We are grateful to D. Presidente and T. Smith for their clinical pathological work on wombats. J. Phelan, P. Holz and J. Ferguson are especially acknowledged along with staff of Healesville Sanctuary, B. Shenfield, J. Enfeld, J. Jackson, R. Wilcox, R. Withers, M. Booker and staff of Kinglake National Park for providing many wombats. J. Jackson is also acknowledged for identifying ticks. J. Robertson at Murdoch University is thanked for performing electrophoretograms and B. Rich is thanked for his help with their interpretation. G. Anderson is thanked for his help with statistical analysis and P. Clark is thanked for his comments on the manuscript. L. Skerratt was supported by an Australian Postgraduate Award. This project was funded by the Holsworth Wildlife Research Fund and we thank W. N. Holsworth for his support.

LITERATURE CITED

- ALADOS, C. L., J. M. ESCOS, AND J. M. EMLÉN. 1996. Fractal structure of sequential behaviour patterns: An indicator of stress. *Animal Behaviour* 51: 437–443.
- ARLIAN, L. G., R. A. RUNYAN, S. ACHAR, AND S. A. ESTES. 1984. Survival and infestivity of *Sarcoptes scabiei* var. *canis* and var. *hominis*. *Journal of the American Academy of Dermatology* 11: 210–215.
- , M. AHMED, AND D. L. VYSZENSKI-MOHER. 1988a. Effects of *S. scabiei* var. *canis* (Acari: Sarcoptidae) on blood indexes of parasitized rabbits. *Journal of Medical Entomology* 25: 360–369.
- , D. L. VYSZENSKI-MOHER, AND D. L. V. MOHER. 1988b. Life cycle of *Sarcoptes scabiei* var. *canis*. *The Journal of Parasitology* 74: 427–430.
- . 1989. Biology, host relations, and epidemiology of *Sarcoptes scabiei*. *Annual Review of Entomology* 34: 139–161.
- , D. L. VYSZENSKI-MOHER, AND M. J. POLE. 1989. Survival of adults and developmental stages of *Sarcoptes scabiei* var. *canis* when off the host. *Experimental and Applied Acarology* 6: 181–187.
- , R. H. BRUNER, R. A. STUHLMAN, M. AHMED, D. L. VYSZENSKI-MOHER, AND D. L. V. MOHER. 1990. Histopathology in hosts parasitized by *Sarcoptes scabiei*. *The Journal of Parasitology* 76: 889–894.
- , M. S. MORGAN, C. M. RAPP, AND D. L. VYSZENSKI-MOHER. 1995. Some effects of sarcoptic mange on dogs. *The Journal of Parasitology* 81: 698–702.
- BAKER, F. J., AND R. E. SILVERTON. 1985. Introduction to medical laboratory medicine, 6th Edition, Butterworth & Co, Sydney, New South Wales, Australia, 408 pp.
- BARKER, I. K., I. BEVERIDGE, A. J. BRADLEY, AND A. K. LEE. 1978. Observations on spontaneous stress-related mortality among males of the dasyurid marsupial *Antechinus stuartii* Macleay. *Australian Journal of Zoology* 26: 435–447.
- BARTLEY, W. C., AND K. MELLANBY. 1944. The parasitology of human scabies (women and children). *Parasitology* 35: 207–208.
- BURGESS, I. 1994. *Sarcoptes scabiei* and scabies. *Advances in Parasitology* 33: 235–292.
- DAVIS, D. P., AND R. D. MOON. 1990. Density, location, and sampling of *Sarcoptes scabiei* (Acari: Sarcoptidae) on experimentally infested pigs. *Journal of Medical Entomology* 27: 391–398.
- DOUBE, L. J. 1982. Diseases of wombats. In *Wildlife diseases of the Pacific Basin and other countries*. Proceedings of the 4th International Conference of the Wildlife Disease Association. M. E. Fowler (ed.). Wildlife Disease Association, Fruitridge Printing, Sacramento, California, pp. 63–75.
- DUNCAN, J. R., K. W. PRASSE, AND E. A. MAHAFFEY. 1994. *Veterinary laboratory medicine*. Iowa State University Press, Ames, Iowa, 300 pp.
- FAIN, A. 1968. Étude de la variabilité de *Sarcoptes scabiei* avec une revision des Sarcoptidae. *Acta Zoologica Pathologica Antverpiensia* 47: 1–196.
- HEILESEN, B. 1946. Studies on *Acarus scabiei* and scabies. *Acta Dermato-Venereologica (Supplementum 14)* 26: 1–370.
- JOHNSON, C. G., AND K. MELLANBY. 1942. The parasitology of human scabies. *Parasitology* 34: 285–290.
- JUBB, K. V. F., P. C. KENNEDY, AND N. PALMER. 1993. *Pathology of domestic animals*, Vol. 3, 4th

- Edition. Academic Press, Sydney, New South Wales, Australia, 653 pp.
- LITTLE, S. E., W. R. DAVIDSON, P. M. RAKICH, T. L. NIXON, D. I. BOUNOUS, AND V. F. NETTLES. 1998. Responses of red foxes to first and second infection with *Sarcoptes scabiei*. *Journal of Wildlife Diseases* 34: 600–611.
- MARTIN, R., K. HANDASYDE, AND L. F. SKERRATT. 1998. Current distribution of sarcoptic mange in wombats. *Australian Veterinary Journal* 76: 411–414.
- MCILROY, J. C. 1973. Aspects of the ecology of the common wombat, *Vombatus ursinus* (Shaw, 1800). Ph.D. Thesis, Australian National University, Canberra, Australian Capital Territory, Australia, 286 pp.
- NESTE, D. V., AND J. M. LACHAPPELLE. 1981. Host-parasite relationships in hyperkeratotic (Norwegian) scabies: pathological and immunological findings. *British Journal of Dermatology* 105: 667–678.
- PENCE, D. B., L. A. WINDBERG, B. C. PENCE, AND R. SPROWLS. 1983. The epizootiology and pathology of sarcoptic mange in coyotes *Canis latrans* from south Texas. *The Journal of Parasitology* 69: 1100–1115.
- PRESIDENTE, P. J. A., AND J. CORREA. 1981. Haematology, plasma electrolytes and serum biochemical values of *Trichosurus vulpecula* (Kerr) (Marsupialia: Phalangeridae). *Australian Journal of Zoology* 29: 507–517.
- . 1982. Common wombat *Vombatus ursinus*: maintenance in captivity, blood values, infectious and parasitic diseases. *In* The management of Australian mammals in captivity: Proceedings of the Scientific Meeting of the Australian Mammal Society, D. D. Evans (ed.). The Zoological Board of Victoria, Melbourne, Victoria, Australia pp. 133–143.
- SKERRATT, L. F. 1998. Diseases and parasites of the common wombat *Vombatus ursinus* in the Healesville area of Victoria. *In* Wombats. R. Wells and P. Pridmore (eds.). Surrey Beatty & Sons, Chipping Norton, South Australia, Australia, pp. 317–328.
- , R. MARTIN, AND K. HANDASYDE. 1998. Sarcoptic mange in wombats. *Australian Veterinary Journal* 76: 408–410.
- SOKAL, R. R., AND F. J. ROHLF. 1997. *Biometry*, 3rd Edition. W. H. Freeman and Company, New York, New York, 887 pp.
- SPEARE, R., A. T. HAFFENDEN, P. W. DANIELS, A. D. THOMAS, AND C. D. SEAWRIGHT. 1984. Diseases of the Herbert River ringtail, *Pseudocheirus herbertensis*, and other north Queensland rainforest possums. *In* Possums and gliders. A. P. Smith and I. D. Hume (eds.). Australian Mammal Society, Sydney, New South Wales, Australia, pp. 283–302.
- STRUMIA, M. 1963. A rapid universal blood stain, May-Gruenwald-Giemsa in one solution. *Journal of Laboratory Clinical Medicine* 21: 930.

Received for publication 12 February 1999.