

## **Nasal zygomycosis and pulmonary aspergillosis in an American bison**

Authors: de los Monteros, A. Espinosa, Carrasco, L., King, J. M., and Jensen, H. E.

Source: Journal of Wildlife Diseases, 35(4) : 790-795

Published By: Wildlife Disease Association

URL: <https://doi.org/10.7589/0090-3558-35.4.790>

---

BioOne Complete ([complete.BioOne.org](https://complete.BioOne.org)) is a full-text database of 200 subscribed and open-access titles in the biological, ecological, and environmental sciences published by nonprofit societies, associations, museums, institutions, and presses.

Your use of this PDF, the BioOne Complete website, and all posted and associated content indicates your acceptance of BioOne's Terms of Use, available at [www.bioone.org/terms-of-use](https://www.bioone.org/terms-of-use).

Usage of BioOne Complete content is strictly limited to personal, educational, and non - commercial use. Commercial inquiries or rights and permissions requests should be directed to the individual publisher as copyright holder.

---

BioOne sees sustainable scholarly publishing as an inherently collaborative enterprise connecting authors, nonprofit publishers, academic institutions, research libraries, and research funders in the common goal of maximizing access to critical research.

## Nasal zygomycosis and pulmonary aspergillosis in an American bison

A. Espinosa de los Monteros,<sup>1</sup> L. Carrasco,<sup>2</sup> J. M. King,<sup>3</sup> and H. E. Jensen<sup>4,5</sup> <sup>1</sup> Department of Comparative Pathology, Veterinary Faculty, University of Las Palmas de Gran Canaria. Trasmontana, 35416 Arucas, Las Palmas de Gran Canaria, Spain; <sup>2</sup> Department of Anatomy and Comparative Pathology, Veterinary Faculty, University of Córdoba, Avda Medina Azhara s/n, 14005-Córdoba, Spain; <sup>3</sup> Department of Pathology, New York State College of Veterinary Medicine, S2 110 Schurman Hall, Cornell University, Ithaca, New York 14853, USA; <sup>4</sup> Department of Pharmacology and Pathobiology, Royal Veterinary and Agricultural University, 17 Bülowsvej, DK-1870 Frederiksberg C, Denmark; <sup>5</sup> Corresponding author (e-mail: HELJ@KVL.dk).

**ABSTRACT:** Concomitant nasal zygomycosis and pulmonary aspergillosis was diagnosed in a 3-mo-old female American bison calf (*Bison bison*) in Pennsylvania (USA). Etiologic diagnosis was made by immunohistochemistry using a panel of monoclonal antibodies and heterologously absorbed polyclonal antibodies. In the lungs fungal infection was accompanied by hemorrhage, fibrin exudation, and infiltration with neutrophils. Fungi were observed to penetrate apparently normal epithelial lining of the nasal turbinates, and there was hemorrhage, edema, and invasion of blood vessels in the submucosa. In vessels fungi were typically associated with thrombosis. The calf may have been infected due to a high level of exposure to mouldy feed and litter in the environment in combination with a collapse of its natural defence mechanisms.

**Key words:** American bison, *Bison bison*, case report, nasal zygomycosis, pulmonary aspergillosis.

Zygomycosis is a unifying term that includes a diverse group of mycotic diseases caused by fungi of the class Zygomycetes (Rippon, 1988). Fungi of the orders Entomophthorales cause localized subcutaneous granulomas and Mucorales cause angioinvasion (Cordes and Shortridge, 1968; Smith 1989). Zygomycosis produced by species in Mucorales, is the most common fungal infection of the alimentary tract of ruminants, especially the forestomachs (Jensen et al., 1994). *Aspergillus* causes placentitis and respiratory infections (Chihaya et al., 1991). However, in recent years concomitant digestive zygomycosis and respiratory aspergillosis in calves and cows also have been observed (Jensen et al., 1989a; Chihaya et al., 1991, 1992a; Jensen et al., 1994)

Most studies of ruminant mycosis have

focused on infections of domestic animals. However, gastrointestinal zygomycosis has been described in gazelle (*Gazella dorcas*) (Marcato and Dimou, 1962), okapi (*Okapia johnstoni*) (Campbell, 1967), buffalo (*Bubalis bubalis*) (Kharole et al., 1976) and camels (*Camelus dromedarius*) (Satir et al., 1993); nasal zygomycosis has been reported in llama (*Lama glama*) (French and Ashworth, 1994); and there are some cases of systemic zygomycosis, with affection of various organs such as kidney, liver, and the central nervous system in deer (*Cervus elaphus*) (Munro et al., 1984). Pulmonary aspergillosis has been described in deer (Barre et al., 1977; Munro and Hunter, 1983, Jensen et al., 1989b) and camels (Elkhouly et al., 1992), and systemic aspergillosis has been described in alpaca (*Lamos pacos*) (Pickett et al., 1985; Severo et al., 1989) in which granulomatous lesions were observed in lungs and kidneys.

In the present paper, the observation of concomitant nasal zygomycosis and pulmonary aspergillosis in an American bison (*Bison bison*) is reported. The aetiological diagnosis was upheld immunohistochemically by the application of a panel of monoclonal and polyclonal antibodies in different, indirect immunohistochemical assays.

In a herd of 255 American bison at Union Dale (Pennsylvania, USA; 41°43'N, 75°30'W) a 3-mo-old female calf with normal body condition was found weak in the pasture with a temperature of 40 C. Lung sounds were harsh and the breathing was somewhat forced. The animal was treated with Cesftiofur sodium (Pharmacia Up-

john, Kalamazoo, Michigan, USA), Selenium and vitamin E (BO-SE) (Schering Plough Animal Health Corp., Kenilworth, New Jersey, USA), and vitamin B<sub>12</sub> (The Butler Company, Columbus, Ohio, USA). Oral supplementation was given with either calf milk replacer (AGWAY, Ithaca, New York, USA) or goat milk. On the second day of illness, the calf was severely depressed, recumbent, and developed diarrhea. The body temperature declined and lung sounds were harsh. The animal was fed on goat milk and treated with electrolytes and dextrose intravenously. The animal died and a postmortem examination was performed.

Macroscopic lesions were recorded and tissue samples from the nasal cavity, lungs, heart, kidneys, liver, spleen, forestomachs, intestines, uterus, and brain were collected and fixed in 10% buffered formalin, embedded in paraffin, sectioned at 3–4  $\mu\text{m}$ , and stained with hematoxylin and eosin, periodic acid-Schiff (PAS), and Grocott's methenamine silver (GMS) (Bancroft and Stevens, 1996). For immunohistochemical staining, sections were mounted on poly-L-lysine-coated slides and processed as described elsewhere (Jensen et al., 1996a, b).

As primary reagents in immunohistochemistry we used two monoclonal antibodies (Mabs) reacting specifically with antigens of aspergillosis Mab-WF-AF-1 (DAKO, Glostrup, Denmark, M3564) and zygomycosis caused by members of the order Mucorales Mab-WSSA-RA-1 (DAKO, Glostrup, Denmark, M3565) (Jensen et al., 1996a, b). The Mabs were used together with genus specific polyclonal antibodies raised against *Aspergillus fumigatus*, *Absidia corymbifera*, *Candida albicans*, *Geotrichum candidum*, *Fusarium solani*, and *Scedosporium apiospermum* (anamorph of *Pseudallescheria boydii*) (Jensen et al., 1997). The monoclonal antibodies were either used in a three-layer indirect enzyme immunohistochemical technique using alkaline phosphatase antialkaline phosphatase (APAAP) immunocomplexes or in an indirect immunofluorescence (IIF) tech-

nique (Jensen et al., 1996b). The polyclonal antibodies were applied in a peroxidase anti-peroxidase (PAP) technique (Jensen et al., 1996a, b). As a substrate, fast red was used in the APAAP technique, whereas 3-amino-9-ethylencarbazole (AEC) was used in the PAP technique (Jensen et al., 1996a, b). Sections were counterstained in Harris hematoxylin for 5 to 10 sec before reading.

For bacteriological examination, samples from the lungs were submitted to the Diagnostic Laboratory in the New York State College of Veterinary Medicine (Cornell University, Ithaca, New York, USA). Tissue was streaked onto blood agar plates (5% calf blood). After inoculation, the plates were incubated for 6 days in a normal atmosphere at 37 C. No attempts were made for isolation of fungi.

At necropsy of the bison calf, 300 ml of serosanguinous fluid were in the abdominal cavity, and the liver was soft and pale. Multiple (>100) black nodules with white centers were scattered throughout the lungs. The nodules were firm and 1 to 2 mm in diameter. The nasal mucosa was congested and dark red. Other lesions were not observed during gross examination.

Histologically, severe congestion, multiple hemorrhages, and marked edema of the submucosa of nasal turbinates were seen. In such areas numerous fungal hyphae were observed in the connective tissue of the submucosa, and they tend to invade the vascular walls and proliferated within vessels resulting in the formation of thrombi (Fig. 1). Hyphae also were present in the lumen of the nasal cavity and were observed to cross the apparently normal epithelium (Fig. 2). The hyphae observed in the nasal structures were from 8 to 12  $\mu\text{m}$  in diameter, mostly non-septated, and had a variable pattern of branching.

The lungs contained multifocal lesions that tend to have a lobular distribution. The lesions were characterized by necrosis, hemorrhage, and fibrin deposits, which

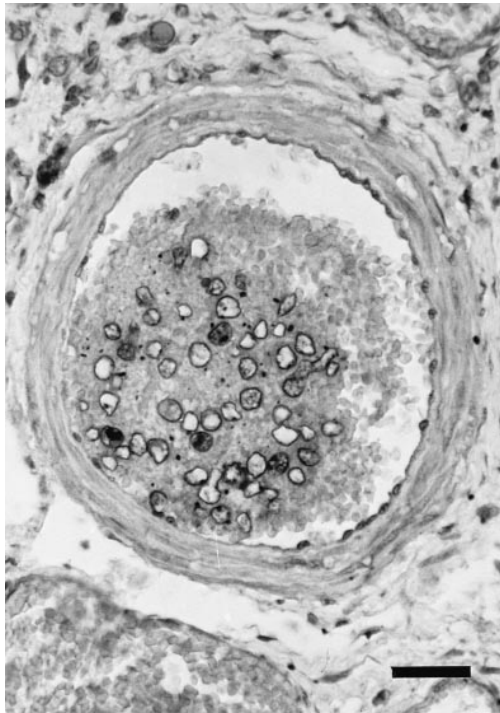


FIGURE 1. Nasal submucosa of an American bison from Pennsylvania (USA) showing numerous cross sectioned zygomycotic hyphae within a thrombosed vessel. For the staining Mab-WSSA-RA-1 was used in an APAAP technique. Bar = 25  $\mu$ m.

were accompanied by infiltration of neutrophils and macrophages. Deposits of fibrin were also observed on the pleural surface. In the pneumonic areas fibrin thrombi and dilatation of lymphatic vessels in the interlobular connective tissue often were present. A large number of branching, mostly septate fungal hyphae with a diameter from 5 to 8  $\mu$ m were within alveoli, on the pleural surface, and in the wall and lumen of capillaries and medium caliber vessels.

Fungi within nasal and pulmonary lesions reacted strongly with the Mab-WSSA-RA-1 and Mab-WF-AF-1, respectively. In these lesions a positive reaction also was upheld by the polyclonal antibodies raised against *A. corymbifera* and *A. fumigatus*, respectively, whereas no reaction was obtained when other antibodies were applied. Thus, the nasal lesions were identified as zygomycosis (Figs. 1, 2), and

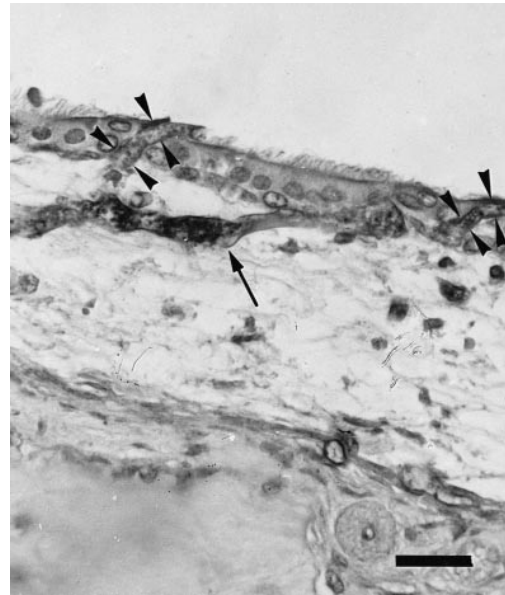


FIGURE 2. Nasal mucosa and submucosa of an American bison showing hyphae within the submucosa (arrow) and others penetrating the apparently normal epithelium (arrow heads). For the staining Mab-WSSA-RA-1 was used in an APAAP technique. Bar = 25  $\mu$ m.

the pulmonary lesions were aspergillosis (Fig. 3).

Other lesions observed histologically were moderate hydropic degeneration of hepatocytes, mild chronic enteritis with eosinophils associated with coccidial schizonts, depletion of Peyer's patches in the small intestine, and a chronic enteritis in the large intestine. Moderate numbers of *Pseudomonas aeruginosa* were cultured from the lungs.

Acute concomitant nasal zygomycosis and pulmonary aspergillosis in an American bison are described. Fungal elements were in the nasal mucosa and lungs and both aspergilli and zygomycetes were often seen within vessels accompanied by thrombosis.

Nasal zygomycosis in ruminants has only been reported in a few species, including sheep (Carrigan et al., 1992; Ketterer et al., 1992) and llamas (French and Ashworth, 1994). Inhalation of a high level of fungal spores, while the animals were fed

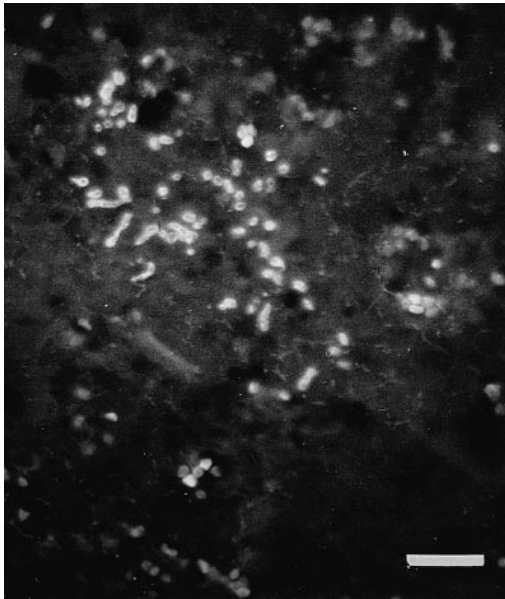


FIGURE 3. Lung tissue from an American bison with fungal hyphae reacting immunohistochemically with a monoclonal antibody (Mab-WF-AF-1) reacting with *Aspergillus* sp. For the staining the IIF technique was used. Bar = 25  $\mu$ m.

has been proposed as a likely route of such infections (Carrigan et al., 1992; Ketterer et al., 1992). A similar situation also may have been the cause of the airway contamination and infection in the present case because the bison were fed on the ground. However, the mycotic lesions observed in the nasal mucosa were acute (Shalev et al., 1977; Jensen et al., 1989a, 1994; Chihaya et al., 1991, 1992a, b; Carrasco et al., 1993, 1997). This is quite different from previous descriptions of nasal zygomycosis in ruminants which are typically deforming nasal structures (Carrigan et al., 1992; Ketterer et al., 1992; French and Ashworth, 1994). This difference may be due to the fact that our case was caused by fungi of the order Mucorales, whereas former ones have been caused by fungi of the order Entomophthorales (Carrigan et al., 1992; Ketterer et al., 1992; French and Ashworth, 1994).

Pulmonary mycosis in cows is usually due to aspergillosis and related to the inhalation of spores from mouldy litter and

feed (Eggert and Romberg, 1960; Griffin, 1969; Jensen et al., 1994). Pulmonary aspergillosis in cows, deer, and llamas, is usually in the form of abscesses having a small diameter and being scattered throughout the lung parenchyma (Eggert and Romberg, 1960; Griffin, 1969; Barre et al., 1977; Pickett et al., 1985; Severo et al., 1989; Chihaya et al., 1991). However, in our case the pulmonary lesions were characterized by hemorrhages, fibrinous exudate, necrosis, thrombosis, and minimal inflammatory reaction which is similar to previously described cases of invasive pulmonary aspergillosis in cows (Chihaya et al., 1992b), camels (El-khouly et al., 1992), and horses (Slocombe and Slauson, 1988; Pace et al., 1994; Rosenstein and Mullaney, 1996; Carrasco et al., 1997).

Agents of aspergillosis and zygomycosis are opportunistic pathogens, and predisposing factors seem to be required before infection is established (Jensen et al., 1994). Important predisposing factors are prolonged treatment with antimicrobial drugs and damage of the epithelial lining of the gastrointestinal canal (Jensen et al., 1989a, 1994). However, the fact that the bison calf was not treated with antimicrobial drugs, that there was a penetration of apparently normal epithelium by hyphae, that a dual infection was diagnosed, and the other animals in the herd remained uninfected all suggest that high exposure to fungal spores in combination with a collapse of its natural defence mechanisms in this calf facilitated establishment of these fungal infections.

#### LITERATURE CITED

- BANCROFT, J. D., AND A. STEVENS. 1996. Theory and practice of histological techniques, 4th Edition Churchill Livingstone, New York, New York, 766 pp.
- BARRE, N., M. LAHELLEC, J. PENNEC, C. MAURIER, AND S. CHARPENTIER. 1977. Un cas di' aspergillose pulmonaire chez un chevreuil. *Recueil de Medicine Veterinaire* 153: 269-271.
- CAMPBELL, C. K. 1967. Microbiological investigation into the death of two young okapis (*Okapia johnstoni* Sclater). *Sabouraudia* 5: 159-164.
- CARRASCO, L., M. A. SIERRA, H. SCHØNHEYDER, AND

- H. E. JENSEN. 1993. Ovine ruminal and abomasal zygomycosis. *Small Ruminant Research* 10: 357–362.
- , L., M. C. TARRADAS, J. C. GOMEZ-VILLAMANDOS, I. LUQUE, A. ARENAS, AND A. MENDEZ. 1997. Equine pulmonary mycosis due to *Aspergillus niger* and *Rhizopus stolonifer*. *Journal of Comparative Pathology* 117: 191–197.
- CARRIGAN, M. J., A. C. SMALL, AND G. H. PERRY. 1992. Ovine nasal zygomycosis caused by *Conidiobolus incongruus*. *Australian Veterinary Journal* 69: 237–240.
- CHIHAYA, Y., Y. FURUSAWA, H. OKADA, K. MATSUKAWA, AND Y. MATSUI. 1991. Pathological studies on systemic mycoses in calves. *Journal of Veterinary Medical Science* 53: 1051–1058.
- , K. MATSUKAWA, K. OHSHIMA, Y. MATSUI, K. OGASA, Y. FURUSAWA, AND H. OKADA. 1992a. A pathological study of bovine alimentary mycosis. *Journal of Comparative Pathology* 107: 195–206.
- , H. OKADA, K. MATSUKAWA, AND Y. MATSUI. 1992b. Disseminated mycoses in cattle. A study on nine autopsy cases. *Journal of Veterinary Medical Science* 54: 485–491.
- CORDES, D. O., AND E. H. SHORTRIDGE. 1968. Systemic phycomycosis and aspergillosis of cattle. *New Zealand Veterinary Journal* 16: 65–80.
- EGGERT, M. J., AND P. F. ROMBERG. 1960. Pulmonary aspergillosis in a calf. *Journal of the American Veterinary Medical Association* 137: 595–596.
- EL-KHOULY, A., F. A. GADIR, D. D. CLUER, AND G. W. MANEFIELD. 1992. Aspergillosis in camels affected with a specific respiratory and enteric syndrome. *Australian Veterinary Journal* 69: 182–186.
- FRENCH, R. A., AND C. D. ASHWORTH. 1994. Zygomycosis caused by *Conidiobolus coronatus* in a llama (*Lama glama*). *Veterinary Pathology* 31: 120–122.
- GRIFFIN, R. M. 1969. Pulmonary aspergillosis in the calf. *Veterinary Record* 84: 109–111.
- JENSEN, H. E. 1994. Systemic bovine aspergillosis and zygomycosis in Denmark with reference to pathogenesis, pathology, and diagnosis. *Acta Pathologica, Microbiologica et Immunologica Scandinavica (Suppl. 42)* 102: 5–48.
- , A. BASSE, AND B. AALBÆK. 1989a. Mycosis in the stomach compartments of cattle. *Acta Veterinaria Scandinavica* 30: 409–423.
- , J. B. JØRGENSEN, AND H. SCHØNHEYDER. 1989b. Pulmonary mycosis in farmed deer: Allergic zygomycosis and invasive aspergillosis. *Journal of Medical and Veterinary Mycology* 27: 329–334.
- , S. N. OLSEN, AND B. AALBÆK. 1994. Gastrointestinal aspergillosis and zygomycosis of cattle. *Veterinary Pathology* 31: 28–36.
- , B. AALBÆK, P. LIND, AND H. V. KROGH. 1996a. Immunohistochemical diagnosis of systemic bovine zygomycosis by murine monoclonal antibodies. *Veterinary Pathology* 33: 176–183.
- , B. AALBÆK, P. LIND, H. V. KROGH, AND P. L. FRANSDEN. 1996b. Development of murine monoclonal antibodies for the immunohistochemical diagnosis of systemic bovine aspergillosis. *Journal of Veterinary Diagnostic Investigation* 8: 68–75.
- , J. SALONEN, AND T. O. EKFOR. 1997. The use of immunohistochemistry to improve sensitivity and specificity in the diagnosis of systemic mycoses in patients with haematological malignancies. *Journal of Pathology* 81: 100–105.
- KETTERER, P. J., M. A. KELLY, M. D. CONNOLE, AND L. AJELLO. 1992. Rhinocerebral and nasal zygomycosis in sheep caused by *Conidiobolus incongruus*. *Australian Veterinary Journal* 69: 85–87.
- KHAROLE, M. U., P. P. GUPTA, B. SINGH, P. C. MANDAL, AND D. S. HOTH. 1976. Phycomycotic gastritis in buffalo calves (*Bubalis bubalis*). *Veterinary Pathology* 13: 409–413.
- MARCATO, P. S., AND D. DIMOU. 1962. Su un caso di mucormycosi del ruminante in una gazella. *Nuova Veterinaria* 38: 279–287.
- MUNRO, R., AND A. R. HUNTER. 1983. Histopathological findings in the lungs of Scottish red and roe deer. *Veterinary Record* 112: 194–197.
- , ——— M. BONNIWELL, AND W. CORRIGAL. 1984. Systemic mycosis in Scottish red deer (*Cervus elaphus*). *Journal of Comparative Pathology* 95: 281–289.
- PACE, L. W., N. R. WIRTH, R. R. FOSS, AND W. H. FALES. 1994. Endocarditis and pulmonary aspergillosis in a horse. *Journal of Veterinary Diagnostic Investigation* 6: 504–506.
- PICKETT, J. P., C. P. MOORE, B. A. BEEHLER, A. GENDRON-FITZPATRICK, AND R. R. DUBIELZIG. 1985. Bilateral chorioretinitis secondary to disseminated aspergillosis in an alpaca. *Journal of the American Veterinary Medical Association* 187: 1241–1243.
- RIPPON, J. W. 1988. *Medical mycology: The pathogenic fungi and the pathogenic actinomycetes*. W. B. Saunders Company, Philadelphia, Pennsylvania, 797 pp.
- ROSENSTEIN, D. S., AND T. P. MULLANEY. 1996. Acute pulmonary aspergillosis and severe enterocolitis in a quarter horse mare. *Equine Veterinary Education* 8: 200–203.
- SATIR, A. A., M. I. ABU BAKR, A. ABALKHAIL, A. E. ABDEL GHAFAR, AND A. E. BABIKER. 1993. Phycomycosis of the abomasum in *Camelus dromedarius*. *Journal of Veterinary Medicine Series* 40(A): 672–675.
- SEVERO, L. C., J. C. BOHRER, G. R. GEYER, AND L. FERREIRO. 1989. Invasive aspergillosis in an alpaca (*Lamas pacos*). *Journal of Medical and Veterinary Mycology* 27: 193–195.

- SHALEV, M., J. C. MURPHY, AND J. G. FOX. 1977. Mycotic enteritis in a chamaleon and a brief review of phycomycoses of animals. *Journal of the American Veterinary Medical Association* 171: 872-875.
- SLOCOMBE, R. F., AND D. O. SLAUSON. 1988. Invasive pulmonary aspergillosis of horses: An association with acute enteritis. *Veterinary Pathology* 25: 277-281.
- SMITH, J. M. B. 1989. *Opportunistic mycoses of man and animals*. C.A.B. International, BPCC Wheastons Ltd., Exeter, UK, 251 pp.

*Received for publication 24 October 1998.*