

Tuberculosis in a Wild Subantarctic Fur Seal from Argentina

Authors: Bastida, Ricardo, Loureiro, Julio, Quse, Viviana, Bernardelli, Amelia, Rodríguez, Diego, et al.

Source: Journal of Wildlife Diseases, 35(4) : 796-798

Published By: Wildlife Disease Association

URL: <https://doi.org/10.7589/0090-3558-35.4.796>

BioOne Complete (complete.BioOne.org) is a full-text database of 200 subscribed and open-access titles in the biological, ecological, and environmental sciences published by nonprofit societies, associations, museums, institutions, and presses.

Your use of this PDF, the BioOne Complete website, and all posted and associated content indicates your acceptance of BioOne's Terms of Use, available at www.bioone.org/terms-of-use.

Usage of BioOne Complete content is strictly limited to personal, educational, and non - commercial use. Commercial inquiries or rights and permissions requests should be directed to the individual publisher as copyright holder.

BioOne sees sustainable scholarly publishing as an inherently collaborative enterprise connecting authors, nonprofit publishers, academic institutions, research libraries, and research funders in the common goal of maximizing access to critical research.

Tuberculosis in a Wild Subantarctic Fur Seal from Argentina

Ricardo Bastida,^{1,2,3,6} Julio Loureiro,² Viviana Quse,² Amelia Bernardelli,⁴ Diego Rodríguez,^{1,2,3} and Enrique Costa⁵ ¹ Departamento de Ciencias Marinas, Facultad de Ciencias Exactas y Naturales, Universidad Nacional de Mar del Plata. Casilla de Correos 43, (7600) Mar del Plata, Argentina; ² Fundación Mundo Marino, San Clemente del Tuyú, Argentina; ³ Consejo Nacional de Investigaciones Científicas y Técnicas (CONICET), Buenos Aires, Argentina; ⁴ Servicio Nacional de Sanidad y Calidad Agroalimentaria, Buenos Aires, Argentina; ⁵ Instituto de Patología Bernardo Epstein, La Plata, Argentina; ⁶ Corresponding author (e-mail: rbastida@mdp.edu.ar).

ABSTRACT: The first case of tuberculosis is described in a wild subantarctic fur seal (*Arctocephalus tropicalis*) found on the Argentine coast. There was hydrothorax and white firm granulomatous lesions of 40–50 mm in diameter in the lungs. Lesions consisted of a central area of caseous necrosis, an intermediate zone of epithelioid and lymphocytic mononuclear cells, and a peripheral zone of connective tissue. Biochemical and drug sensitivity tests and inoculation of Guinea pigs confirmed the identification as *Mycobacterium tuberculosis* complex. *Arctocephalus tropicalis* is the fifth pinniped species in which the *M. tuberculosis* complex has been detected. Since subantarctic fur seals are widely distributed in the Southern Hemisphere, it is possible that the tuberculosis cases may have a common origin and could spread to other austral regions and species.

Key words: *Arctocephalus tropicalis*, case report, lung disease, *Mycobacterium tuberculosis* complex, pinnipeds, tuberculosis.

Sick and injured marine mammals and birds receive medical treatment in the Fundación Mundo Marino Rehabilitation Center (FMMRC) of San Clemente del Tuyú (Argentina) and are later re-introduced back into their natural environment. The most commonly treated pinnipeds are the southern sea lion (*Otaria flavescens*), the South American fur seal (*Arctocephalus australis*), and the subantarctic fur seal (*Arctocephalus tropicalis*). Most of the animals of the first two species come from breeding colonies found in Uruguay. It is different for the subantarctic fur seals, because this species breeds in oceanic islands immediately north of the antarctic convergence (polar front). The vagrant animals recorded in Argentina probably originated in the colonies of Gough Island (40°20'S, 9°54'W) and were transported to South America by the South Atlantic Gyre (Rodríguez, 1996).

Tuberculosis cases in pinnipeds were first detected in the Australian sea lion (*Neophoca cinerea*) and the New Zealand fur seal (*Arctocephalus forsteri*), in both captive and wild animals (Cousins, 1987; Cousins et al., 1990; Forshaw and Phelps, 1991); all these cases belonged to the *Mycobacterium tuberculosis* complex (TBC), showing unique genomic characteristics (Cousins, 1987; Cousins et al., 1990). Recently Bernardelli et al. (1996) confirmed the presence of this complex in southern sea lions (*Otaria flavescens*) and South American fur seals (*Arctocephalus australis*) from the southwestern Atlantic Ocean. In this paper we report and describe the first case of TBC in a wild subantarctic fur seal.

On 12 May 1996, a subantarctic fur seal was found stranded in San Clemente del Tuyú (Argentina; 36°18'S, 56°46'W); it died during its transportation for medical treatment at the FMMRC. It was an adult male of 166.5 cm long and weighed 86.5 kg. Necropsy was conducted immediately, according to standard protocols for small carnivores (Blood et al., 1986; Jubb et al., 1990).

Samples from all organs were taken for histopathological studies, fixed in 10% formalin, embedded in paraffin, and stained with hematoxylin and eosin following standard procedures (Nezelof et al., 1975). Samples taken for bacteriological studies (lung tissue, lung swab, and lung exudate) were processed by the Petroff decontamination method and inoculated on Lowenstein-Jensen and Stonebrink media (Servicio Nacional de Sanidad y Calidad Agroalimentaria, Buenos Aires, Argentina). Culture isolates were identified by

biochemical, drug sensibility, and biological tests (Kantor, 1979; Kleeberg et al., 1980; Grange and Yates, 1994), and the acid-fast rods stained in Ziehl Neelsen media (Servicio Nacional de Sanidad y Calidad Agroalimentaria). The isolates were injected into Guinea pigs and later tested with intradermic bovine Protein Purified Derivative (PPD) of Bovine Tuberculin (Servicio Nacional de Sanidad y Calidad Agroalimentaria).

Prior to death the subantarctic fur seal was in a very poor physical condition, depressed, dyspneic, indifferent, and not responsive to manual handling. Necropsy confirmed thoracic lesions compatible with tuberculosis. There were 4 to 5 L of yellowish liquid exudate (hydrothorax), and the heart and lungs were covered by a fibrinous tissue. The lungs were of normal size and pale-pink in color. Whitish nodules of 40 to 50 mm diameter were found in both parietal and visceral surfaces of the lungs. These nodules were dry and calcified on cut surfaces. Histologically, lungs had granulomatous lesions with a central area of caseous necrosis, and an intermediate zone composed of epithelioid and lymphocytic mononuclear cells. The lymphocytic cells showed small and dense nuclei and the epithelioid cells had less dense nuclei and abundant eosinophilic cytoplasm. The peripheral zone was composed of connective tissue (Fig. 1). Thoracic lymph nodes were enlarged with caseous and calcified areas evident grossly on cut surfaces; these were later confirmed histopathologically.

Several tests were performed in order to identify the isolates. Bacteriological analyses showed the same etiological agent of the *Mycobacterium tuberculosis* complex. There was slow growth on Stonebrink media (37 C) and positive staining with Ziehl Neelsen stain. In primary isolation the cultures grew in 4 to 8 wk, with acid-fast rods observed in all samples. Negative results were obtained in the following biochemical tests: photochromogenicity, scrotochromogenicity, Tween hydrolysis (3 day, 2

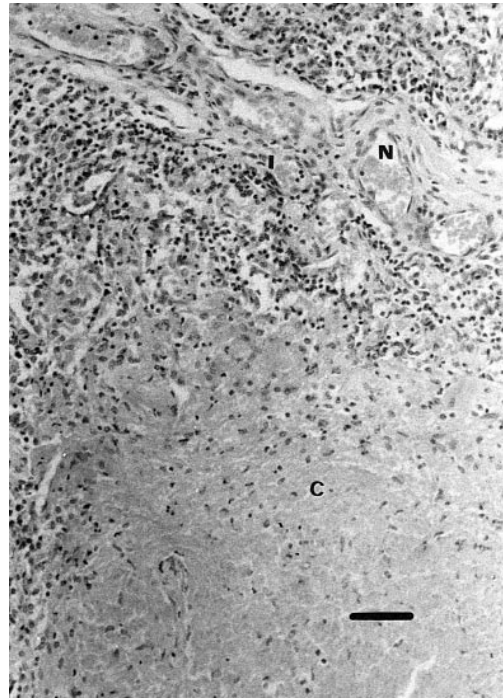


FIGURE 1. Tuberculous granuloma in the fur seal lung, with a caseous necrosis area (N), an intermediate zone (I) composed of epithelioid and lymphocytic mononuclear cells, and peripheral zone of connective tissue (C). H&E. Bar = 40 μ m.

wk), tellurite reduction, arilsulfatase, β -glucosidase, β -galactosidase, catalase (25 and 68 C), semiquantitative catalase test, Niacine production and Nitrate reduction. Sensitivity to Tiophen-2-carboxylic hydrazid was positive. To confirm the tipification, Guinea pigs were IM inoculated with the fur seal isolates (Stonebrink media). Three wk after inoculation 50 IU of *Mycobacterium bovis* PPD tuberculin were injected. This produced a papule surrounded by 17 mm diameter erythema in 24 hr. The Guinea pigs were necropsied 4 wk after the tuberculin test, showing lesions compatible with tuberculosis in the liver. The biochemical and drug sensitivity tests performed on the Guinea pig isolates produced the same test results as those of the fur seal strains.

The probability of identifying and isolating tuberculous animals in wild seal colonies is low, due to the inaccessibility of

most of the rookeries. Infection within a colony could be very high because of the extreme gregariousness of the eared seals, mainly during breeding seasons. The confirmation of this disease in *A. tropicalis* is very important because this species is the most widely distributed fur seal in temperate and subantarctic waters of the Southern Hemisphere and their populations have greatly increased in the last decades (Croxall and Gentry, 1987; Bester, 1990; Hofmeyr et al., 1997). Vagrant seals are recorded in both continental and insular areas in the South Pacific, South Atlantic, and Indian oceans where they are found in association with breeding colonies of five species of fur seals (*Arctocephalus philippi*, *Arctocephalus australis*, *Arctocephalus pusillus*, *Arctocephalus gazella*, and *Arctocephalus forsteri*), three species of sea lions (*Otaria flavescens*, *Neophoca cinerea*, and *Phocarctos hookeri*) and one phocid species (*Mirounga leonina*). This association with other species points out the risk of infection to all the Southern Hemisphere seal species and the possibility that all the TBC cases recorded have a common origin, with *A. tropicalis* representing the link between the different seal species. Also the cross infection between seals and both marine (i.e., killer whales and leopard seals) and terrestrial predators should not be dismissed because, although infrequent, terrestrial carnivores prey on some fur seal species (Riedman, 1990). At present, a cooperative study is being conducted between Australian and Argentine colleagues in order to compare the mycobacterial isolates from different seals and to establish the possible relationship among them.

LITERATURE CITED

- BERNARDELLI, A., R. BASTIDA, J. LOUREIRO, H. MICHELIS, M. I. ROMANO, A. CATALDI, AND E. COSTA. 1996. Tuberculosis in sea lions and fur seals from the south-western Atlantic coast. *Revue Scientifique et Technique du Office International des Epizooties* 15: 985–1005.
- BESTER, M. N. 1990. Population trends of subantarctic fur seals and southern elephant seals at Gough Island. *South African Journal of Antarctic Research* 20: 9–12.
- BLOOD, D. C., J. A. HENDERSON, AND O. M. RADOSTITS. 1986. *Medicina veterinaria*. Nueva Editorial Interamericana, México D. F., México, 502 pp.
- COUSINS, D. V. 1987. ELISA for detection of tuberculosis in seals. *Veterinary Record* 121: 305.
- , B. R. FRANCIS, B. L. GOW, D. M. COLLINS, C. H. MCGLASHAN, A. GREGORY, AND R. M. MACKENZIE. 1990. Tuberculosis in captive seals: Bacteriological studies on an isolate belonging to the *Mycobacterium tuberculosis* complex. *Research in Veterinary Science* 48: 196–200.
- CROXALL, J. P., AND R. L. GENTRY (EDS). 1987. Status, biology and ecology of fur seals National Oceanic and Atmospheric Administration Technical Report 51. Springfield, Illinois, 211 pp.
- FORSHAW, D., AND G. R. PHELPS. 1991. Tuberculosis in a captive colony of pinnipeds. *Journal of Wildlife Diseases* 27: 288–295.
- GRANGE, J. M., AND M. D. YATES. 1994. Guidelines for speciation within the *Mycobacterium tuberculosis* complex. World Health Organization, Veterinary Public Health Unit, WHO/ZOON/94. Geneva, Switzerland, 174 pp.
- HOFMEYR, G. J. G., M. N. BESTER, AND F. C. JONKER. 1997. Changes in population sizes and distribution of fur seals at Marion Island. *Polar Biology* 17: 150–158.
- JUBB, K. V. F., P. C. KENNEDY, AND N. PALMER. 1990. *Patología de los animales domésticos*. Vol. II. Editorial Agropecuaria Hemisferio Sur, Montevideo, Uruguay, 417 pp.
- KANTOR, I. M. 1979. *Bacteriología de la Tuberculosis*. Centro Panamericano de Zoonosis, Oficina Sanitaria Panamericana, Bogotá, Colombia. Oficina Regional de la Organización Mundial de la Salud, Serie Monografía Científicas y Técnicas 11: 1–63.
- KLEEBERG, H. H., H. J. KOORNHOF, AND H. PALMER. 1980. *Laboratory manual of tuberculosis methods*. South African Medical Research Council, Tuberculosis Research Institute, Pretoria, South Africa, 253 pp.
- NEZELOF, C., P. GALLE, AND H. HINGLAIS. 1975. *Exámenes de Laboratorio: Técnicas microscópicas*. Editorial JIMS, Barcelona, Spain, 254 pp.
- RIEDMAN, M. 1990. *The Pinnipeds: seals, sea lions and walruses*. University of California Press, Berkeley, California, 439 pp.
- RODRÍGUEZ, D. 1996. *Biología y ecología de los pinnípedos del sector bonaerense*. Tesis Doctoral, Universidad Nacional de Mar del Plata, Mar del Plata, Argentina, 315 pp.

Received for publication 10 April 1998.