



## **Acute Sarcocystosis in a Captive White-tailed Deer in Virginia**

Authors: Duncan, R. B., Fox, J. H., Lindsay, D. S., Dubey, J. P., and Zuccaro, M. E.

Source: Journal of Wildlife Diseases, 36(2) : 357-361

Published By: Wildlife Disease Association

URL: <https://doi.org/10.7589/0090-3558-36.2.357>

---

BioOne Complete ([complete.BioOne.org](https://complete.BioOne.org)) is a full-text database of 200 subscribed and open-access titles in the biological, ecological, and environmental sciences published by nonprofit societies, associations, museums, institutions, and presses.

Your use of this PDF, the BioOne Complete website, and all posted and associated content indicates your acceptance of BioOne's Terms of Use, available at [www.bioone.org/terms-of-use](https://www.bioone.org/terms-of-use).

Usage of BioOne Complete content is strictly limited to personal, educational, and non - commercial use. Commercial inquiries or rights and permissions requests should be directed to the individual publisher as copyright holder.

---

BioOne sees sustainable scholarly publishing as an inherently collaborative enterprise connecting authors, nonprofit publishers, academic institutions, research libraries, and research funders in the common goal of maximizing access to critical research.

# SHORT COMMUNICATIONS

*Journal of Wildlife Diseases*, 36(2), 2000, pp. 357–361  
© Wildlife Disease Association 2000

## Acute Sarcocystosis in a Captive White-tailed Deer in Virginia

R. B. Duncan, Jr.,<sup>1,4</sup> J. H. Fox,<sup>1</sup> D. S. Lindsay,<sup>1</sup> J. P. Dubey,<sup>2</sup> and M. E. Zuccaro<sup>3</sup> <sup>1</sup> Department of Biomedical Sciences and Pathobiology, Virginia-Maryland College of Veterinary Medicine, Blacksburg, Virginia, 24061, USA; <sup>2</sup> United States Department of Agriculture, Agricultural Research Service Livestock and Poultry Sciences Institute, Parasite Biology and Epidemiology Laboratory, Beltsville, Maryland, 20705, USA; <sup>3</sup> Brook Run Animal Clinic, Richmond, Virginia, 23227, USA; <sup>4</sup> Corresponding author (e-mail: duncanr@vt.edu).

**ABSTRACT:** A 19-mo-old female captive white-tailed deer in a public wild animal park in Richmond (Virginia, USA) was necropsied and evaluated histologically following spontaneous death after a 1 wk period of lethargy in a captive herd of 22 deer. An acute necrotizing pneumonia was associated with intraendothelial protozoal schizonts that were identified immunohistochemically as *Sarcocystis* spp. This is the first confirmed report of acute sarcocystosis in a wild ruminant.

**Key words:** Case report, *Odocoileus virginianus*, pneumonia, *Sarcocystis* spp., sarcocystosis, schizonts, white-tailed deer.

A private veterinary practitioner performed a necropsy on a 19-mo-old female white-tailed deer (*Odocoileus virginianus*), housed in a public wild animal park in Richmond, (Virginia, USA; 77°30'N; 37°30'W). The deer died following a 1 wk period of lethargy characterized by standing by itself and separation from 21 other deer in the herd. The deer were held in a 1/4 ha fenced enclosure with six bison (*Bison bison*) and the animals were hand fed a grain mixture and mixed grass hay. A stream that ran through the enclosure served as the water source. At necropsy, 11 ml of clear yellow fluid was present in the pericardial space. No other significant findings were noted.

Samples of lung, liver, kidney, small intestine, colon, abomasum, and heart were collected, fixed in 10% buffered neutral formalin, and submitted for histopathological examination. The tissues were routinely processed, embedded in paraffin, sectioned at 5  $\mu$ m, and stained with hematoxylin and eosin. Additionally, tissue sections were subjected to immunohistochemistry with three polyclonal rabbit antisera, each specific for *Sarcocystis cruzi*, *Toxoplasma gon-*

*dii*, and *Neospora caninum*, respectively, using previously described methods (Lindsay and Dubey, 1989; Dubey et al., 1991).

Histologically, significant lesions were limited to the lung, heart, liver, and kidney (Figs. 1, 2). Sections of lung had marked diffuse alveolar congestion and alveolar lumens were filled with homogenous eosinophilic material consistent with edema. There was acute multifocal necrosis of alveolar walls with pyknosis, karyorrhexis, and microthrombosis. Many alveolar capillary endothelial cells had large protozoal schizonts containing 1–2  $\mu$ m diameter merozoites. A schizont was identified in the cytoplasm of an endothelial cell in a muscular coronary artery. The liver had several small foci of necrosis that were associated with neutrophilic infiltration and there were numerous scattered individual hepatocytes that were necrotic. Schizonts were present in glomerular capillaries and arterioles. There was occasional random multifocal necrosis and microthrombosis of several capillary tufts. Sarcocystosis was suspected based on light microscopy and organisms were definitively identified as *Sarcocystis* sp. by immunohistochemistry based on reactivity with *S. cruzi* antiserum, and lack of reactivity with *T. gondii* or *N. caninum* antisera.

*Sarcocystis* spp. are apicomplexan parasites that have a two host life cycle (Dubey et al., 1989). The intermediate host is usually a herbivore or an omnivore, while the definitive host is usually a carnivore or omnivore. The intermediate host becomes infected by ingesting sporocysts in food or water that has been contaminated by the

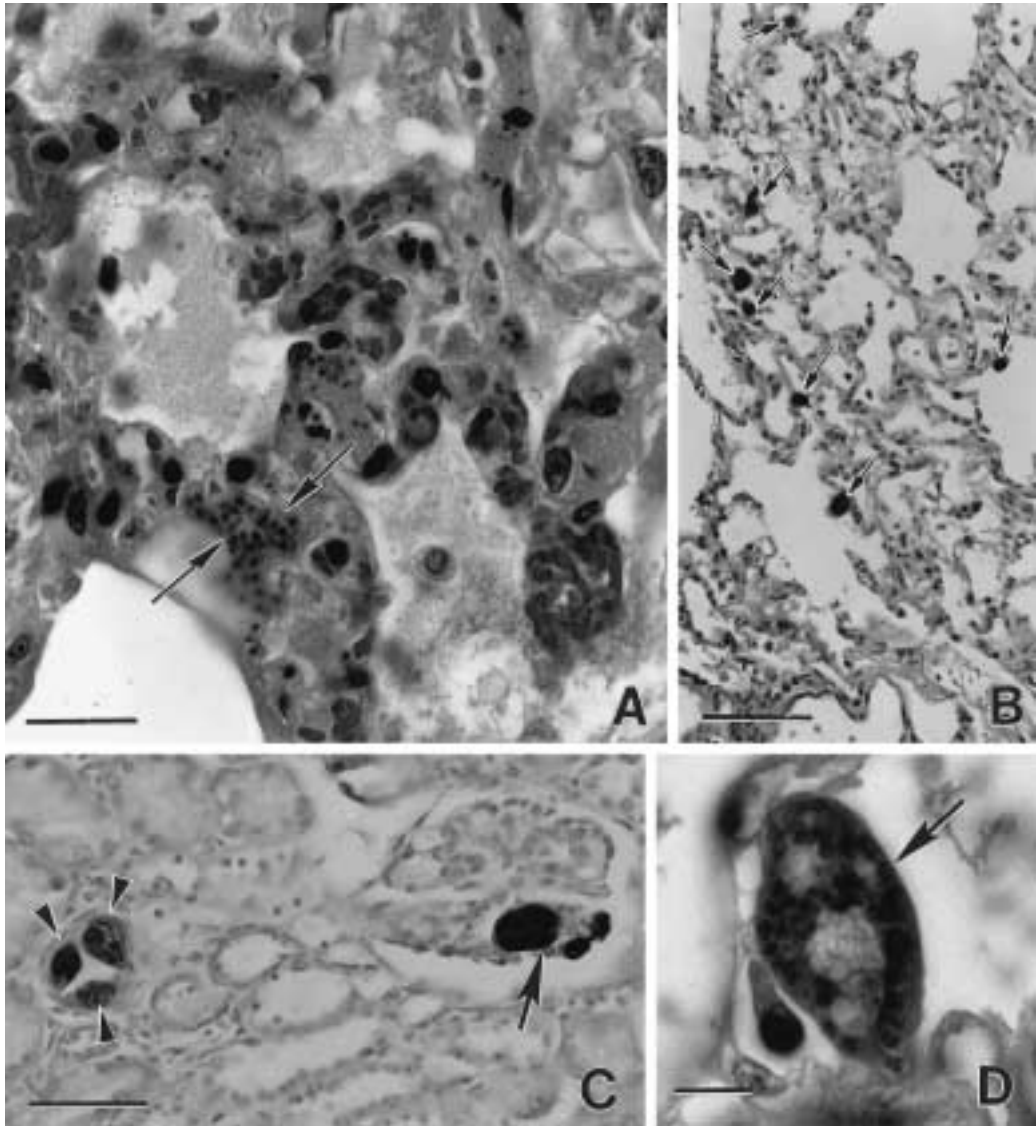


FIGURE 1. Lesions and *Sarcocystis* sp. in tissue sections of a naturally infected white-tailed deer. **A.** Lung with interstitial pneumonia, septal necrosis, infiltrates of mixed leukocytes and merozoites (arrows). H&E stain, Bar = 20  $\mu$ m. **B.** Lung demonstrating several schizonts bulging in to the alveoli. ABC stain with anti-*Sarcocystis cruzi* antibody. Bar = 200  $\mu$ m. **C.** Kidney demonstrating three schizonts in a glomerulus (arrows) and three schizonts in an arteriole (arrowheads). ABC stain with anti-*S. cruzi* antibody. **D.** Lung demonstrating a schizont (arrow) in a capillary. H&E stain. Bar = 20  $\mu$ m.

feces of the definitive host that produces the sporocysts. Following excystation of the sporocyst, sporozoites migrate from the intestine to arterial vessels where they develop into first-generation schizonts in endothelial cells. These schizonts divide by endopolygony (a special type of schizogony) to produce first-generation merozoites.

These merozoites enter the circulation and enter endothelial cells found in a variety of organs and undergo a second-generation of schizogony and produce second-generation merozoites. Second generation merozoites enter the circulation and eventually enter the heart, skeletal muscle, and occasionally neural tissue where they de-

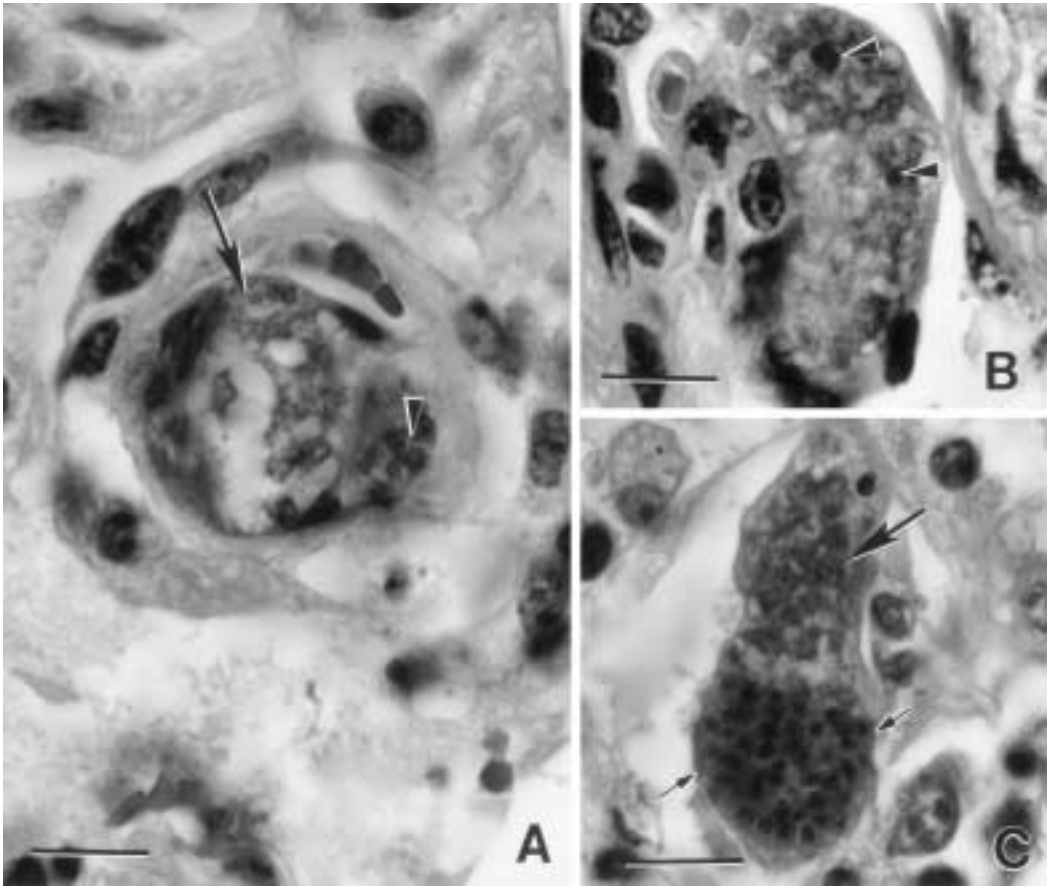


FIGURE 2. Developing and mature schizonts of *Sarcocystis* sp. in the lung of a white-tailed deer. All H&E stain, Bar = 20  $\mu$ m. **A.** Two schizonts in a capillary. Note the lobated nucleus (arrow) of the developing schizont and the merozoites (arrowhead) in the mature schizont. **B.** Immature schizont with lobated nucleus and two prominent nucleoli (arrowheads). **C.** Developing schizont (large arrow) and mature schizont (small arrows).

velop into sarcocysts that contain bradyzoites. Ingestion of sarcocysts by an appropriate definitive host leads to sexual reproduction, oocyst formation, and sporulation of oocysts in the lamina propria of the intestine (Dubey et al., 1989). Fully sporulated sporocysts are excreted in the feces.

*Sarcocystis* spp. infections are usually asymptomatic in the intermediate host, but if large numbers of sporocysts are ingested by pregnant or young animals, clinical disease and death can occur (Dubey et al., 1989). Abortion, wasting, and hemorrhaging of mucosal surfaces are the main signs observed in acute sarcocystosis in the

intermediate host. Lesions are due to developing schizonts in endothelial cells.

*Sarcocystis* spp. infections are highly prevalent in white-tailed deer (Lindsay et al., 1988; Atkinson et al., 1993). White-tailed deer are the intermediate hosts for two named species of the genus *Sarcocystis* (Dubey et al., 1989). *Sarcocystis odocoileocanis* produces microscopic sarcocysts that have a 2–3  $\mu$ m thick sarcocyst wall (Crum et al., 1981). The definitive hosts for *S. odocoileocanis* include dogs (*Canis familiaris*), wolves (*Canis lupus*), coyotes (*Canis latrans*), red foxes (*Vulpes vulpes*) and gray foxes (*Urocyon cinereoar-*

*genteus*) (Dubey et al., 1989). *Sarcocystis odoi* produces sarcocysts that have a 5–10  $\mu\text{m}$  thick sarcocyst wall (Dubey and Lozier, 1983). The definitive host for *S. odoi* are cats (Dubey and Lozier, 1983). The white-tailed deer probably serves as intermediate host for more than these two species based on sarcocyst morphology (Atkinson et al., 1993).

To our knowledge, naturally occurring acute sarcocystosis has not been previously reported in the white-tailed deer or other cervids. To date, no other deer at this park have been affected. Lesions in this case resembled accounts of acute sarcocystosis in adult cattle, originally described in Canada and called Dalmeny disease (Dubey et al., 1989). A species of *Sarcocystis*, *S. hemionilatrantis* is pathogenic for mule deer (*O. hemionus hemionus*). Of 12 mule deer fed  $5 \times 10^4$  to  $1 \times 10^6$  sporocysts, all became anorexic and uncoordinated and 9 died (Dubey and Kistner, 1985). However, natural fatal cases of *S. hemionilatrantis* infections have not been documented in mule deer. Data on the natural epizootiology of *Sarcocystis* spp. in mule deer suggests that *S. hemionilatrantis* infection predisposes mule deer to predation (Dubey and Kistner, 1985).

The deer described in this report was housed in an enclosure with bison (*B. bison*) and this enclosure had housed these species exclusively for the past 10 yr. While this was a naturally occurring case, confinement and hand feeding practices were speculated to have created conditions suitable for development of acute sarcocystosis in this deer. Contamination of feed or water was considered likely as a cause of overwhelming infection. Several carnivores and omnivores including: red and gray foxes (*Vulpes vulpes*, *Urocyon cinereoargenteus*), bobcat (*Felis rufus*), opossum (*Didelphis virginianus*), and bear (*Ursus americanus*) were held in separate enclosures within this wild animal park. Preventive measures to limit cross-contamination of different enclosures with feces carried on boots or other equipment

was not in common practice. None of the captive carnivores or omnivores that could be considered potential definitive hosts were housed upstream of the enclosure in which this deer was held. Wild foxes and wild dogs had been previously observed in the park. Attempts to exclude wild foxes and dogs from the park had failed. A feral cat was resident in the park, but recently has been removed. Since then, additional feral cats have been observed. The mixed grass hay was stored in a barn and raccoons (*Procyon lotor*) were known to inhabit part of the hayloft and fecal contamination of the hay was noted. Additionally, raccoon scats were observed in the enclosure holding the deer and bison. Contamination of forage or water with feces from any of these animals could have provided a source of exposure.

Many wild cervids serve as intermediate hosts for *Sarcocystis* sp., yet different species of *Sarcocystis* are considered host specific (Dubey et al., 1989). We observed merozoites and schizonts, but not mature sarcocysts indicating acute infection. Because sarcocysts were not present in myocardial sections and skeletal muscle was not examined, we were not able to definitively identify the *Sarcocystis* sp. It is quite possible that either of the previously named species of *Sarcocystis* documented in white-tailed deer or a previously unnamed species was present in this case.

We acknowledge the histotechnical assistance of J. Songer, L. Vest, and M. Berger.

#### LITERATURE CITED

- ATKINSON, C. T., S. D. WRIGHT, S. R. TELFORD, JR., G. S. MCLAUGHLIN, D. J. FORRESTER, R. E. ROELKE, AND J. W. MCCOWN. 1993. Morphology, prevalence, and distribution of *Sarcocystis* spp. in white-tailed deer (*Odocoileus virginianus*) from Florida. *Journal of Wildlife Diseases* 29: 73–78.
- CRUM, J. M., R. FAYER, AND A. K. PRESTWOOD. 1981. *Sarcocystis* spp. in white-tailed deer I. Definitive and intermediate host spectrum with a description of *Sarcocystis odocoileocanis* n. sp. *Journal of Wildlife Diseases* 17: 567–579.
- DUBEY, J. P., AND S. M. LOZIER. 1983. *Sarcocystis*

- infections in white-tailed deer (*Odocoileus virginianus*) in Montana: Intensity and description of *Sarcocystis odoi* n. sp. *American Journal of Veterinary Research* 44: 1738–1743.
- , AND T. P. KISTNER. 1985. Epizootiology of *Sarcocystis* infections in mule deer fawns in Oregon. *Journal of the American Veterinary Medical Association* 187: 1181–1186.
- , C. A. SPEER, AND R. FAYER. 1989. *Sarcocystis* of man and animals. CRC Press, Boca Raton, Florida, 215 pp.
- , S. W. DAVIS, C. A. SPEER, D. D. BOWMAN, A. DE LAHUNTA, D. E. GRANSTROM, M. J. TOPPER, A. N. HAMIR, AND M. M. SUTER. 1991. *Sarcocystis neurona* n. sp. (Protozoa: Apicomplexa), the etiologic agent of equine protozoal myeloencephalitis. *The Journal of Parasitology* 77: 212–218.
- LINDSAY, D. S., AND J. P. DUBEY. 1989. Immunohistochemical diagnosis of *Neospora caninum* in tissue sections. *American Journal of Veterinary Research* 50: 1981–1983.
- LINDSAY, D. S., B. L. BLAGBURN, W. H. MASON, AND J. C. FRANSEN. 1988. Prevalence of *Sarcocystis odocoileocanis* from white-tailed deer in Alabama and its attempted transmission to goats. *Journal of Wildlife Diseases* 24: 154–156.

*Received for Publication 12 June 1999.*