

Ultrastructure of Frenkelia sp. from a Norwegian Lemming in Finland

Authors: Laakkonen, Juha, and Henttonen, Heikki

Source: Journal of Wildlife Diseases, 36(2) : 362-366

Published By: Wildlife Disease Association

URL: <https://doi.org/10.7589/0090-3558-36.2.362>

BioOne Complete (complete.BioOne.org) is a full-text database of 200 subscribed and open-access titles in the biological, ecological, and environmental sciences published by nonprofit societies, associations, museums, institutions, and presses.

Your use of this PDF, the BioOne Complete website, and all posted and associated content indicates your acceptance of BioOne's Terms of Use, available at www.bioone.org/terms-of-use.

Usage of BioOne Complete content is strictly limited to personal, educational, and non - commercial use. Commercial inquiries or rights and permissions requests should be directed to the individual publisher as copyright holder.

BioOne sees sustainable scholarly publishing as an inherently collaborative enterprise connecting authors, nonprofit publishers, academic institutions, research libraries, and research funders in the common goal of maximizing access to critical research.

Ultrastructure of *Frenkelia* sp. from a Norwegian Lemming in Finland

Juha Laakkonen^{1,3} and Heikki Henttonen² ¹ Department of Biology, University of California, San Diego, 9500 Gilman Drive, La Jolla, California 92093-0116, USA and Section of Anatomy, Faculty of Veterinary Medicine, PO Box 57, FIN-00014 Helsinki University, Finland; ² Finnish Forest Research Institute, PO Box 18, FIN-01301, Vantaa, Finland; ³ Corresponding author (e-mail: Juha@biomail.ucsd.edu).

ABSTRACT: An apparently healthy Norwegian lemming (*Lemmus lemmus*) caught in northern Finland was observed to have a whitish body 0.5 to 1.0 mm in diameter in the external layer of the cerebral cortex. By light microscopy a highly lobulated cyst of *Frenkelia* sp. was observed. By transmission electron microscopy the cyst wall was seen consisting of a parasitophorous vacuolar membrane, an underlying electron-dense layer and a granular layer. The membrane was only slightly convoluted. The protrusions of the cyst wall appeared round but were often not distinctive. A very thin septum divided the interior of the cyst into compartments packed with bradyzoites and maturing zoites. The bradyzoites were elongate measuring $5\text{--}8 \times 1.5\text{--}2 \mu\text{m}$. This is the first electron microscopical study of *Frenkelia* sp. from *L. lemmus*.

Key words: *Frenkelia* spp., heteroxenous coccidia, *Lemmus lemmus*, ultrastructure.

Frenkelia microti and *Frenkelia glareoli* (Biocca, 1968) are heteroxenous coccidia (Apicomplexa: Coccidia: Sarcocystidae) that form tissue cysts in the brain of small rodents acting as intermediate hosts while oocysts are formed in the intestine of definitive hosts, hawks or buzzards of the genus *Buteo* (Levine and Ivens, 1990). *Frenkelia glareoli* (Erhardova, 1955; synonym *Frenkelia clethrionomyobuteonis*, Rommel and Krampitz, 1975) occurs in Europe and uses buzzards (*Buteo buteo*) and rough-legged hawks (*Buteo lagopus*) as definitive hosts, and bank voles (*Clethrionomys glareol*) as intermediate hosts (Rommel and Krampitz, 1975). Besides the strict intermediate host specificity, *F. glareoli* is characterized by microscopic cysts of non-lobate compartments. *Frenkelia microti* (Findlay and Middleton, 1934) occurs in many areas in the northern hemisphere, and has a wide intermediate host range of rodents (see Upton and McKown, 1992).

It uses several buzzards of the genus *Buteo* as definitive hosts (see Geisel et al., 1978), and is characterized by macroscopic lobulated cysts.

Enemar (1965) found one M-organism (*Frenkelia* sp.) in the brain of a Norwegian lemming (*Lemmus lemmus*) collected in Swedish Lapland. Besides this detailed histological description of *Frenkelia* sp., there are no other reports of *Frenkelia* sp. from *L. lemmus*. As part of our ongoing study to monitor occurrence and distribution of *L. lemmus* in Finnish Lapland prior to expected mass movements from northern mountain regions into the taiga forests occurring in periodicity of 30 to 35 yr (Henttonen and Kaikusalo, 1993), we collected data on the parasites of *L. lemmus*. We describe here the ultrastructure of a cyst of *Frenkelia* sp. in the brain of a *L. lemmus* from Finnish Lapland.

The over-wintered male *L. lemmus* examined in this study was found dead in a large pitfall in the subarctic birch forest zone in Kilpisjärvi (69°03'N, 20°49'E) in northern Finland in September 1998. None of the other 55 lemmings examined were infected with *Frenkelia* sp.

At necropsy, all major organs were examined macroscopically for parasites and anomalies. Tissue samples of brain, heart, lungs, kidney, spleen and liver were fixed in 10% buffered formalin. Standard histological sections (5 μm) were then prepared and stained by haematoxylin and eosin (H & E). Sections were studied by microscope at $\times 200$ and $\times 1,000$. For electron microscopy, 1 mm³ samples of formalin fixed brain tissue were re-fixed for 2 hr in 2.5% glutaraldehyde in phosphate buffer with OsO₄ postfixation. After

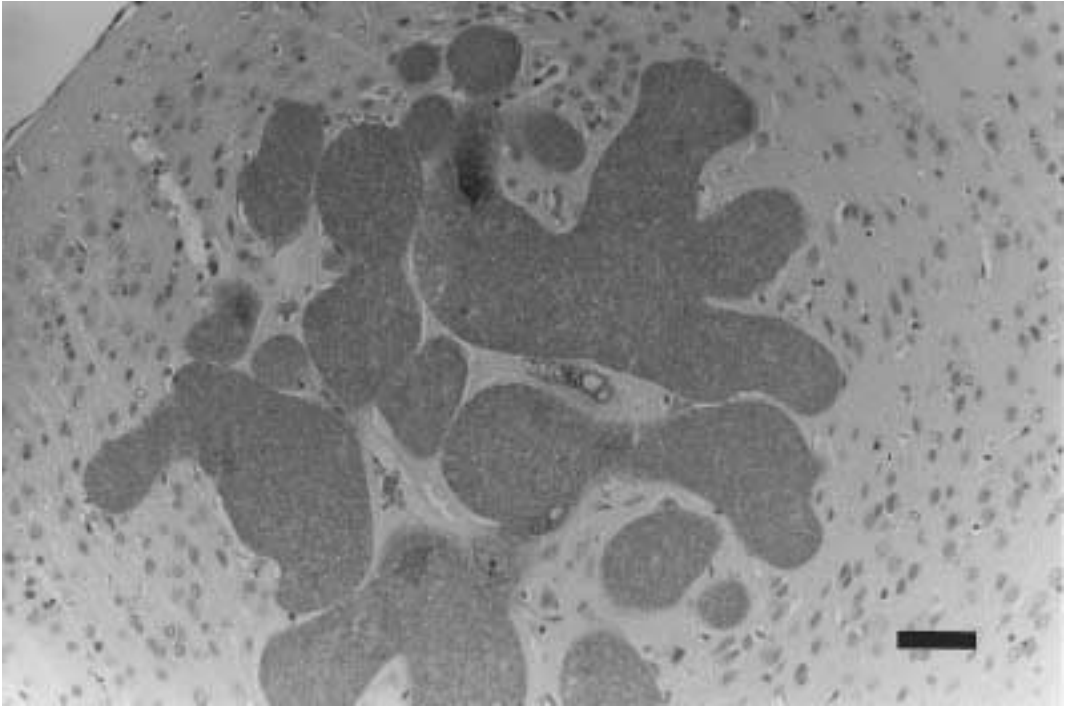


FIGURE 1. Multilobulated cyst of *Frenkelia* sp. in the brain of *L. lemmus*. Note the absence of inflammation. H & E stain. Scale bar = 50 μm.

dehydration in acetone, the samples were embedded in LX 112 Epon plastic (Ladd Research Industries, Inc. Burlington, Vermont, USA) and polymerized. Ultrathin sections were stained with 3% uranyl acetate, and with 3% lead citrate at room temperature. The sections were examined with a JEOL JEM S electron microscope (JEOL LTD, Tokyo, Japan). A voucher tissue section of *Frenkelia* sp. from *L. lemmus* was deposited in the U.S. National Parasite Collection, Beltsville, Maryland (USNPC No. 88803). The terminology used to describe the ultrastructure of the cysts is according to Dubey et al. (1989).

The animal appeared to be in good condition. Macroscopic examination revealed a whitish body 0.5 to 1.0 mm in diameter in the external layer of cerebral cortex. Examination of H & E stained sections revealed a lobulated cyst form of *Frenkelia* sp. (Fig. 1) measuring 500 μm in diameter in the cortex of the cerebrum at the site where the whitish body was observed mac-

roscopically. The macroscopic cysts were highly lobate, but they elicited no inflammation in the cerebral hemisphere surrounding the parasitic cyst (Fig. 1). Ultrastructural examination demonstrated minute undulations on the entire cyst surface (Figs. 2 and 3), and occasionally a deeper fold was observed (Fig. 2). The protrusions of the cyst wall appeared round but they often were not distinctive. The cyst wall (Fig. 2) consisted of a parasitophorous vacuolar membrane (average thickness 0.02 μm), an underlying electron-dense layer (0.16–0.24 μm) and a granular layer (0.6 μm). The electron-dense layer of irregular thickness extended in places as a very thin septa into the interior of the cyst dividing the interior into compartments packed with bradyzoites and maturing zoites (Fig. 3). The bradyzoites were elongate with one end rounded and the other pointed, and measuring $5\text{--}8 \times 1.5\text{--}2$ μm. They appeared to be surrounded by a double membrane (Fig. 2). The conical-shaped

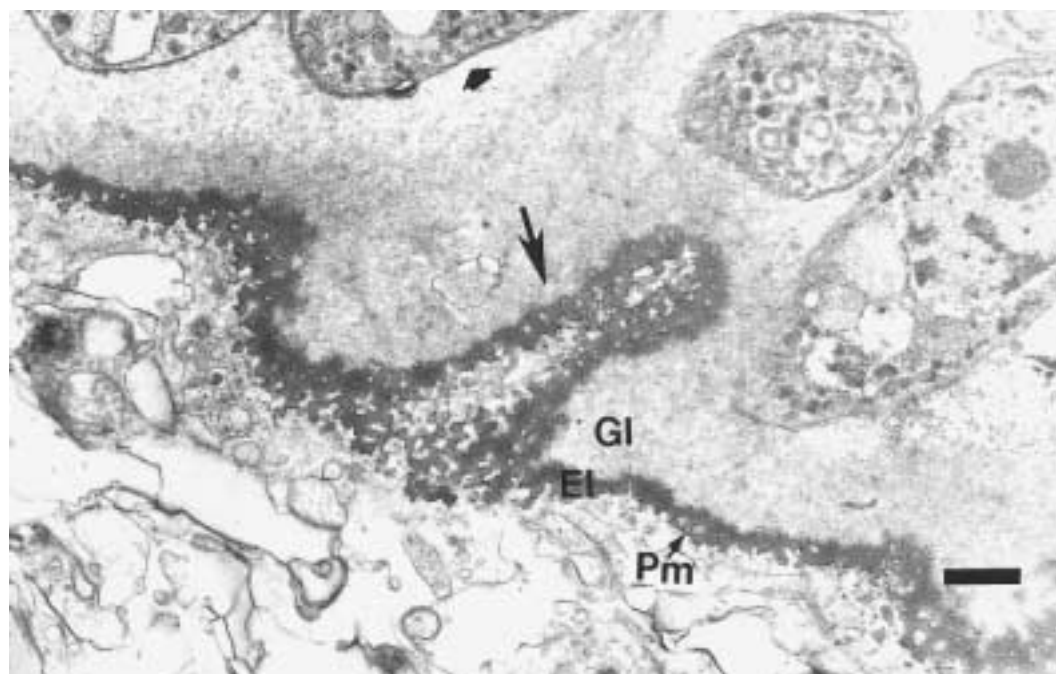


FIGURE 2. Transmission electron micrograph of *Frenkelia* sp. in the brain of *L. lemmus* showing the cyst wall consisting of a parasitophorous vacuolar membrane (Pm), an underlying electron-dense layer (EI) and a granular layer (GI). At certain points, the Pm invaginates into the granular layer (arrow). The double membrane (arrowhead) of a bradyzoite is also visible. Scale bar = 0.5 μ m.

conoid typical for Apicomplexa was not visible in any of the bradyzoites (see below) but membrane-bound, elongate micronemes were visible (Fig. 3). The immature, rounded zoites with an electron-lucent cytoplasmic matrix were principally observed along the periphery of the cyst. Of the interior organelles typical for maturing zoites (Dubey et al., 1989) endoplasmic reticulum, several mitochondria and vacuoles were visible in most maturing zoites (Fig. 3). In all sections examined the number of bradyzoites was low compared to the number of maturing zoites (Fig. 3).

The macroscopic cyst seen in H & E stained sections in this study was similar to that described by Enemar (1965) previously from *L. lemmus*, and they also resembled those found in other rodents (see Upton and McKown, 1992; Fujita et al., 1988). In this study, the septa of the cyst were not so clearly visible as in the cyst described by Enemar (1965). This was most likely due to the different stains used

for preparation of the histological samples. The appearance of the cyst is also likely to depend on the plane in which the cyst was cut by the microtome as well as on the developmental stage in which it was found (Kennedy and Frelie, 1986). The septa were, however, clearly visible in electron micrographs of the cyst in this study (Fig. 3). The structures of the interior organelles of bradyzoites were similar to those seen in other studies of *Frenkelia* spp. (Tadros et al., 1972).

In this study, the ultrastructure of the cyst wall was more similar to the cyst wall of *F. microti* than that of *F. glareoli* (Tadros et al., 1972). In general, the protrusions of the cyst wall did not appear to be as distinctive (Fig. 2) as those seen in other studies of *Frenkelia* (Kennedy and Frelie, 1986), and of *Sarcocystis* spp. (Espinosa et al., 1988). Except for the affinity to different tissues, *Frenkelia* and *Sarcocystis* are very similar in structure, and it has been

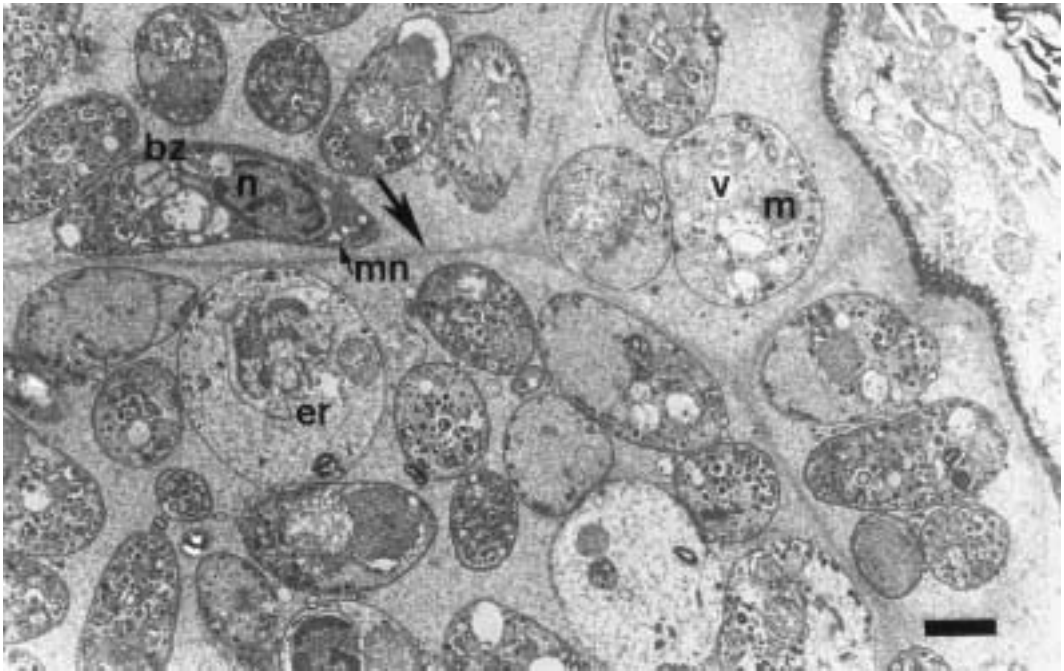


FIGURE 3. Transmission electron micrograph of *Frenkelia* sp. in the brain of *L. lemmus* demonstrating the very thin septa (arrow) dividing the interior of the cyst into compartments. An elongate bradyzoite (bz) and round immature zoites are seen inside the compartments. Abbreviations are: endoplasmic reticulum (er), microneme (mn), mitochondria (m), nuclei (n), and vacuoles (v). Scale bar = 1.5 μ m.

proposed to synonymize the former genus with the latter (Votýpka et al., 1998).

The name *F. microti* has often been used to describe all lobulated *Frenkelia* spp. from various host species including *L. lemmus* (see Upton and McKown, 1992). *Frenkelia* sp. from *L. lemmus*, however, has not been named to the species level (Levine and Ivens, 1990). Results of this study showed that the ultrastructure of the *Frenkelia* sp. from *L. lemmus* is similar to that of *F. microti* from other rodents. Molecular studies are warranted to investigate whether the lobulated *Frenkelia* sp. from different rodents represent one (*F. microti*) or several species.

The definitive host of this protozoan parasite is unknown but the definitive hosts for *Frenkelia* spp. are raptors (Levine and Ivens, 1990). Upton and McKown (1992) suggested that because the *B. lagopus* is circumpolar, it represents an ideal candidate as a definitive host for *F. microti*. *Buteo lagopus* is one of the main

predators of rodents also at Kilpisjärvi during the summer months.

Based on previous reports on the effect of *Frenkelia* (Voříšek et al., 1998) and other brain invading parasites (Quinn et al., 1987; Berdoy et al., 1995), it can be predicted that the cysts in the brain may interfere with the normal function of the central nervous system increasing the exploratory behavior of the host. As a consequence, lemmings are likely to be more susceptible to predation. The possible contribution of *Frenkelia* sp. on the altered behavior of *L. lemmus* during its mass movements remains to be studied.

We are grateful for J. Niemimaa for helping in the field, and T. Pankasalo and P. Niemelä for valuable technical assistance. This research was funded by The Research Council for Natural Sciences of the Academy of Finland and the Oskar Öflund Stiftelse Foundation (JL).

LITERATURE CITED

- BERDOY, M., J. P. WEBSTER, AND D. W. MACDONALD. 1995. Parasite-altered behavior: Is the effect of *Toxoplasma gondii* on *Rattus norvegicus* specific? *Parasitology* 111: 403–409.
- BIOCCA, E. 1968. Class Toxoplasmea critical review and proposal of the new name *Frenkelia* gen. N. for M-organism. *Parasitologia* 10: 89–98.
- DUBEY, J. P., C. A. SPEER, AND R. FAYER. 1989. Sarcocystis of animals and man. CRC Press, Inc., Boca Raton, Florida, 205 pp.
- ENEMAR, A. 1965. M-organisms in the brain of the Norway lemming, *Lemmus lemmus*. *Arkiv för Zoologi Serie 2*, 18: 9–16.
- ERHARDOVA, B. 1955. Nachweis toxoplasmaähnlicher parasiten bei der Rötelmaus *Clethrionomys glareolus*. *Folia Biologica* 1: 381–382.
- ESPINOSA, R. H., M. C. STERNER, J. A. BLIXT, AND R. J. CAWTHORN. 1988. Description of a species of *Sarcocystis* (Apicomplexa: Sarcocystidae), a parasite of the northern saw-whet owl, *Aegolius acadicus*, and experimental transmission to deer mice, *Peromyscus maniculatus*. *Canadian Journal of Zoology* 66: 2118–2121.
- FINDLEY, G. M., AND A. D. MIDDLETON. 1934. Epidemic disease among voles (*Microtus*) with special reference to *Toxoplasma*. *Journal of Animal Ecology* 3: 150–160.
- FUJITA, O., O. YUZABURO, AND M. OHBAYASHI. 1988. *Frenkelia* sp. from the red-backed vole, *Clethrionomys rufocanus bedfordiae*, in Hokkaido, Japan. *Japanese Journal of Veterinary Research* 36: 69–71.
- GEISEL, O., E. KAISER, H. E. KRAMPITZ, AND M. ROMMEL. 1978. Beiträge zum lebenszyklus der Frenkelien. IV. Pathomorphologische befunde an den organen experimentell infizierter Rötelmäuse. *Veterinary Pathology* 15: 621–630.
- HENTTONEN, H., AND A. KAIKUSALO. 1993. Lemming movements. In *The biology of lemmings*, N. C. Stenseth and R. A. Ims (eds.). The Linnean Society of London, Academic Press, London, UK, pp. 157–186.
- KENNEDY, M. J., AND P. F. FRELIER. 1986. *Frenkelia* sp. from the brain of a porcupine (*Erethizon dorsatum*) from Alberta, Canada. *Journal of Wildlife Diseases* 22: 112–114.
- LEVINE, N. D., AND V. IVENS. 1990. The coccidian parasites of rodents. CRC Press, Inc., Boca Raton, Florida, 228 pp.
- QUINN, S. C., R. J. BROOKS, AND R. CAWTHORN. 1987. Effects of the protozoan parasite *Sarcocystis rauschorum* on open-field behavior of its intermediate vertebrate host, *Dicrostonyx richardsoni*. *The Journal of Parasitology* 73: 265–271.
- ROMMEL, V. M., AND H. E. KRAMPITZ. 1975. Beiträge zum Lebenszyklus der Frekelien. I. Die identität von *Isospora buteonis* aus dem Mäusebussard mit einer Frenkelienart (*F. clethrionomyobuteonis* spec. n.) aus der Rötelmaus. *Berlin Münchener Tierärzichle Wochenscreitung* 88: 338–340.
- TADROS, W. A., R. G. BIRD, AND D. S. ELLIS. 1972. The fine structure of cysts of *Frenkelia* (The M-organism). *Folia Parasitologica* 19: 203–209.
- UPTON, S. J., AND R. D. MCKOWN. 1992. The red-tailed hawk, *Buteo jamaicensis*, a native definitive host of *Frenkelia microti* (Apicomplexa) in North America. *Journal of Wildlife Diseases* 28: 85–90.
- VOŘÍŠEK, P., J. VOTÝPKA, K. ZVÁRA, AND M. SVOBODA. 1998. Heteroxenous coccidia increase the predation risk of parasitized rodents. *Parasitology* 117: 521–524.
- VOTÝPKA, J., V. HYPŠA, M. JIRKU, J. FLEGER, J. VÁVRA, AND J. LUKES. 1998. Molecular phylogenetic relatedness of *Frenkelia* spp. (Protozoa, Apicomplexa) to *Sarcocystis falcatula* Stiles 1893: Is the genus *Sarcocystis* paraphyletic? *Journal of Eukaryotic Microbiology* 45: 137–141.

Received for publication 7 July 1999.