

EXPERIMENTAL TRANSMISSION OF CUTANEOUS CHYTRIDIOMYCOSIS IN DENDROBATID FROGS

Authors: Nichols, Donald K., Lamirande, Elaine W., Pessier, Allan P., and Longcore, Joyce E.

Source: Journal of Wildlife Diseases, 37(1) : 1-11

Published By: Wildlife Disease Association

URL: <https://doi.org/10.7589/0090-3558-37.1.1>

BioOne Complete (complete.BioOne.org) is a full-text database of 200 subscribed and open-access titles in the biological, ecological, and environmental sciences published by nonprofit societies, associations, museums, institutions, and presses.

Your use of this PDF, the BioOne Complete website, and all posted and associated content indicates your acceptance of BioOne's Terms of Use, available at www.bioone.org/terms-of-use.

Usage of BioOne Complete content is strictly limited to personal, educational, and non - commercial use. Commercial inquiries or rights and permissions requests should be directed to the individual publisher as copyright holder.

BioOne sees sustainable scholarly publishing as an inherently collaborative enterprise connecting authors, nonprofit publishers, academic institutions, research libraries, and research funders in the common goal of maximizing access to critical research.

EXPERIMENTAL TRANSMISSION OF CUTANEOUS CHYTRIDIOMYCOSIS IN DENDROBATID FROGS

Donald K. Nichols,^{1,4} Elaine W. Lamirande,¹ Allan P. Pessier,^{1,3} and Joyce E. Longcore²

¹ Department of Pathology, National Zoological Park, Smithsonian Institution, 3000 Connecticut Avenue NW, Washington, DC 20008, USA

² Department of Biological Sciences, University of Maine, Orono, Maine 04469, USA

³ Current address: Department of Pathology, Zoological Society of San Diego, P.O. Box 120551, San Diego, California 92112, USA

⁴ Corresponding author (e-mail: dnichols@nzp.si.edu)

ABSTRACT: In a series of three experiments during March–October, 1998, two species of captive-bred poison dart frogs (*Dendrobates tinctorius* and *D. auratus*) were exposed to *Batrachochytrium dendrobatidis*, a recently-described chytridiomycete fungus (chytrid) that was originally isolated from a blue poison dart frog (*D. azureus*). All frogs exposed to the chytrids developed a fatal skin disease, whereas none of the control frogs developed skin lesions. The most consistent clinical sign in chytrid-exposed frogs was excessive shedding of skin. Gross lesions were subtle, usually affected the legs and ventrum, and consisted of mild skin thickening and discoloration. Microscopic examination of shed skin pieces and/or skin imprints demonstrated the presence of chytrids and was used for ante mortem and post mortem confirmation of chytrid infection. Histologically, there was epidermal hyperkeratosis, hyperplasia, and hypertrophy associated with low to moderate numbers of chytrids in the keratinized layers. These experiments demonstrated that *Batrachochytrium dendrobatidis* can be a fatal pathogen in poison dart frogs. The experimentally-induced disease in these frogs resembled cases of cutaneous chytridiomycosis that have recently been described in several other species of captive and wild amphibians.

Key words: *Batrachochytrium dendrobatidis*, chytrid, cutaneous chytridiomycosis, *Dendrobates auratus*, *Dendrobates tinctorius*, experimental infection, fungus, poison dart frog.

INTRODUCTION

Most species in the fungal class Chytridiomycetes (chytrids) live on decaying organic material (Barr, 1990). Although some species of chytrids were known to parasitize fungi, plants, and invertebrate animals, none had been reported to be a pathogen of vertebrates until recently. Berger et al. (1998) and Pessier et al. (1999) described a novel skin disease in several species of anuran amphibians, associated with the presence of epidermal infection by chytrids. Deaths of captive frogs (Pessier et al., 1999) and the decline of many wild populations of frogs and toads in Australia and Panama (Berger et al., 1998) have been attributed to this disease. Although chytrids were clearly present in the skin lesions of the dead animals, it had not been conclusively demonstrated that infection by these organisms was the cause of the lesions.

This paper describes the experimental transmission of fatal cutaneous chytridiomycosis in two species of dendrobatid

frogs using *Batrachochytrium dendrobatidis*, a recently described chytrid species (Longcore et al., 1999). The study consisted of a series of three experiments performed during March–October 1998. The purposes of Experiment 1 were to develop techniques for infecting frogs with chytrids and to monitor the progression of any disease that resulted. The purpose for Experiment 2 was to determine if the results of Experiment 1 were repeatable, using frogs from a different species. Experiment 3 was conducted to determine if frogs could be infected by a different method of exposure to chytrids and, if so, what effects this had on the progression of the disease.

MATERIALS AND METHODS

Experiment 1

In March 1998, eight captive-bred juvenile (2–3 mo post metamorphosis; body weight range 0.67–0.94 g) blue-and-yellow poison dart frogs (*Dendrobates tinctorius*) were obtained from a privately owned collection of poison dart frogs (The Boa Barn, Long Green, Maryland, USA) that had no history of chytridiomy-

cosis or any other skin disease. These frogs were housed two or three per cage in 5.7 l plastic storage boxes (Sterilite Corporation, Townsend, Massachusetts, USA). To allow for adequate ventilation, a 26 × 13 cm rectangular section was removed from the middle of the lid of each container and silkscreen fabric was taped over these areas to prevent the frogs from escaping. A 15 × 25 cm piece of polypropylene grass-like carpet (Bretlin Inc., Calhoun, Georgia, USA) was placed in the bottom of each container as substrate and two or three leaves from a plastic aquarium plant were added to provide hiding places. The containers were inclined by setting one end on 2.5 cm plastic blocks. Approximately 100 ml of tap water that had been passed through a reverse osmosis water filter (RO water) was added to each container, resulting in the formation of a pool of water at the lower end. The containers were placed inside incubators (Thermocare Model W1 Intensive Care Warmers, Thermocare Inc., Incline Village, Nevada, USA) that were timer-controlled so that the containers warmed to 25 C for 8 hr during the day and gradually cooled to ambient room temperature (20–22 C) at night. Containers were cleaned every 2–3 days by thoroughly rinsing the container, carpet substrate, and plastic leaves with copious amounts of RO water. Frogs were fed *ad libitum* fruitflies (*Drosophila melanogaster* vestigial wing) (Carolina Biological Supply Company, Burlington, North Carolina, USA) that were raised on a commercial fruitfly food (Formula 4–24 Instant *Drosophila* Medium, Carolina Biological Supply Company). The flies were coated with a fine dust of a vitamin-mineral mixture (Miner-All O, Sticky Tongue Farms, Menifee, California, USA) just before being added to the frog cages.

The frogs were acclimated to the above conditions for 3 wk before beginning the experiment. Three frogs died between days 17 and 21 of the acclimation period. A complete necropsy, including histologic examination of skin and all major organs, was performed on each dead frog. Necropsy revealed that the frogs had decreased body fat stores and numerous oxyurid and strongyle nematodes within the intestinal tract; the cause of death in each case was attributed to nematode parasitism and poor body condition. Each of the remaining frogs was weighed and treated once orally with 0.1 mg fenbendazole (Panacur, Hoechst-Roussel, Somerville, New Jersey, USA); this dose was approximately 100 mg/kg (actual dose: 106–149 mg/kg). Four days later, each frog was orally treated with 0.25 µg of ivermectin (Ivomec, Merck and Company, Rathway, New Jersey, USA; actual dose: 266–373 µg/kg) and moved

to completely new cages set up as previously described. The frogs were divided into two groups; the control group consisted of three frogs (B1, B2, and B3) and the experimental group had two frogs (B4 and B5).

The chytrid species used for this experiment, *Batrachochytrium dendrobatidis*, was isolated from a blue poison dart frog (*Dendrobates azureus*) that died at the National Zoological Park in September 1997 (Longcore et al., 1999). Cultures of this organism were grown on 2% tryptone agar (Difco Laboratories, Detroit, Michigan, USA) and in 1% tryptone broth (Difco Laboratories). For this experiment, these cultures were kept at the same fluctuating temperatures (20–25 C) present in the frogs' incubators. For each experimental exposure, a 1 × 2 cm block of agar with chytrid colonies containing active zoospores (viewed with an inverted microscope) was removed with a sterile scalpel and rinsed 10 times with 0.5 ml of sterile 1% tryptone broth. The agar rinse was transferred to a sterile vial and mixed with an equal volume of tryptone broth culture containing good chytrid colony growth (based on turbidity of broth for cultures between 9- and 19-days-old). Using a pipette, a 200 µl aliquot of this mixture was dripped onto the back and hind-legs of each frog in the exposure group. Each frog in the control group was similarly exposed to 200 µl of a solution prepared in the same manner from tryptone agar plates and tryptone broth that did not contain chytrids. Frogs were exposed once a day for 30 days or until they died.

Frogs were observed several times a day throughout the experiment for clinical signs of disease. Pieces of shed skin (keratinized epidermis) that were found in the cages were removed, placed on glass slides to air dry, and then stained (DipQuick, Jorgensen Laboratories Inc., Loveland, Colorado, USA) for microscopic examination. Frogs that were found dead were removed from the cages for post mortem examination. One frog was found moribund and was euthanized by immersion in a solution of RO water containing a high concentration of tricaine methane sulfonate (TMS, Crescent Research Chemicals, Phoenix, Arizona, USA). At the end of the experiment (5 days after the last frog in the experimental group died), the surviving control frogs were euthanized in the same manner.

A necropsy was performed on each frog and the coelomic cavity organs were removed for fixation in 10% buffered formalin. One hindleg from the first frog that died in the experimental group was removed placed on ice packs, and shipped to one of the authors (JEL) for chytrid isolation and identification as previously de-

scribed (Longcore et al., 1999). The remainder of each carcass was fixed intact in 10% formalin and then decalcified in 5% trichloroacetic acid (Fisher Scientific, Fair Lawn, New Jersey, USA). Representative samples of all organs were sectioned and processed routinely for histologic examination.

Experiment 2

In August 1998, eight juvenile (2–3 mo post metamorphosis; 0.45–1.25 g) green-and-black poison dart frogs (*Dendrobates auratus*) were obtained from the same private collection as in Experiment 1. Frogs were initially housed in two groups of four under conditions similar to those described previously; however, water provided to the frogs and used to clean cages was a mixture of approximately 80% RO water and 20% tap water that had been passed through a charcoal filter. The frogs were fed *ad libitum* fruitflies (*Drosophila melanogaster* and/or *D. hydei*, Carolina Biological Supply Company) that were fed the same diet and dusted with the same vitamin-mineral powder as before. Two days after their arrival, frogs were weighed and prophylactically dewormed with oral ivermectin (dose: 0.73–1.00 mg/kg). Six days later, one frog was found dead in its cage and a complete necropsy was performed on the carcass, including histologic examination of all major organs. Necropsy results revealed that the cause of death was inanition, which was attributed to overcrowding and cagemate aggression. The frog groups were divided and frogs were then housed singly or in pairs. Two additional juvenile *D. auratus* were purchased from the same source, prophylactically treated with ivermectin (1.0 mg per frog topically), and housed together throughout the experiment.

This experiment began six days after the arrival of the last two frogs. Three frogs (G1, G2, and G3) served as the control group. The experimental group consisted of six frogs (G4, G5, G6, G7, G8, and G9). *Batrachochytrium dendrobatidis* was grown on tryptone agar and in tryptone broth as before, except that cultures were maintained at room temperature (20–22°C). Mixtures of agar and broth cultures were prepared in the same manner described in Experiment 1 and each frog in the experimental group was exposed by dripping 200 µl of the chytrid culture mixture onto its back and hindlegs using a pipette. Frogs in the control group were exposed to chytrid-free broth as previously described. The frogs were exposed once per day, Monday through Friday, for 4 wk or until death; in wk 3, exposures occurred Tuesday through Friday.

Frogs were observed daily for clinical signs

of disease. Pieces of shed skin that were found in the cages were removed, placed on glass slides to air dry, and stained as before for microscopic examination. On day 23 after the exposures began, skin imprints of each surviving frog were made by gently pressing each frog between two glass slides; these slides were air-dried, stained, and examined microscopically. Skin imprints also were made from each frog that died before further post mortem examination.

A necropsy was performed on each dead frog and tissue samples were collected and processed for histologic examination as described for Experiment 1. Before formalin fixation, one hindleg each was removed from the first and last frogs to die in the experimental group, and these were used for chytrid isolation and identification using procedures described by Longcore et al. (1999).

Three days after the last frog in the experimental group died, skin imprints were again made from each of the surviving frogs in the control group. In addition, scrapings of each frog's skin were made by gently rubbing the dull side of a sterile scalpel blade across the dorsal and ventral surfaces of the animal's trunk and hindlegs. The material on the scalpel blades was smeared across glass slides and air-dried. Slides of the imprints and scrapings were stained and examined microscopically as described above. The frogs in the control group were observed for an additional seven days and skin imprints were again made and examined microscopically. The experiment was then considered to be over and the animals in the control group were used in Experiment 3.

Experiment 3

The three frogs (G1, G2, and G3) that served as negative controls in Experiment 2 were used in this experiment. Each frog was individually housed under the same conditions described in Experiment 2.

Cultures of *Batrachochytrium dendrobatidis* were maintained as in Experiment 2. In this experiment, the pool of water in each frog's cage was contaminated with chytrids; the frogs were not directly exposed nor were they placed in the water after it was contaminated. For the contamination of each cage, a 1 × 2 cm section of tryptone agar with chytrid colonies containing active zoospores was removed with a sterile scalpel and rinsed 10 times with 0.5 ml of 1% tryptone broth. The agar rinse was mixed with 0.5 ml of tryptone broth culture containing good chytrid colony growth (based on broth turbidity). This mixture was added to the pool of water in the frog cage. The cage of frog G1

was contaminated once and 48 hr later, the cage was cleaned. The cage of frog G3 was contaminated on three consecutive days; the cage was cleaned 24 hr after the second contamination, then it was contaminated again, and it was cleaned 48 hr after the third contamination. The cage of frog G2 was contaminated on five consecutive days; this cage was cleaned 24 hr after the second contamination, then contaminated again, cleaned 24 hr after the fourth contamination, then contaminated a final time and cleaned 72 hr later.

Frogs were observed daily for signs of disease. Pieces of shed skin found in the cages were removed, stained, and examined microscopically as described before. Skin imprints from each surviving frog were made on days 9 and 15 after the experiment started. In addition, skin imprints were made from each carcass before necropsy. This experiment ended when the last frog died. A complete necropsy was performed on each frog and tissue samples were collected and processed for histologic examination as described previously.

Statistical analyses

A Chi-square test (DeGroot, 1975) was used to compare the prevalence of skin disease in the chytrid-exposed frogs to that in the control frogs for Experiment 1 and for Experiment 2. Chi-square tests also were used to compare the prevalence of mortality during the experiment in chytrid-exposed frogs to that in the control frogs for Experiment 1 and for Experiment 2. Finally, the results of the three experiments were combined so that skin disease prevalence and mortality of all chytrid-exposed frogs could be compared to those in all control frogs, using Chi-square tests. The tests were performed utilizing the Microsoft Excel statistical program (Microsoft Corporation, Redmond, Washington, USA) and results were considered significant for $P < 0.05$.

RESULTS

General

Findings in all three experiments were similar. Therefore, the experimental results will be presented together and any remarkable differences among the experiments will be identified and discussed separately.

Clinical signs

Anorexia was the earliest clinical sign noted in frogs that had been exposed to chytrids. This occurred as early as 8 days

after initial chytrid exposure (Table 1) but was only detected in 3 of the 11 (27%) chytrid-exposed frogs. Anorexia also was noted in the two surviving control frogs in the late stages of Experiment 1.

Lethargy, which was characterized as slow movements and/or reluctance to move when stimulated, occurred in 7 (64%) of the chytrid-exposed frogs and was first noted 1 to 4 days before death (Table 1). Two (67%) of the control animals in Experiment 1 were also lethargic; frog B1 was lethargic the day before it was found dead and frog B2 displayed lethargy for 1 wk before it was euthanized.

Large amounts of opaque, gray-white to tan, shed skin were found in the cages of all frogs exposed to chytrids, except for frog G2 in Experiment 3. This excessive shedding of skin was first noted 12 to 15 days after initial chytrid exposure (Table 1) and was a consistent finding until infected frogs died. Small tags of partially shed skin also were adhered to the feet, legs, and abdomen of six (55%) chytrid-exposed frogs. In contrast, only small pieces of semi-transparent shed skin were occasionally found in the cages of the control frogs and none of these frogs were noted to have tags of partially shed skin (Table 1).

Frog B4 in Experiment 1 was found moribund on Day 22 and was euthanized. All other chytrid-exposed frogs in the three experiments were found dead. The time interval between initial chytrid exposure and death ranged from 13 to 31 days ($\bar{x} = 22.4$ days; Table 1). One of the controls (frog B1) in Experiment 1 was found dead 10 days after this experiment began. The other two control frogs in this experiment were euthanized on day 36 (5 days after the last chytrid-exposed frog had died). All three of the control animals in Experiment 2 were alive and appeared to be healthy on Day 35 of this experiment (9 days after the last chytrid-exposed frog had died); these frogs were considered to be normal at that time and were subsequently used in Experiment 3.

During Experiment 1, both of the chy-

TABLE 1. Number of days after initial exposure to chytrids when clinical signs were first observed in dendrobatid frogs.

Frog ID	Exposure to chytrids	Anorexia	Lethargy	Shed skin in cage	Partially shed skin on body	Death
<i>Experiment 1</i>						
B1	no	— ^a	9	—	—	10
B2	no	29	29	—	—	36 ^b
B3	no	29	—	—	—	36 ^b
B4	yes	19	19	12	21	22 ^b
B5	yes	19	29	12	22	31
<i>Experiment 2</i>						
G1	no	—	—	—	—	—
G2	no	—	—	—	—	—
G3	no	—	—	—	—	—
G4	yes	—	—	15	—	26
G5	yes	—	23	15	21	24
G6	yes	—	—	15	—	16
G7	yes	—	—	15	21	22
G8	yes	—	25	15	—	26
G9	yes	—	18	15	—	21
<i>Experiment 3</i>						
G1	yes	—	17	15	18	21
G2	yes	8	—	—	—	13
G3	yes	—	21	15	21	24

^a Signs not observed noted with —.
^b Euthanized.

trid-exposed frogs and two of the three (67%) frogs in the control group had occasional tetanic-like seizures that were characterized by rigidity of the entire body with fasciculations of limb musculature. These seizures usually occurred when frogs were startled during cage cleaning and lasted for a few seconds up to 4 min, after which the affected animals appeared to be normal. The seizures were first noted in these frogs before the experiment began and also occurred in two of the three (67%) animals that died before initiation of the experiment. Similar seizures were not seen in any of the frogs in Experiment 2 but were noted in two of the frogs in Experiment 3; frog G2 seized once 4 days before it was found dead and frog G3 had a seizure 3 days before it died.

Cytology

Numerous chytrids were usually detected in the shed skin pieces recovered from the cages of the chytrid-exposed frogs. The organisms were located within the cyto-

plasm of epidermal keratinocytes and their morphology typically consisted of 10 to 15 μm diameter, round to oval, fungal cell bodies (thalli), many of which contained internal septa and/or zoospores (Fig. 1). Empty thalli also were common. No chytrids were found in shed skin fragments from control frogs.

Skin imprints from live frogs typically had small, scattered clusters of keratinized epidermal cells that, in chytrid-exposed frogs, usually contained low to moderate numbers of intracytoplasmic chytrid thalli (Fig. 2). Thalli were detected in all imprints made from chytrid-exposed frogs on Day 23 in Experiment 2. Chytrids also were present in imprints made on Day 15 in Experiment 3 but were not identified in the imprints made on Day 9. Skin imprints made from dead frogs usually had much larger keratinized skin fragments containing more numerous thalli. Chytrids were not present in imprints or skin scrapings made from the control frogs in Experiment 2.

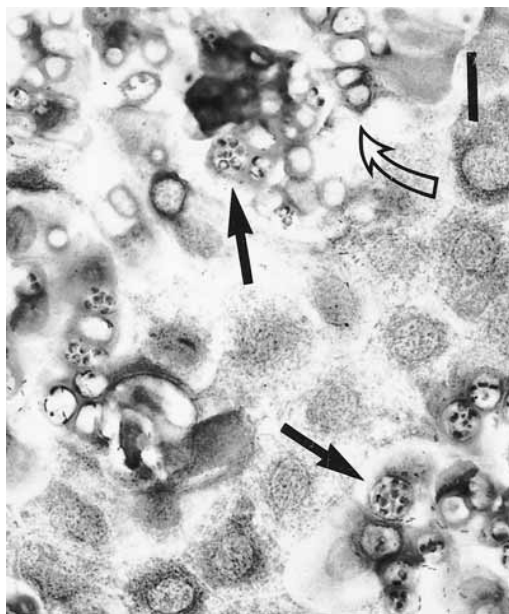


FIGURE 1. Photomicrograph of a cytologic preparation of shed skin from a green-and-black poison dart frog that was experimentally-infected with *Batrachochytrium dendrobatidis*. A sheet of keratinized epidermal cells has numerous intracytoplasmic chytrid organisms, including thalli containing numerous zoospores (arrows) and empty thalli (open arrow). DipQuick stain. Bar = 19 μ m.

Necropsy

Grossly, the consistent findings in all of the chytrid-exposed frogs were mild gray-white discoloration of skin over the hindlegs and ventrum, and the presence of numerous small pieces of partially shed skin that were located primarily on the feet and hindlegs. Occasionally, other areas of the body also had these changes. These lesions were best observed under low magnification (1.5 to 2 \times). Most (73%) of the chytrid-exposed frogs had reduced fat stores, however three (27%) of the frogs (G1, G4, and G9) had large amounts of fat at the time of death.

In Experiment 1, gross lesions also were observed at necropsy in the three control frogs. Frog B1, which died 10 days after the experiment began, had intestinal nematode parasites and only small amounts of body fat. Frogs B2 and B3 also were in poor nutritional condition with scant body

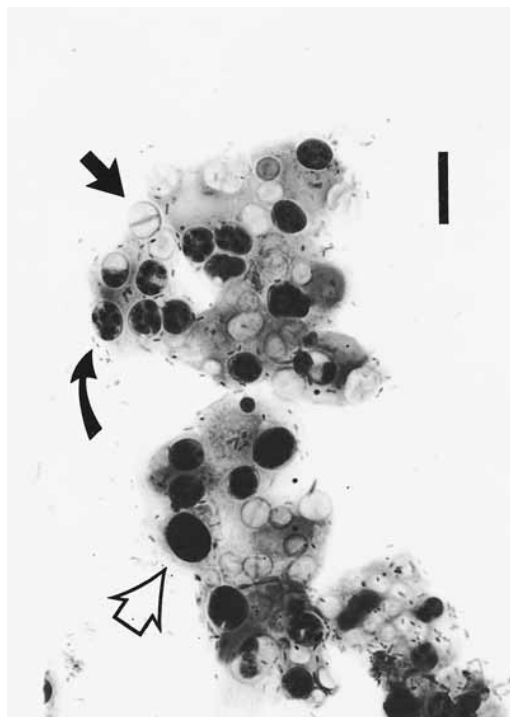


FIGURE 2. Photomicrograph of ante mortem skin imprints from a green-and-black poison dart frog made 23 days after first experimental exposure to *Batrachochytrium dendrobatidis*. Small clusters of keratinized epidermal cells contain moderate numbers of intracytoplasmic chytrids, including dark-staining uninucleated forms (open arrow), empty septate thalli (arrow), and thalli containing zoospores (curved arrow). Many large extracellular bacillary bacteria are also present. DipQuick stain. Bar = 14 μ m.

fat and generalized atrophy of the musculature. The entire skeleton of frog B2 was softer than normal and both hindlimbs projected in an abnormal cranio-lateral direction.

Histologically, a characteristic dermatosis was present in all chytrid-exposed frogs (Table 2). Skin lesions were most extensive and most severe over the feet, hindlegs, and ventral aspects of the torso; the head and dorsum were often relatively unaffected. Lesions consisted of mild to moderate epidermal hyperkeratosis with mild, multifocal hyperplasia and/or hypertrophy of nonkeratinized epidermal cells (Fig. 3). Low to moderate numbers of chytrid thalli were located in the keratinized layers of

TABLE 2. Microscopic lesions in dendrobatid frogs exposed to chytrids.

Frog ID	Chytrid exposure	Dermatosis	Osteodystrophy	Other lesions
<i>Experiment 1</i>				
B1	no	no	yes	Parastic enteritis
B2	no	no	yes	Bone fractures
B3	no	no	yes	None
B4	yes	yes	yes	Bone fracture
B5	yes	yes	yes	None
<i>Experiment 2</i>				
G1	no	no	NE ^a	NE
G2	no	no	NE	NE
G3	no	no	NE	NE
G4	yes	yes	yes	None
G5	yes	yes	no	None
G6	yes	yes	no	Aspiration pneumonia
G7	yes	yes	no	Aspiration pneumonia
G8	yes	yes	no	None
G9	yes	yes	no	None
<i>Experiment 3</i>				
G1	yes	yes	yes	None
G2	yes	yes	no	None
G3	yes	yes	yes	None

^a NE = not examined.

these lesions. Small, scattered foci of epidermal degeneration were also present in some frogs and were occasionally accompanied by infiltration of the underlying dermis by low numbers of neutrophils and macrophages. Neither skin lesions nor chytrids were detected in the control frogs or in the four frogs that died during the acclimation periods before Experiments 1 and 2 began.

Varying degrees of osteodystrophy affected the skeletons of all frogs in Experiment 1 (Table 2). This was characterized by the presence of wide seams of unmineralized osteoid along cortical surfaces of bones, with only thin, irregularly-shaped mineralized central layers. These lesions were most extensive in control frog B2, in which there also was fibro-cartilagenous tissue proliferation associated with spontaneous fractures of both femurs and the right humerus. A similar partially healed femoral fracture was found in frog B4. Three frogs (33%) in Experiments 2 and 3 also had osteodystrophy (Table 2), but the lesions in these frogs were relatively mild

(Fig. 4) and did not appear to be clinically significant.

Aspiration pneumonia was detected histologically in two of the six (33%) chytrid-exposed animals in Experiment 2 (Table 2). In frog G6, there was diffuse hypertrophy and hyperplasia of the epithelial cells lining the airways of both lungs, associated with the presence of amorphous blue-gray material surrounded by neutrophils, macrophages, and degenerate epithelial cells within the airway lumens. A similar but much smaller, focal lesion was located in one lung lobe of frog G7.

Culture results

Pure cultures of an organism identified as *Batrachochytrium dendrobatidis* (Longcore et al., 1999) were isolated from the skin of frog B4 in Experiment 1 and frogs G4 and G6 in Experiment 2. No attempts were made to culture chytrids from any of the other frogs.

Statistical analyses

In Experiment 1, both of the chytrid-exposed frogs had the skin disease de-

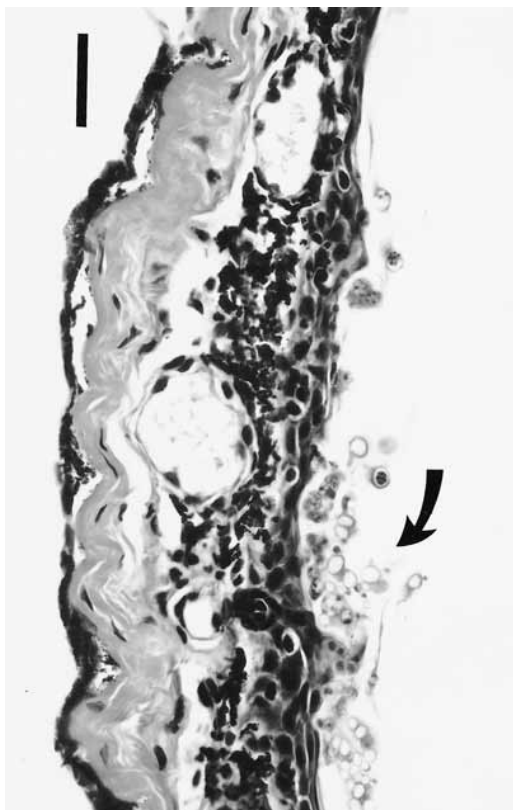


FIGURE 3. Skin from a juvenile green-and-black poison dart frog that died 26 days after first exposure to *Batrachochytrium dendrobatidis*. There is prominent epidermal hyperkeratosis with hyperplasia, hypertrophy, and loss of organized stratification of the non-keratinized epidermis. Moderate numbers of chytrids are located in the keratinized layers (arrow). H&E. Bar = 42 μ m.

scribed above whereas none of the three control frogs had skin lesions. Chi-square test results indicated that this difference was significant ($P = 0.025$). Both of the chytrid-exposed frogs and one of the control frogs in this experiment died by Day 31; the other two control frogs were euthanized on Day 36 for histologic examination of their skin. The difference in mortality between the two groups was not significant ($P = 0.14$).

In Experiment 2, all six frogs that were exposed to chytrids developed the skin disease described above and all six animals died by Day 26. In contrast, all three of the control frogs were still alive and free

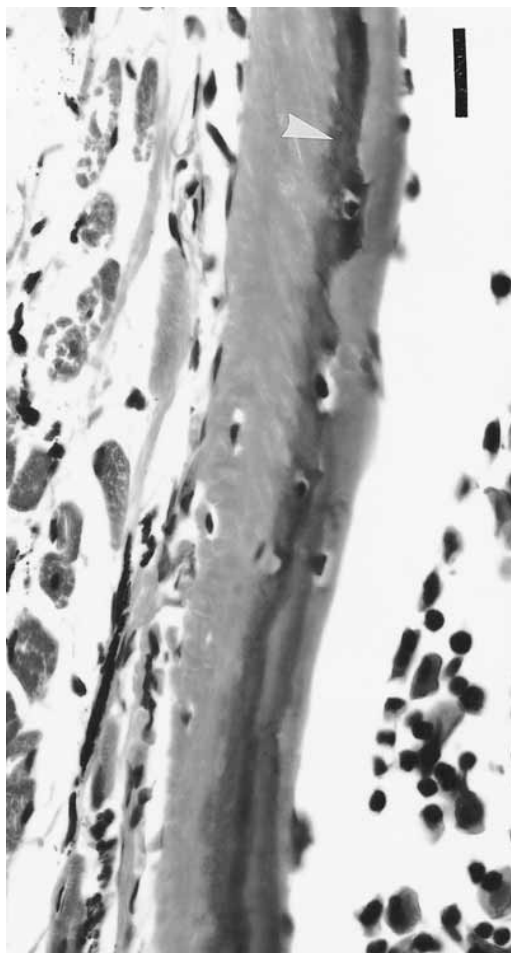


FIGURE 4. Photomicrograph of a long bone from a green-and-black poison dart frog with osteodystrophy. There is a darkly-stained, irregularly-shaped central mineralized layer (arrowhead) overlain by thick seams of poorly-mineralized osteoid. H&E, decalcification in 5% trichloroacetic acid. Bar = 19 μ m.

of grossly visible skin lesions on Day 35. Therefore, Chi-square tests were identical when comparing the prevalence of skin disease and the mortality prevalence between the two groups. Test results indicated that these differences were highly significant ($P < 0.003$).

In the combined experiments, a total of 11 frogs were exposed to chytrids; all developed skin disease and all died within 31 days of initial chytrid exposure. None of the six control frogs developed skin disease and only one died within the first 35 days

of the experiments. These differences are very highly significant ($P < 0.001$ for both prevalence of skin disease and mortality prevalence).

DISCUSSION

The chytrid isolate used in these studies was originally cultured from a captive blue poison dart frog that died with a skin disease in which numerous chytrid thalli were present (Pessier et al., 1999). This isolate was maintained in pure culture and then used to experimentally reproduce the skin disease in green-and-black poison dart frogs and blue-and-yellow poison dart frogs. The same chytrid organism was recovered in pure culture from all three affected frogs in which cultures were attempted. Therefore, these experiments fulfilled Koch's postulates (Samuelson and Von Lichtenberg, 1994) by conclusively demonstrating that *Batrachochytrium dendrobatidis* can cause skin disease in at least three species of dendrobatid frogs.

There was a highly statistically significant correlation between the presence of cutaneous chytridiomycosis and death. In four of the nine frogs (44%) that died during Experiments 2 and 3, the only lesion present was chytrid-induced skin disease. Although the other five chytrid-infected frogs (56%) in these two experiments had other lesions, none of these were attributable to chytrid infection nor were they severe enough to have caused death. Mild osteodystrophy was detected histologically in one frog in Experiment 2 and two frogs in Experiment 3; however, this condition appeared to be clinically insignificant. The pneumonia in two frogs in Experiment 2 most likely resulted from aspiration of ivermectin that was orally administered to these frogs 18 days prior to initiation of the experiment. The lesion in one frog was focal and mild, and was not considered to be contributory to the death of this animal. Although pneumonia in the other frog was more extensive, the primary cause of this frog's death appeared to be the chytrid infection since the frog was clinically normal

until it was exposed to chytrids. It is likely that the presence of pneumonia in this latter frog exacerbated the effects of chytridiomycosis; this frog was the first to die (Day 16) in Experiment 2.

All of the frogs from Experiment 1 (including the control frogs and the three frogs that died before the experiment started) had lesions of osteodystrophy, and all but one of these also had occasional tetanic-like seizures. These seizures resembled those caused by hypocalcemia in mammals (Jones et al., 1996), birds (Bennett, 1994), and reptiles (Boyer, 1996). The death of control frog B1 was attributed to a combination of intestinal nematode parasitism, poor nutritional condition, and probable hypocalcemia. The other two control frogs in Experiment 1 were euthanized on Day 36 and both had moderate to marked osteodystrophy, which was accompanied by multiple bone fractures in frog B2. Although derangement in calcium metabolism may have eventually led to the deaths of these two control frogs, they clearly outlived all of the chytrid-exposed animals in the three experiments, including the frogs that had no lesions other than cutaneous chytridiomycosis.

Tetanic seizures and poorly mineralized bones in amphibians can be caused by dietary imbalances of calcium, phosphorus, and/or vitamin D (Wright, 1996). A diet identical to that in these experiments has been used at NZP to successfully raise several species of poison dart frogs, including *D. tinctorius* (E. Smith, pers. comm.). However, the use of 100% RO water (which is almost completely devoid of calcium and other dissolved minerals) in Experiment 1 may have exacerbated a dietary calcium imbalance. Therefore, a mixture of 80% RO water and 20% charcoal-filtered water (which does have dissolved minerals) was used in the other experiments.

In Experiment 1, frogs were directly exposed to chytrids daily for up to 30 days. During Experiment 2, the daily exposures occurred only 4 or 5 days per wk for 4 wk.

In Experiment 3, the frogs were not directly exposed to chytrids but were exposed when they immersed themselves in the pools of water in their cages. By all of the methods of exposure, and apparently independent of the number of times frogs were exposed, frogs began shedding excessive amounts of skin 12 to 15 days after initial chytrid exposure. Excessive skin shedding was a consistent clinical sign in all chytrid-infected frogs, except for frog G2 which was found dead on Day 13 of Experiment 3. At necropsy, frog G2 had thickened, discolored skin over its legs and ventrum and this would likely have been shed if the animal had lived longer. The cage of frog G2 was contaminated with a relatively large amount of the chytrid culture mixture on five consecutive days and this frog died sooner than the other chytrid-exposed frogs in all three experiments. Frog G6 in Experiment 2 had extensive aspiration pneumonia and was found dead on Day 16 after initial chytrid exposure. Of the other nine frogs exposed to chytrids, eight were found dead 21 to 26 days after first exposure to the fungus and one was found dead on Day 31.

The mechanism by which cutaneous chytrid infections caused the deaths of the infected frogs is not known. Other organs did not consistently contain lesions, which indicates that the skin disease was directly responsible for the deaths. Normal amphibian skin functions include maintenance of hydration, osmoregulation, thermoregulation, and, to varying degrees between different species, respiration (Duellman and Trueb, 1986). The chytrid-induced cutaneous changes may have interfered with one or more of these skin functions, resulting in fatal metabolic abnormalities.

Cytologic examination of shed skin and skin imprints was useful in the ante mortem diagnosis of chytridiomycosis. Once excessive skin shedding began, chytrid thalli were easily detected in the pieces of shed skin. The organisms also were present in all skin imprints made from live

frogs 15 days or longer after initial exposure to *B. dendrobatidis*. Examination of skin imprints made at the time of necropsy also provided a method for rapidly proving that the frogs were infected.

The materials used in these studies to expose frogs to *B. dendrobatidis* were mixtures of broth cultures and rinses of agar cultures. These contained zoospores and thalli in various stages of development. Although no attempts were made to quantify the numbers of organisms, the mixtures were prepared in a similar manner for all three experiments. In Experiment 3, however, the volume of the mixture added to each cage was five times that used to directly expose frogs in Experiments 1 and 2. Therefore, it is likely that the cages were contaminated with much higher numbers of chytrid organisms. In subsequent studies, a method has been developed to collect, isolate, and quantitate zoospores of *B. dendrobatidis* (E. Lamirande, unpubl. data). Chytridiomycosis has been induced in healthy juvenile *D. tinctorius* by exposing the frogs to zoospores only and the experimental results were very similar to those reported in this paper (D. Nichols and E. Lamirande, unpubl. data).

The experimentally-induced disease described in this paper was similar to that previously reported to be associated with fatalities in many different species of captive and wild anuran amphibians (Berger et al., 1998; Pessier et al., 1999). Cutaneous chytridiomycosis has apparently emerged recently to become a significant disease problem in amphibians over a wide geographical area, including Australia, Costa Rica, Panama, and the USA (Daszak et al., 1999). The role that this disease may be playing in the global declines of wild amphibian populations is currently under investigation. Some data indicate that chytrids may be pathogens recently introduced to naive amphibian populations (Berger et al., 1998). It is also possible that, in some areas, chytrids and amphibians have co-existed for many years but recent changes have altered the pathogenic-

ity of the chytrids and/or amphibians' susceptibility to infection. The effects that potential cofactors, such as temperature, amphibian age, and environmental alterations, have on the pathogenesis of this disease should be studied. The experimental methodology described in this paper can serve as a model for further laboratory studies of amphibian chytridiomycosis.

ACKNOWLEDGMENTS

We thank P. Miles for generously donating some of the frogs used in these experiments. V. Rico, E. Smith, and the rest of the staff at the National Zoo's Department of Amazonia provided frog husbandry advice, fruitflies, and filtered water. V. Bonshock carefully prepared the histologic slides for this study. R.-A. Ferris provided photomicrography support. A Senior Post-doctoral Fellowship (98-3545-A) from the Friends of the National Zoo (FONZ) supported A. P. Pessier.

LITERATURE CITED

- BARR, D. J. S. 1990. Phylum Chytridiomycota. In *Handbook of Protozoa*. L. Margulis, J. O. Corliss, M. Melkonian, and D. J. Chapman (eds.). Jones and Bartlett, Boston, Massachusetts, pp. 454–466.
- BENNET, R. A. 1994. Neurology. In *Avian medicine: Principles and applications*. B. Richie, G. J. Harrison, and L. R. Harrison (eds.). Wingers Publishing, Inc., Lake Worth, Florida, pp. 723–747.
- BERGER, L., R. SPEARE, P. DASZAK, D. E. GREEN, A. A. CUNNINGHAM, C. L. GOGGIN, R. SLOCOMBE, M. A. RAGAN, A. D. HYATT, K. R. McDONALD, H. B. HINES, K. R. LIPS, G. MARANTELLI, AND H. PARKES. 1998. Chytridiomycosis causes amphibian mortality associated with population declines in the rain forests of Australia and Central America. *Proceedings of the National Academy of Sciences, USA*, 95: 9031–9036.
- BOYER, T. H. 1996. Metabolic bone disease. In *Reptile medicine and surgery*. D. R. Mader (ed.). WB Saunders Co., Philadelphia, Pennsylvania, pp. 385–392.
- DASZAK, P., L. BERGER, A. A. CUNNINGHAM, A. D. HYATT, D. E. GREEN, AND R. SPEARE. 1999. Emerging infectious diseases and amphibian population declines. *Emerging Infectious Diseases* 5: 735–748.
- DEGROOT, M. E. 1975. *Probability and statistics*. Addison-Wesley Publishing Co., Reading, Massachusetts, 607 pp.
- DUELLMAN, W. E., AND L. TRUEB. 1986. *Biology of amphibians*. McGraw-Hill Book Company, New York, New York, 670 pp.
- JONES, T. C., R. D. HUNT, AND N. W. KING. 1997. *Veterinary Pathology*. 6th Edition. Williams & Wilkins, Baltimore, Maryland, 1392 pp.
- LONGCORE, J. E., A. P. PESSIER, AND D. K. NICHOLS. 1999. *Batrachochytrium dendrobatidis* gen. et sp. nov., a chytrid pathogenic to amphibians. *Mycologia* 91: 219–227.
- PESSIER, A. P., D. K. NICHOLS, J. E. LONGCORE, AND M. S. FULLER. 1999. Cutaneous chytridiomycosis in poison dart frogs (*Dendrobates* spp.) and White's tree frogs (*Litoria caerulea*). *Journal of Veterinary Diagnostic Investigation* 11: 194–199.
- SAMUELSON, J., AND F. VON LICHTENBERG. 1994. Infectious diseases. In *Pathologic basis of disease*. 5th Edition. R. S. Cotran, V. Kumar, and S. L. Robbins (eds.). WB Saunders Co., Philadelphia, Pennsylvania, pp. 305–306.
- WRIGHT, K. M. 1996. Amphibian husbandry and medicine. In *Reptile medicine and surgery*. D. R. Mader (ed.). W. B. Saunders Co., Philadelphia, Pennsylvania, pp. 436–459.

Received for publication 25 January 2000.